An Update on Facial Transplantation Cases Performed between 2005 and 2010

Maria Siemionow, M.D., Ph.D., D.Sc.
Can Ozturk, M.D.
Cleveland, Ohio

Background: Since 2005, 13 facial allotransplantation cases have been performed worldwide. The major indications for these facial allotransplantations were neurofibromatosis and trauma injuries, including animal bites, burns, falls, and shotgun blasts.
Methods: An analysis of 13 facial transplantation cases was performed by reviewing the anatomical details, microsurgical techniques, and functional outcomes according to the follow-up information based on the literature, meeting presentations, and media reports.
Results: The male-to-female ratio was 11:2. Two male patients died at 2 months and 2 years, respectively, after transplantation because of transplant- and infection-related problems. Eleven face transplant recipients are alive. The composite tissue allotransplants included cutaneous, myocutaneous, and osteomyocutaneous components. Most of these facial allotransplants were partial, one was nearly total, and two were announced as total face transplantations.
Conclusions: This report provides a useful overview of the technical aspects of face transplantation; however, the reports on long-term functional and aesthetic outcomes will help to define the future of face transplantation. (*Plast. Reconstr. Surg.* 128: 707e, 2011.)

Until 1962, replantation of amputated limbs, body parts, and tissues was not feasible.[1] Advances in microsurgical techniques and instrumentation opened the field of replantation surgery and reconstructive surgery, making it applicable to free autologous tissue transfers. Because of the investigation of a new generation of immunosuppressive agents, composite tissue allotransplantation became feasible. The world's first institutional review board approval for face transplantation in humans was granted to Siemionow in 2004. In 2005, partial face allotransplantation was performed in Amiens, France, by Devauchelle and Dubernard.[2]

Once considered utopic, facial allotransplantation has become a clinical reality, and technical aspects have been managed successfully. However, the question is, how can we guarantee the best functional and aesthetic outcomes for this unique group of patients? In this article, we have summarized available outcome data on the world's experience with face transplantation, analyzing differences in the technical approaches used for these cases and differences in the functional outcomes based on the literature, meeting presentations, and media reports.

From the Dermatology and Plastic Surgery Institute, Cleveland Clinic.
Received for publication December 7, 2010; accepted April 12, 2011.

DOI: 10.1097/PRS.0b013e318230c77b

BACKGROUND DATA

The first face transplant was a partial transplant, and the last two cases performed in Spain and France, in 2010, were reported as full face transplants. In total, 13 face transplantations were performed between November of 2005 and December of 2010. The indications for transplantation were traumatic facial injury, neurofibromatosis, and facial deformity after tumor resection. Traumatic injuries included animal bites, shotgun blast injury, burns, and falls. The male-to-female ratio was 11:2. Two male recipients died because of transplant-related problems. The details regarding patient population, type and extent of trauma, facial composite tissue allotransplantation components, and microsurgical repairs are summarized in Tables 1 and 2.[3] The immunosuppression protocols of the first four facial transplant

Disclosure: *The authors have no financial interest to declare in relation to the content of this article.*

Table 1. Summary of Patients and Microsurgical Repair of Arteries, Veins, and Nerves for 13 Face Transplant Recipients

Patient	Age (yr)	Sex	Country	Outcome	Team Leaders, Year	Type of Transplant	Artery Repair	Venous Repair	Sensory Nerve Repair	Motor Repair
1	38	F	France	Alive	Dubernard and Devauchelle, 2005	Partial myocutaneous	Bilateral facial artery (end-to-end)	Bilateral facial vein (end-to-end)	Bilateral infraorbital and mental nerve	Left mandibular branch
2	30	M	China	Died	Guo, 2006	Partial osteomyocutaneous	Right external maxillary artery (end-to-end)	Right anterior facial vein (end-to-end)	No repair discussed	Right facial nerve not well coapted
3	29	M	France	Alive	Lantieri, 2007	Partial myocutaneous	Bilateral external carotid artery (end-to-end)	Bilateral thyrolinguofacial trunks (end-to-end)	Bilateral infraorbital nerve (mental nerve placed near foramen)	Bilateral facial nerve
4	45	F	United States	Alive	Siemionow, 2008	Nearly total osteomyocutaneous	Bilateral facial common artery (end-to-end	Left external jugular, posterior facial and right facial vein (end-to-end)	Not repaired because of original trauma	Bilateral facial nerve
5	28	M	France	Alive	Lantieri, 2009	Partial osteomyocutaneous	Bilateral external carotid artery	External jugular vein and thyrolinguofacial trunk	Not repaired because of original trauma	Bilateral facial nerve
6	37	M	France	Died	Lantieri, 2009	Partial myocutaneous	Bilateral external carotid artery	Bilateral thyrolinguofacial trunk	Bilateral supraorbital and infraorbital nerve	Bilateral facial nerve
7	59	M	United States	Alive	Pomohac, 2009	Partial osteomyocutaneous	Left external carotid, right facial artery (end-to-end)	Bilateral facial vein	Bilateral infraorbital and buccal sensory nerve	Bilateral facial nerve branches
8	33	M	France	Alive	Lantieri, 2009	Partial osteomyocutaneous	Bilateral external carotid artery	External jugular vein and thyrolinguofacial trunk	Not repaired because of original trauma	Bilateral facial nerve
9	42	M	Spain	Alive	Cavadas, 2009	Partial osteomyocutaneous	Right CCA to right SCA (end-to-side)	Bilateral external jugular vein and right internal jugular vein	Bilateral lingual, inferior alveolar, and unilateral cervicofacial nerve	Bilateral hypoglossal nerve
10	27	M	France	Alive	Devauchelle and Dubernard, 2009	Partial osteomyocutaneous	Bilateral facial artery	Bilateral facial vein	Bilateral infraorbital and mental nerve	Bilateral facial nerve (6 mo after transplantation)
11	34	M	Spain	Alive	Gomez-Cia, 2010	Partial myocutaneous	Bilateral external carotid artery	Bilateral internal jugular vein	Bilateral infraorbital and mental nerve	Bilateral facial nerve
12	30	M	Spain	Alive	Barret, 2010	Total osteomyocutaneous	Bilateral external carotid artery	Bilateral external jugular, unilateral retromandibular, and anterior jugular vein	Bilateral supraorbital, infraorbital and mental nerve	Bilateral facial nerve
13	35	M	France	Alive	Lantieri, 2010	Total myocutaneous	Bilateral external carotid artery	Bilateral external jugular vein and thyrolinguofacial trunk	Bilateral supraorbital, infraorbital, and mental nerve	Bilateral facial nerve

M, male; F, female; CCA, common carotid artery; SCA, subclavian artery.

Table 2. Summary of Anatomical Components of Face Allografts in 13 Face Transplant Recipients

							Skin and Oral					
Patient	Age (yr)	Sex	Country	Year	Bone	Soft Tissue	Scalp, Forehead, and Ear	Eyelid and Cheek	Nose	Lip and Chin	Tongue, Palate, and Mucosa	Total Amount of CTA (%)
1	38	F	France	2005	None	None	None	Partial cheek	Partial nose	Upper and lower lip and chin	Partial mucosa	25–30
2	30	M	China	2006	Unilateral infraorbital, maxilla, nasal, and zygoma	Parotid gland, septal cartilage	None	Partial cheek	Total nose	Upper lip	Partial mucosa	30–35
3	29	M	France	2007	None	Bilateral parotid glands and ducts, septal cartilage	None	Bilateral cheeks	Total nose	Upper and lower lip and chin	Partial mucosa	70–75
4	45	F	United States	2008	Bilateral orbital floor, zygoma, nasal, maxilla with teeth and hard palate	Bilateral parotid gland and ducts, septal cartilage	None	Bilateral cheeks and lower eyelids	Total nose	Upper lip	Partial mucosa	75–80, 535 cm^2
5	28	M	France	2009	Maxilla	Bilateral parotid glands and ducts, septal cartilage	None	Bilateral cheeks	Total nose	Upper and lower lip and chin	Partial mucosa	60–65
6	37	M	France	2009	None	Bilateral parotid glands and ducts, septal and ear cartilage	Forehead, scalp, and ear	Bilateral cheek, lower and upper eyelids	Total nose	None	Partial mucosa	70–75, plus scalp
7	59	M	United States	2009	Bilateral maxilla with teeth and palate	Bilateral parotid ducts, septal cartilage	None	Bilateral cheek	Total nose	Upper lip	Partial mucosa	45–50
8	33	M	France	2009	Maxilla and mandible	None	None	Bilateral cheek	Nose	Upper and lower lip and chin	Partial mucosa	60–65
9	42	M	Spain	2009	Mandible	None	Neck	Partial bilateral cheek	None	Lower lip and chin	Tongue and partial mucosa	30–35
10	27	M	France	2009	Mandible	None	None	None	Nose	Upper and lower lip and chin	Partial mucosa	25–30
11	34	M	Spain	2010	None	Bilateral parotid glands	None	Bilateral cheek	Partial nose	Upper and lower lip and chin	Partial mucosa	60–65
12	30	M	Spain	2010	Bilateral orbital floor, zygoma, nasal, maxilla with teeth, palate and mandible	Bilateral parotid glands and ducts, septal cartilage	Forehead	Bilateral cheek, lower and upper eyelids	Total nose	Upper and lower lip and chin	Partial mucosa	95–100
13	35	M	France	2010	None	Bilateral parotid glands and ducts, septal cartilage, tear glands and lacrimal canal	Forehead, bilateral ears	Bilateral cheek, lower and upper eyelids with glands	Total nose	Upper and lower lip and chin	Partial mucosa	95–100

CTA, composite tissue allotransplantation; M, male; F, female.

patients are summarized in Table 3. Sensory and motor recovery results of reported cases are presented in Table 4. The uniqueness of this article is that it summarizes all current cases of facial transplantation performed worldwide. The limitations, however, include lack of specific details, and conflicting reports on some of the yet unpublished cases. However, considering the significant worldwide interest in establishing centers for facial transplantation, we are bringing readers up to date on the current status of face transplantation.

REVIEW OF CURRENT CASES OF FACIAL COMPOSITE TISSUE ALLOTRANSPLANTATION RECIPIENTS

The cases of face transplantation performed between 2005 and 2010 are summarized in Figures 1 through 13, which present diagrams of the 13 face transplant recipients, outlining the composite tissue allotransplantation components (i.e., skin, soft tissues, muscles, bones, arteries, veins, nerves, and glands) and functional units included in face allotransplantation. Details on composite tissue allotransplantation design and repair of arteries, veins, and nerves are presented in Tables 1 and 2.[3]

Case 1 (Fig. 1)

Date: November of 2005
Location: Amiens, France
Team leaders: Jean-Michelle Dubernard and Bernard Devauchelle
Recipient: 38-year-old woman
Donor: Brain-dead 46-year-old woman
Indication: Midface trauma after dog bite
Previous reconstruction: None
Time interval to transplantation: 6 months

Case 2 (Fig. 2)

Date: April of 2006
Location: Xian, China
Team leader: Shuzhong Guo
Recipient: 30-year-old man
Donor: Brain-dead 25-year-old man
Indication: Midface trauma after bear bite
Previous reconstruction: Left radial forearm flap
Time interval to transplantation: 18 months

Case 3 (Fig. 3)

Date: January of 2007
Location: Paris, France
Team leader: Laurent Lantieri
Recipient: 29-year-old man
Donor: Brain-dead 65-year-old man
Indication: Plexiform neurofibroma
Previous reconstruction: Multiple resections

Table 3. Summary of Immunosuppression Protocols of the First Four Facial Transplant Patients

Patient	Age (yr)	Sex	Location	Year	Induction Immunosuppressive Protocol	Maintenance Protocol
1	38	F	Amiens, France	2005	Antithymocyte globulin (1.25 mg/kg/day for 10 days); tacrolimus (10–15 ng/ml); MMF (2 g); prednisolone (250 mg on day 1, 100 mg on day 2, 60 mg for 10 days)	Tacrolimus (10–15 ng/ml); sirolimus (8–12 ng/ml started 11 mo after surgery); MMF (2 g/day); prednisolone (25 mg/day); bone marrow infusion on PODs 4 and 11
2	30	M	Xian, China	2006	Tacrolimus (25 ng/ml); MMF (500 mg); methylprednisolone (1 g); humanized IL-2 receptor monoclonal antibody (50 mg)	Tacrolimus (10–25 ng/ml); MMF (taper dose); prednisone (taper dose, stopped after 22 mo); humanized IL-2 receptor monoclonal antibody (50 mg on PODs 15 and 30)
3	29	M	Paris, France	2007	Antilymphocyte serum (1.25 mg/kg/day for 10 days); tacrolimus (10–13 ng/ml); MMF (2 g); prednisone (500 mg on day 1, 250 mg on day 2, 120 mg on day 3, 60 mg for 7 days)	Tacrolimus (8–10 ng/ml); MMF (2 g/day); prednisone (10 mg/day)
4	45	F	Cleveland, Ohio	2008	Rabbit antithymocyte globulin (1.2 mg/kg/day for 9 days); methylprednisolone (1 g on day 1); tacrolimus (12–15 ng/ml for 3 mo); MMF (2 g)	Tacrolimus (10–12 ng/ml); MMF (stopped at 6 mo after surgery); prednisone (10 mg/day)

F, female; M, male; MMF, mycophenolate mofetil; PODs, postoperative days; IL, interleukin.

Table 4. Details of Motor Recovery of the First Four Face Transplantation Cases

	Team Leaders			
Motor Recovery	**Dubernard**	**Guo**	**Lantieri**	**Siemionow**
Lip motion	Upper lip (12 wk); lower lip (4 mo); labial closure (6 mo)	NA	Orbicularis oris contraction (6 mo)	Upper lip occlusion
Facial mimicry	Smile (14–18 mo)	Facial nerve not fully functional; unable to smile completely and symmetrically	Spontaneous mimicry (9 mo)	Facial mimicry
Other	Eat and drink (1 wk); chin and nose pyramidal muscle motion (12 mo)	Eat, drink, and speak normally	Eat and speak (10 day); trigeminal and facial motor function (12 mo)	Eat and drink from a cup; speak more clearly

NA, not applicable.

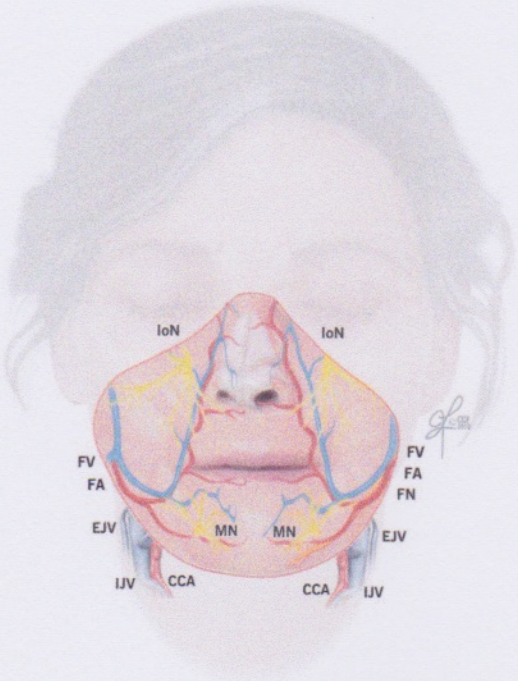

Fig. 1. Case 1. The recipient was a 38-year-old woman with midface trauma after dog bite. The patient underwent partial face transplantation, including nose, lips, chin, partial cheeks, and intraoral mucosa. The procedure took place in November of 2005, in Amiens, France. *CCA*, common carotid artery; *EJV*, external jugular vein; *EMA*, external maxillary artery; *FA*, facial artery; *FV*, facial vein; *FN*, facial nerve; *IJV*, internal jugular vein; *IaN*, inferior alveolar nerve; *IoN*, infraorbital nerve; *Ld*, lacrimal duct; *LG*, lacrimal gland; *LN*, lingual nerve; *MN*, mental nerve; *SoN*, supraorbital nerve.

Case 4 (Fig. 4)

Date: December of 2008
Location: Cleveland, Ohio
Team leader: Maria Siemionow
Recipient: 45-year-old woman
Donor: Brain-dead 44-year-old woman
Indication: Shotgun injury
Previous reconstruction: 23 reconstructive operations
Time interval to transplantation: 4 years

Case 5 (Fig. 5)

Date: March of 2009
Location: Paris, France
Team leader: Laurent Lantieri
Recipient: 28-year-old man
Donor: Brain-dead 43-year-old man
Indication: Ballistic trauma

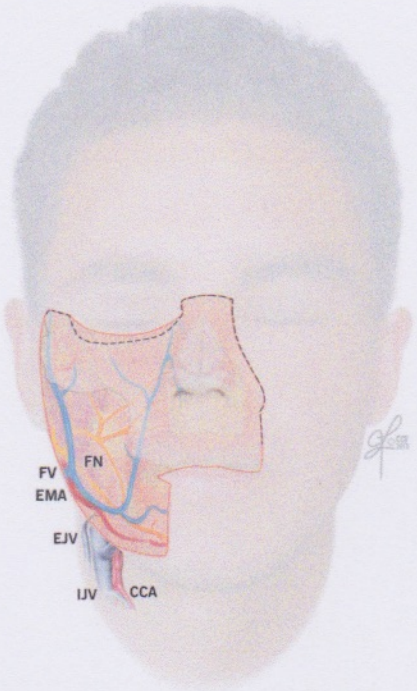

Fig. 2. Case 2. The recipient was a 30-year-old man with midface trauma after bear bite. The patient underwent partial face transplantation, including overlying skin, soft tissue, upper lip, nose, right anterior maxilla, sinus, right zygoma with lateral orbital wall, right parotid gland, and partial masseter with intraoral mucosa. The procedure took place in April of 2006 in Xian, China.

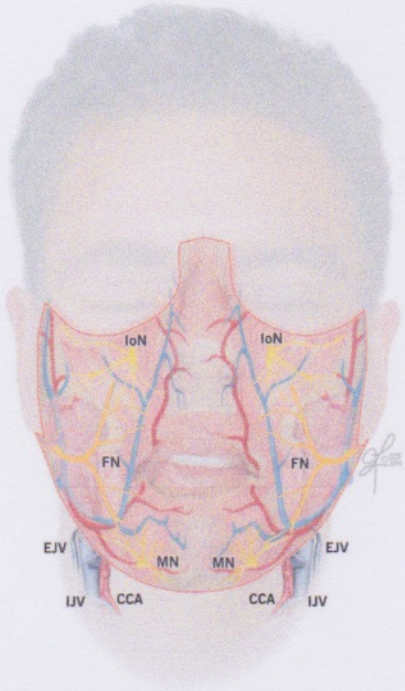

Fig. 3. Case 3. The recipient was a 29-year-old man with neurofibromatosis. The patient underwent partial middle/lower face transplantation, including the lower two-thirds of face skin, soft tissue, lips, chin, cheeks, nose, bilateral parotid glands, parotid ducts, and intraoral mucosa. The procedure took place in January of 2007 in Paris, France.

Case 6 (Fig. 6)

Date: April of 2009
Location: Paris, France
Team leader: Laurent Lantieri
Recipient: 37-year-old man
Donor: Brain-dead 59-year-old man
Indication: Third-degree burn

Case 7 (Fig. 7)

Date: April of 2009
Location: Boston, Mass.
Team leader: Bohdan Pomahac
Recipient: 59-year-old man
Donor: Brain-dead 60 year-old man
Indication: Fall/electrical injury

Case 8 (Fig. 8)

Date: August of 2009
Location: Paris, France
Team leader: Laurent Lantieri
Recipient: 33-year-old man
Donor: Brain-dead 55-year-old man
Indication: Ballistic trauma

Case 9 (Fig. 9)

Date: August of 2009
Location: Valencia, Spain
Team leader: J. Pedro Cavadas
Recipient: 42-year-old man
Donor: Non–heart-beating, brain-dead, 35-year-old man
Indication: Cancer treatment sequela

Case 10 (Fig. 10)

Date: November 2009
Location: Amiens, France
Team leader: Bernard Devauchelle and Jean-Michelle Dubernard
Recipient: 28-year-old man
Donor: Brain-dead man
Indication: Explosion trauma

Case 11 (Fig. 11)

Date: January of 2010

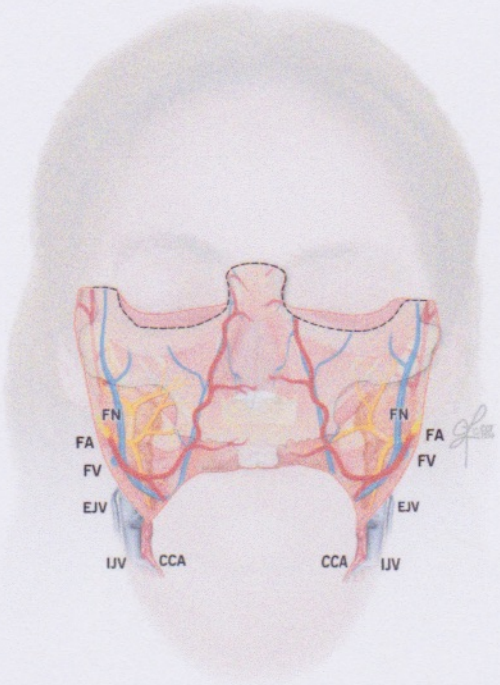

Fig. 4. Case 4. The recipient was a 45-year-old woman who sustained a shotgun injury to the face. The patient underwent a nearly total face transplantation, including composite Le Fort III midfacial skeleton, overlying skin, soft tissue, nose, lower eyelids, upper lip, total infraorbital floor, bilateral zygomas, bilateral parotid glands, anterior maxilla with central maxillary incisors, total alveolus, anterior hard palate, and intraoral mucosa. The procedure took place in December of 2008 in Cleveland, Ohio.

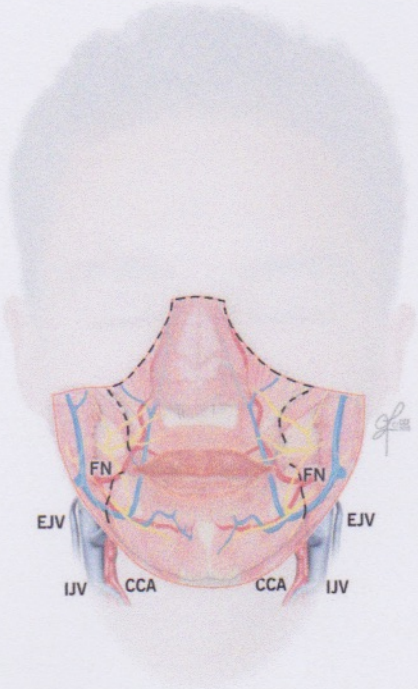

Fig. 5. Case 5. The recipient was a 28-year-old man who presented after ballistic injury to the face. The patient underwent partial face transplantation, including maxilla, chin, nose and overlying lower third of face skin, soft tissue, lips, cheeks, bilateral parotid glands, parotid ducts, and intraoral mucosa. The procedure took place in March of 2009 in Paris, France.

Location: Sevilla, Spain
Team leader: T. Gomez-Cia
Recipient: 34-year-old man
Donor: Brain-dead 30-year-old man
Indication: Neurofibromatosis

Case 12 (Fig. 12)

Date: March of 2010
Location: Barcelona, Spain
Team leader: J. Pare Barret
Recipient: 30-year old man
Donor: 41-year-old man
Indication: Shotgun injury

Case 13 (Fig. 13)

Date: June of 2010
Location: Paris, France
Team leader: Laurent Lantieri
Recipient: 35-year-old man
Donor: No data available
Indication: Neurofibromatosis

DISCUSSION

Currently, 13 face transplant cases have been performed worldwide, including seven in France, one in China, two in the United States, and three in Spain. Technical details for only eight of those patients have been reported in the literature, whereas data for the other five are based on media reports and meeting presentations.[2–24]

The sine qua non priority for successful facial transplantation is revascularization of the facial allograft following anastomosis between the donor and recipient vessels. According to facial transplantation reports, the preferred vessels for arterial anastomoses were the external carotid arteries and their branches, such as external maxillary and facial arteries. The preferred vessels for venous anastomoses were the facial and external jugular veins and the thyrolinguofacial trunks.[2–9] Both arterial and venous anastomoses were performed

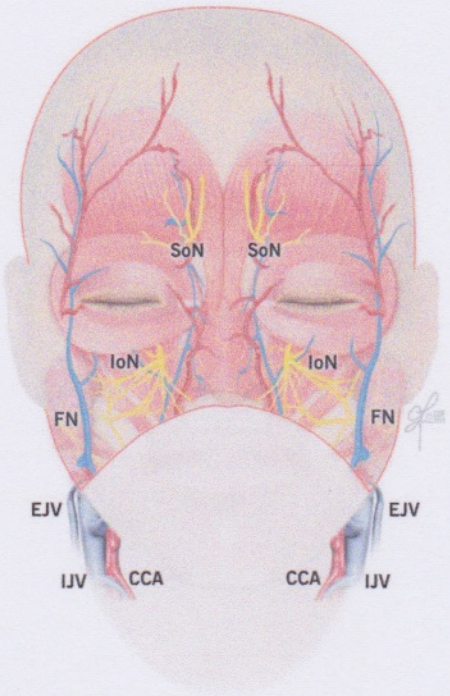

Fig. 6. Case 6. The recipient was a 37-year-old man with third-degree burn. The patient underwent partial face transplantation, including the upper two-thirds of the face with overlying skin, soft tissue, entire scalp with bilateral ears, forehead, lower eyelids, nose, bilateral cheeks, bilateral parotid glands and parotid ducts, and intraoral mucosa. The procedure took place in April of 2009 in Paris, France.

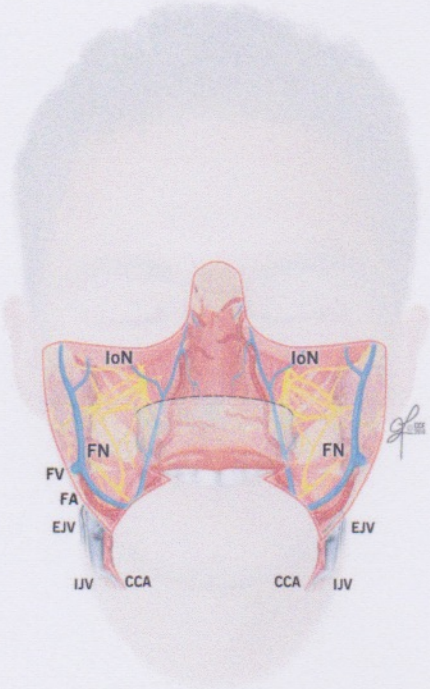

Fig. 7. Case 7. The recipient was a 59-year-old man who presented after a fall/electrical injury. The patient underwent partial face transplantation, including midface tissue with overlying skin, soft tissue, nose, upper lip, bilateral cheek, bilateral parotid ducts, maxilla with teeth, and palate. The procedure took place in April of 2009 in Boston, Massachusetts.

using conventional end-to-end microsurgical techniques. This may be because the vessel calibers were of nearly equal size, and adequate vessel length was available from the donor graft. Standard end-to-end anastomosis was the preferred technique used for vessel repair. This differs from the experience reported during free flap reconstruction within the head and neck region, where vessel caliber discrepancy often occurs between the size of recipient and donor vessels and thus end-to-side anastomosis is often preferred. There was only one report of end-to-side vessel anastomosis (Table 1, patient 9).

Takamatsu et al. described selection of the recipient vessels within the head and neck region, and suggested the superficial temporal and facial vessels as the vessels of first choice for the midface and upper face reconstruction.[25] For mandibular or lower face reconstruction, the external carotid artery and its branches should be considered.[25] Eight of the 13 face transplantation cases included osteomyocutaneous components, and cases included the midface, which is the most important and technically challenging component of facial reconstruction. In cases where osteomyocutaneous face transplants were performed, the surgeons preferred to connect vessels at the proximal levels (e.g., common facial artery and external carotid artery). This approach may be important for maintaining the viability of composite allografts, including bone components. However, Pomahac et al. reported that the facial artery alone can perfuse both the soft tissues and bony elements of midfacial allografts, including maxilla and zygoma components.[8] These findings, based on cadaver studies, elucidated that perfusion of bony components is supplied by vascular communications between facial and maxillary artery systems. The facial artery nourishes the midface anatomical structures; however, there are no clinical data confirming that a single facial artery can perfuse a total osteomyocutaneous face transplant. Meningaud et al. reported that, in a preclinical cadaver

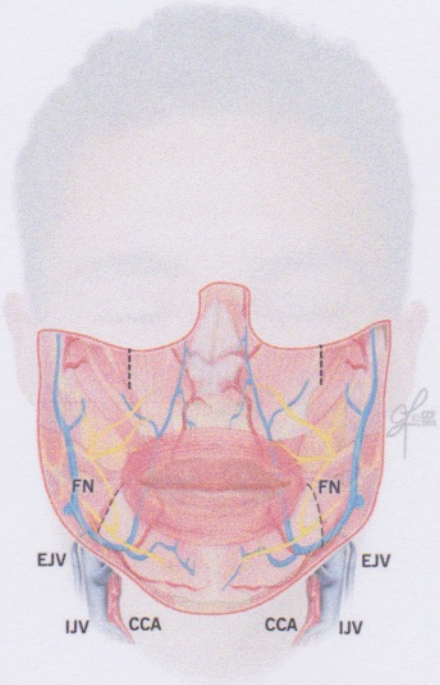

Fig. 8. Case 8. The recipient was a 33-year-old man who sustained a ballistic injury to the face. The patient underwent partial face transplantation, including the lower two-thirds of facial tissue with overlying skin, soft tissue, nose, cheek, mouth, maxilla, and mandible. The procedure took place in August of 2009 in Paris, France.

Fig. 9. Case 9. The recipient was a 42-year-old man with face deformity resulting from cancer treatment sequela. The patient underwent partial face transplantation, including the lower third of facial tissue with overlying skin, soft tissue, lower lip, partial cheek, chin, neck, mandible, tongue, and intraoral mucosa. The procedure took place in August of 2009 in Valencia, Spain.

study, complete revascularization of a full facial and scalp flap was feasible when based on a single external carotid artery.[9] Furthermore, they observed full revascularization of the composite tissue allotransplant after end-to-end anastomosis of the external carotid artery in their clinical case. However, they carried out the contralateral external carotid artery repair to secure vascularity of the facial graft in case of one-sided vessel thrombosis. To make recommendations for the best design of vascular anastomosis, in face transplant cases, more experimental and clinical data are required, specifically, when choosing the arterial and venous supply for cases of nearly total and total osteomyocutaneous face transplantation.

According to the facial transplantation literature and meeting reports, two arterial and two or more venous anastomoses were performed in all except two cases—in one case,[4] only a single artery and single vein were repaired; in the second case, single artery and three veins were anastomosed.[23] Because of the rich interconnecting vascular network within the face, a single artery and single venous repair are usually sufficient for adequate graft vascularization in most of the partial face transplant cases. There are also reports describing successful facial replantation based on a single-vessel anastomosis supporting survival of large segments of the face, scalp, and soft tissues.[26,27] However, at this point, we cannot experiment with or afford the failure of facial transplantation solely because of potential technical problems that may be related to arterial or venous repair. Thus, to minimize the risk of transplant failure, at least two arterial and two venous anastomoses should be performed. None of the cases discussed in this article reported early vascular complications such as graft failure caused by vascular thrombosis or vascular spasm.

Another technically important issue regarding vessel choice is the status of the recipient vessels. Most transplant candidates present with scarring, anatomical variations, and compromised vascular territories because of the extent of trauma, tumor resection, or previous reconstructive procedures.

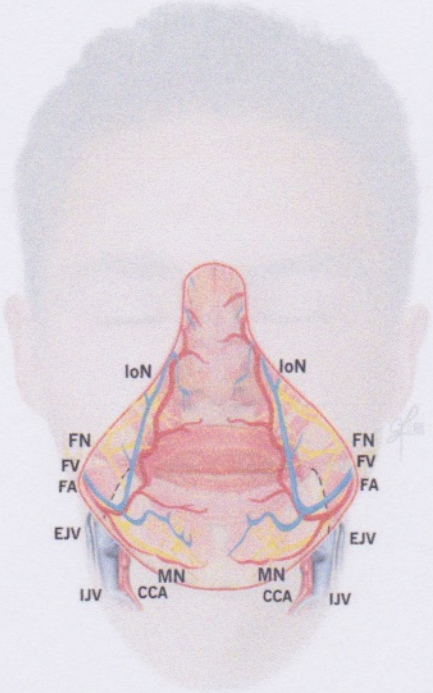

Fig. 10. Case 10. The recipient was a 27-year-old man who sustained a ballistic injury to the face. The patient underwent partial face transplantation, including the lower third of facial tissue with overlying skin, soft tissue, nose, lips, chin, and mandible. The procedure took place in November of 2009 in Amiens, France.

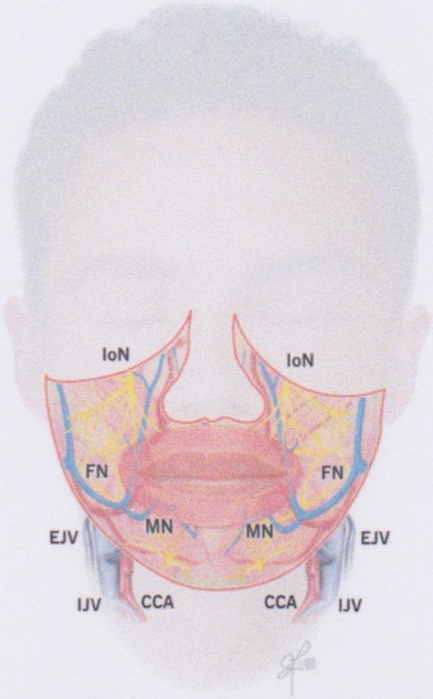

Fig. 11. Case 11. The recipient was a 34-year-old man with neurofibromatosis. The patient underwent partial face transplantation, including the lower part of face with overlying skin, soft tissue, nose, lips, chin, cheeks, bilateral parotid glands, parotid ducts, and intraoral mucosa. The procedure took place in January of 2010 in Sevilla, Spain.

It is often quite difficult to identify the exact anatomical location of the recipient vessels because of multiple reconstructive attempts. During preparation of the recipient site, these limited access vessels can be easily damaged. Thus, to prevent this problem, adequate information about available vascular anatomy and vessel patency should be provided and supported by imaging studies, such as computed tomographic angiography, three-dimensional magnetic resonance imaging, or Doppler ultrasound monitoring.[6,7]

After successful vessel repair, the next step is coaptation of the sensory and motor nerves. As reported, the trigeminal nerve is the main sensory nerve and the facial nerve is the main motor nerve repaired during face transplantation.

According to the literature reports, the facial nerve and its branches were repaired in eight face transplant cases.[2,4–9,20] In four of eight patients, the infraorbital nerves were repaired.[2,5,8,9,20] In addition, the mental nerves were repaired in two patients, whereas the buccal and supraorbital nerves were repaired in only one patient.[2,5,8,9,20] In one of two cases, instead of direct coaptation of the mental nerves, donor nerve stumps were placed near the mental foramen.[5,20] In the remaining four cases, bilateral facial nerve repair was performed without sensory nerve repair, which was not available because of the extent of original facial trauma (Table 1).[4,6,7,20] Nearly normal sensory recovery of the transplanted part of the face was observed in the first four cases between 3 and 8 months postoperatively (Fig. 14). As reported, sensory recovery was analyzed by quantitative sensory tests, including Semmes-Weinstein, two-point discrimination, pressure-specified sensory devices, and heat/cold tolerance. Interestingly, there was almost total sensory recovery in two patients who had only facial nerves repaired but none of the trigeminal nerve branches because of the extent of original trauma. Thus, the question arises, how could this be feasible? As described in the literature, sensory recovery is possible because of interconnections between the facial and trigeminal

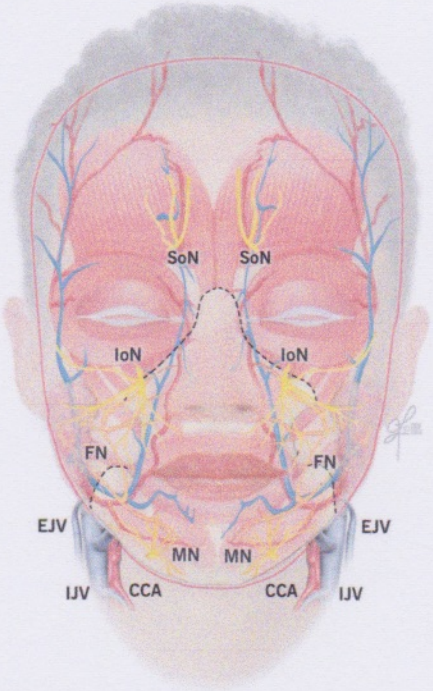

Fig. 12. Case 12. The recipient was a 30-year old man with a ballistic injury to the face. The patient underwent total facial transplantation, including overlying skin, soft tissue, nose, lips, cheeks, eyelids, zygoma, maxilla with teeth, palate, mandible, and intraoral mucosa. The procedure took place in March of 2010 in Barcelona, Spain.

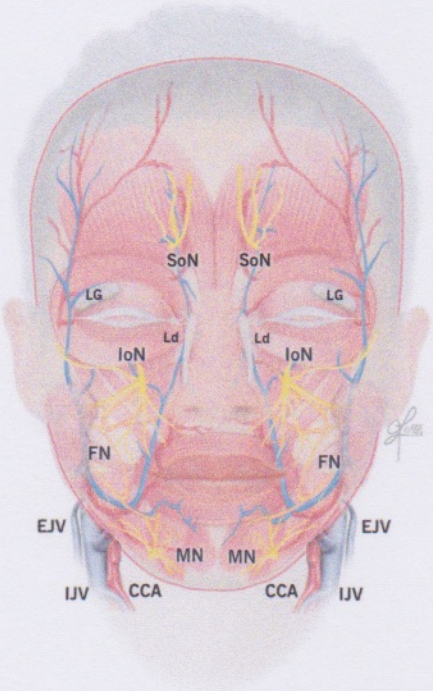

Fig. 13. Case 13. The recipient was a 35-year-old man with neurofibromatosis. The patient underwent total facial transplantation, including overlying skin, soft tissue, ears, nose, lips, cheeks, eyelids, lacrimal glands and lacrimal ducts, and intraoral mucosa. The procedure took place in June of 2010 in Paris, France.

nerve branches, so direct sensory nerve connection may not be crucial in some of the anatomically challenging cases.[28,29] In the third patient, reported by Lantieri et al., bilateral mental nerves were not repaired because they were transected at the level of the submental foramen.[5] Instead, the donor nerve was placed near the mental foramen without coaptation. Interestingly, 3 months after surgery, quantitative sensory testing showed sensory reinnervation of the skin and the presence of thermal and mechanical sensation. The authors concluded that this outcome was possible because of the ingrowth of the donor nerve into the recipient nerve or by means of direct sprouting of the donor nerve within this region of the face. In summary, sensory recovery of face composite tissue allotransplantation was reported in all patients as nearly perfect at 3 to 8 months after transplantation. However, these results are based on the small number of cases. As expected, sensation to the light touch of skin and oral mucosa recovered 3 months after transplantation; however, thermal sensation recovered between 6 and 8 months after transplantation. There was almost no difference between the results of sensory reinnervation after transplantation when compared with the results reported for the free tissue transfers and direct nerve repair cases.[30,31]

We believe that the degree of motor and functional recovery will be of utmost importance in evaluating long-term results of facial allotransplantation in the future. However, in all reported cases, motor recovery following composite tissue allotransplantation was slower and often less optimal when compared with the sensory recovery outcomes. Because of the novelty of this procedure, there are only a few long-term follow-up results of motor nerve recovery. In the first facial composite tissue allotransplantation case, Dubernard et al. reported that the patient was able to move the upper lip at 3 months after transplantation, which was followed by motion of the lower lip at approximately 4 months, complete labial contact at 6 months, and normal smile at 18

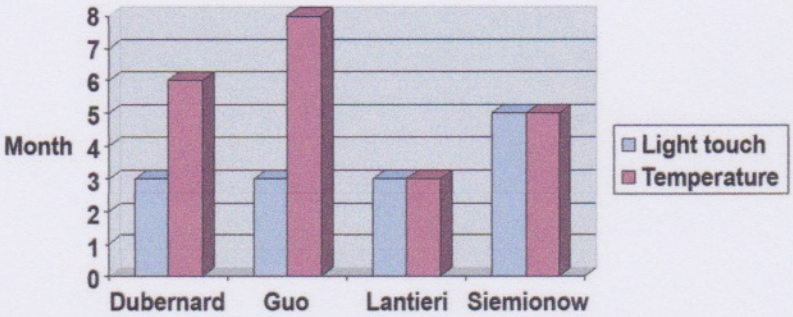

Fig. 14. Details of sensory recovery of the first four face transplantation cases.

months after transplantation. Endobuccal pressure increased progressively, and contraction of the chin muscles and nose was present at the end of the first year.[2] In contrast, in the second patient, the motor function of the facial nerve was not satisfactory and did not improve over time.[4] The patient was unable to smile either completely or symmetrically, and the function of other muscles innervated by the facial nerve has not improved over time. According to Guo, this result was attributable to poor coaptation of the facial nerves during transplant surgery. In the third patient, Lantieri et al. reported that electromyography showed no electrical activity of facial nerve reinnervation at 3 months after transplantation. After 1 year, the electromyographic recordings showed signs of motor reinnervation for both the trigeminal and facial nerves.[5] In addition, the authors reported an unexpected result indicating recovery of involuntary reflex contraction of the facial muscles in response to stimulation of the supraorbital branches of the trigeminal nerves. In the fourth patient, Siemionow et al. reported that, at 6 months after transplantation, motor recovery including facial mimetics progressed at a slow but steady rate, as demonstrated by improved facial mimetics with symmetric smiling and upper lip occlusion.[6,7] However, at this time, the patient's upper lip and lower eyelid movements were imperfect. As expected, at 1 year after transplantation, motor recovery was almost completely recovered. The reports about functional outcomes of face transplantation patients are still limited. There is a lack of published data on motor recovery of the facial nerve in five of 13 cases. This raises the question of how we can measure quantitatively motor nerve recovery outcomes following face transplantation. Several methods, such as the Carroll test, have been used to determine functional recovery after hand transplantation; thus, establishment of standard methods for monitoring functional recovery after facial transplantation will be needed for comparative analysis in the future.[32] In their article, Hui-Chou et al. suggested use of functional magnetic resonance imaging and electromyographic studies to determine motor recovery in face transplant patients.[33]

Current review of the 13 face transplant cases has confirmed that functional outcomes are different in each patient because of the complexity of trauma and acquired deficits. The restoration of osteomyocutaneous defects is more challenging when compared with reconstruction of partial myocutaneous defects. However, the most important outcome is patient satisfaction with the functional results achieved after face transplantation. According to the first four patient reports, all were able to eat, drink, and speak within 7 to 10 days after transplantation.[2,4–7] Siemionow et al. reported that functional recovery of the three-dimensional facial defect was excellent, with restoration of major functions that the patient had lacked before, including improvement of speech because of hard palate transplantation that was included in the allograft.[6,7] The latest reports on face composite tissue allotransplantation include the first tongue transplant performed by Cavadas et al. as a part of their face composite tissue allotransplantation; also, Lantieri et al. included the lacrimal gland and lacrimal ducts in their full face transplant patient.[16,23] These new functional units included in the latest face transplant cases introduce new challenges for functional recovery and measurable outcomes. For the patients, however, these may be the only available options for restoring these unique lost functions.

CONCLUSIONS

Facial allotransplantation is the most complex microsurgical and functional reconstruction currently available to plastic surgeons. It is clear that,

following anatomical reconstruction of facial deficits in one surgical procedure, facial transplantation is expected to restore both the functional and aesthetic deficits and to improve psychological and social conditions of this unique group of patients. However, because face transplantation is still regarded as an "experimental," high-risk procedure carrying a death rate of approximately 15 percent, the selection process and patient inclusion criteria should be evaluated carefully. We hope that this report on the first 13 face transplant cases will provide a useful overview of the technical aspects of face transplantation; however, the reports on long-term functional and aesthetic outcomes will help to define the future of face transplantation.

Maria Siemionow, M.D., Ph.D., D.Sc.
Dermatology and Plastic Surgery Institute
Cleveland Clinic
9500 Euclid Avenue
Cleveland, Ohio 44195
siemiom@ccf.org

ACKNOWLEDGMENTS

The authors thank Laurent Lantieri, M.D., Ph.D., Pedro C. Cavadas, M.D., Ph.D., Emmanuel Morelon, M.D., Ph.D., Tomas Gomez-Cia, M.D., Ph.D., and Juan P. Barret, M.D., Ph.D., for discussing their face transplant cases in personal communications.

REFERENCES

1. Malt RA, McKhann C. Replantation of several arms. *JAMA* 1964;189:716–722.
2. Dubernard JM, Lengelé B, Morelon E, et al. Outcomes 18 months after the first human partial face transplantation. *N Engl J Med.* 2007;357:2451–2460.
3. Siemionow MZ, ed. *The Know-How of Face Transplantation.* London: Springer; 2011.
4. Guo S, Han Y, Zhang X, et al. Human facial allotransplantation: A 2-year follow-up study. *Lancet* 2008;372:631–638.
5. Lantieri L, Meningaud JP, Grimbert P, et al. Repair of the lower and middle parts of the face by composite tissue allotransplantation in a patient with massive plexiform neurofibroma: A 1-year follow-up study. *Lancet* 2008;372: 639–645.
6. Siemionow MZ, Papay F, Djohan R, et al. First U.S. near-total human face transplantation: A paradigm shift for massive facial injuries. *Plast Reconstr Surg.* 2010;125:111–122.
7. Siemionow M, Papay F, Alam D, et al. Near-total human face transplantation for a severely disfigured patient in the USA. *Lancet* 2009;374:203–209.
8. Pomahac B, Lengele B, Ridgway EB, et al. Vascular considerations in composite midfacial allotransplantation. *Plast Reconstr Surg.* 2010;125:517–522.
9. Meningaud JP, Benjoar MD, Hivelin M, Hermeziu O, Toure G, Lantieri L. The procurement of total human face graft for allotransplantation: A preclinical study and the first clinical case. *Plast Reconstr Surg.* Epublished ahead of print June 15, 2010.
10. Partial face transplant patient goes public in Spain. *USA Today.* Available at: http://www.usatoday.com/news/health/2010-05-04-face-transplant_N.htm. Accessed May 4, 2010.
11. Devauchelle B. Microsurgical reconstruction of the face: Some outstanding indications. In: *Proceedings of the 7th Congress of the Polish Society of Oral and Craniofacial Surgery,* Jachranka, Poland; May 14–15, 2010.
12. Lantieri L, Grimbert P, Meningaud JP, Bellivier F. Face transplantation outcomes: Feasibility, reproducibility and efficacy. Paper presented at: 21st Annual Meeting of the European Association of Plastic Surgeons; May 27–30, 2010; Manchester, United Kingdom.
13. Eaton L. Spanish doctors carry out first transplantation of a full face. *BMJ.* 2010;340:c2303.
14. Eaton L. First patient to receive complete face transplant can leave hospital. *BMJ.* 2010;341:c4088.
15. Hinojosa Pérez R, Porras Lopez M, Escoresca-Ortega AM, et al. Severe rhabdomyolysis after allogeneic transplantation of facial structures: A case report. *Transplant Proc.* 2010;42: 3081–3082.
16. Charlton A. Doctors perform face transplant with eyelids. Available at: http://www.msnbc.msn.com/id/38144667. Accessed July 8, 2010.
17. Spain's first face transplant patient smiling. *USA Today.* Available at: http://www.usatoday.com/news/health/2009-08-22-spain-face-transplant_N.htm. Accessed August 22, 2009.
18. Barret J. Composite facial allotransplantation: The Barcelona full face transplant. In: *Proceedings of the Advanced Educational Courses in Plastic Surgery Meeting of the British Association of Plastic, Reconstructive and Aesthetic Surgeons,* Manchester, United Kingdom; October 1–2, 2010.
19. Hivelin M. Face transplantation outcomes: Report on the Mondor series. In: *Proceedings of the Advanced Educational Courses in Plastic Surgery Meeting of the British Association of Plastic, Reconstructive and Aesthetic Surgeons,* Manchester, United Kingdom; October 1–2, 2010.
20. Lantieri L, Hivelin M, Audard V, et al. Feasibility, reproducibility, risks and benefits of face transplantation: A prospective study of outcomes. *Am J Transplant.* 2011;11:367–378.
21. Hivelin M, Hodel J, Meningaud JP, et al. Long term stability of maxillary and mandibular bony components supplied by facial arteries through periosteal network: Report on two facial allotransplantations for ballistic traumas. Paper presented at: 2010 American Society for Reconstructive Transplantation 2nd Biennial Meeting; November 18–20, 2010; Chicago, Ill.
22. Morelon E, Testelin S, Petruzzo P, et al. New partial face allograft transplantation: Report on first six months. Paper presented at: 2010 American Society for Reconstructive Transplantation 2nd Biennial Meeting; November 18-20, 2010; Chicago, Ill.
23. Cavadas P. Clinical update and update on hand and face transplant outcomes. In: *Proceedings of the 2010 American Society for Reconstructive Transplantation 2nd Biennial Meeting,* Chicago, Ill; November 18–20, 2010.
24. Bueno J, Barret JP, Serracanta J, et al. Logistics and strategy of multi-organ procurement involving total face allograft. *Am J Transplant.* 2011;11:1091–1097.
25. Takamatsu A, Harashina T, Inoue T. Selection of appropriate recipient vessels in difficult, microsurgical head and neck reconstruction. *J Reconstr Microsurg.* 1996;12:499–507; discussion 508–513.
26. Wilhelmi BJ, Kang RH, Movassaghi K, Ganchi PA, Lee WP. First successful replantation of face and scalp with single

artery repair: Model for face and scalp transplantation. *Ann Plast Surg.* 2003;50:535–540.
27. Yin JW, Matsuo JM, Hsieh CH, Yeh MC, Liao WC, Jeng SF. Replantation of total avulsed scalp with microsurgery: Experience of eight cases and literature review. *J Trauma* 2008; 64:796–802.
28. Tohma A, Mine K, Tamatsu Y, Shimada K. Communication between the buccal nerve (V) and facial nerve (VII) in the human face. *Ann Anat.* 2004;186:173–178.
29. Baumel JJ. Trigeminal-facial nerve communications: Their function in facial muscle innervation and reinnervation. *Arch Otolaryngol.* 1974;99:34–44.
30. Kimata Y, Uchiyama K, Ebihara S, et al. Comparison of innervated and noninnervated free flaps in oral reconstruction. *Plast Reconstr Surg.* 1999;104:1307–1313.
31. Lähteenmaki T, Waris T, Asko-Seljavaara S, Sundell B. Recovery of sensation in free flaps. *Scand J Plast Reconstr Surg Hand Surg.* 1989;23:217–222.
32. Carroll D. A quantitative test of upper extremity function. *J Chronic Dis.* 1965;18:479–491.
33. Hui-Chou HG, Nam AJ, Rodriguez ED. Clinical facial composite tissue allotransplantation: A review of the first four global experiences and future implications. *Plast Reconstr Surg.* 2010;125:538–546.