

## Review Article

## Eagle syndrome: A comprehensive review



Arvind Badhey<sup>a</sup>, Ameya Jategaonkar<sup>a</sup>, Alexander Joseph Anglin Kovacs<sup>b</sup>, Sameep Kadakia<sup>a</sup>, Peter Paul De Deyn<sup>c</sup>, Yadranko Ducic<sup>d,\*</sup>, Stimson Schantz<sup>a</sup>, Edward Shin<sup>a</sup>

<sup>a</sup> Department of Otolaryngology-Head and Neck Surgery, The New York Eye and Ear Infirmary of Mount Sinai, New York, NY, United States

<sup>b</sup> Department of Otolaryngology-Head and Neck Surgery, University of Arizona College of Medicine, Phoenix, AZ, United States

<sup>c</sup> Department of Neurology, University of Groningen, Groningen, Netherlands

<sup>d</sup> Otolaryngology and Facial Plastic Surgery Associates, Fort Worth, TX, United States

## ARTICLE INFO

## Keywords:

Eagle syndrome  
Management  
Styloid process

## ABSTRACT

The objective of this report is to summarize the symptoms, diagnostic workup, necessary imaging, and management of Eagle syndrome. A comprehensive literature review was conducted on peer-reviewed publications of Eagle syndrome across multiple disciplines in order to gain a thorough understanding of the presentation, diagnosis, and management of this disorder. Diagnoses of Eagle Syndrome have increased, in part due to the awareness of physicians to patient symptomatology. While cervical pain and dysphagia are among the typical symptoms, patients can present with a wide spectrum of benign and dangerous symptoms. CT scan is the gold standard for diagnosis and can be aided by both 3D reconstructive imaging and Angiography. Treatment strategies include medical management (analgesics, corticosteroids, antidepressants, and anticonvulsants) and varied surgical approaches (extraoral, transoral, endoscopic assisted). Increased understanding by providers treating patients with Eagle Syndrome allows for a more comprehensive treatment plan. With a variety of medical regimens and more definitive surgical approaches, Eagle Syndrome can be treated safely and effectively.

## 1. Introduction

Eagle Syndrome is a rare and poorly understood clinical condition that presents with a myriad of symptoms that typically include pain in the anterolateral neck. These symptoms are associated with an abnormal styloid process. Fig. 1 shows a schematic of normal anatomy along with an elongated styloid process. Eagle initially described a pain syndrome associated with an elongated styloid process in 1937 as “stylalgia” [1]. Eagle subsequently expanded on his initial descriptions [2–6]. Historically stylohyoid pain syndromes have been delineated based upon their etiology, i.e. acquired versus congenital. Eagle syndrome proper has been described as a pain syndrome associated with an elongated styloid. The congenital variant, often described as stylohyoid syndrome has been described as a syndrome with pain and symptoms of carotid compression (presyncope, syncope, and even transient ischemic events) caused by an ossified stylohyoid ligament. Subsequent studies have expanded Eagle syndrome to include a myriad of symptoms beyond pain. Furthermore the literature has also blurred the demarcation between the acquired and congenital syndromes.

Eagle syndrome is an important clinical condition for the otolaryngologist to recognize. This is due to the variety of presentations,

potentially serious complications, and the fact that Eagle syndrome is often amenable to treatment. In this paper we present an updated review of the literature regarding Eagle/stylohyoid syndrome and discuss current/emerging treatment modalities.

## 2. Methods

For this study we aimed to identify all full-text, peer-reviewed publications pertaining to Eagle Syndrome in otolaryngology or head and neck surgery. The searches were conducted in the Ovid MEDLINE, Google Scholar, PubMed, and NCBI databases there were no regional restrictions. However only English language results were reviewed. The following search terms were used: “Eagle Syndrome”, “styloid syndrome”, “stylocarotid syndrome”, “stylohyoid syndrome”, “styloid-carotid artery syndrome”, and “elongated styloid syndrome”. The results were combined with the terms “otolaryngology” or “head and neck” to retrieve articles. All such articles were reviewed. Finally the works cited by each of these papers were reviewed in order to obtain a more complete and expansive collection of relevant literature.

\* Corresponding author.

E-mail addresses: [akbadhey@gmail.com](mailto:akbadhey@gmail.com) (A. Badhey), [Ameya.a.jategaonkar@gmail.com](mailto:Ameya.a.jategaonkar@gmail.com) (A. Jategaonkar), [akovacs@email.arizona.edu](mailto:akovacs@email.arizona.edu) (A.J. Anglin Kovacs), [skadakia@nyee.edu](mailto:skadakia@nyee.edu) (S. Kadakia), [p.p.de.deyn@umcg.nl](mailto:p.p.de.deyn@umcg.nl) (P.P. De Deyn), [yducic@sbcglobal.net](mailto:yducic@sbcglobal.net) (Y. Ducic), [sschantz@nyee.edu](mailto:sschantz@nyee.edu) (S. Schantz), [eshin@nyee.edu](mailto:eshin@nyee.edu) (E. Shin).

<http://dx.doi.org/10.1016/j.clineuro.2017.04.021>

Received 31 January 2017; Received in revised form 26 April 2017; Accepted 27 April 2017

Available online 06 May 2017

0303-8467/ © 2017 Elsevier B.V. All rights reserved.

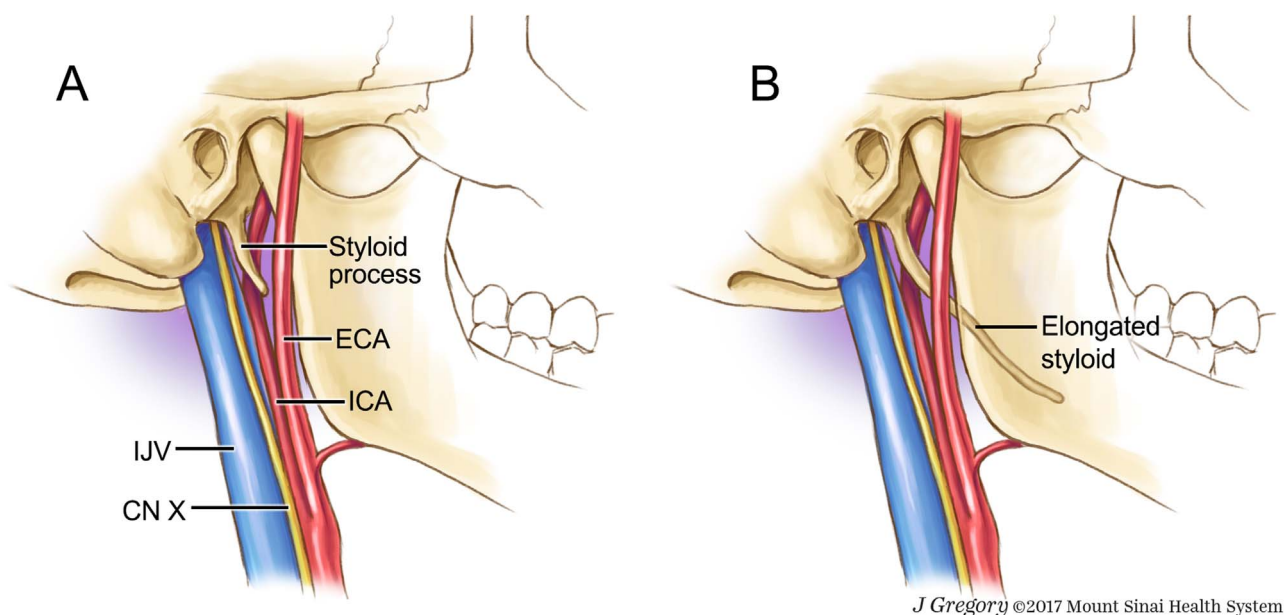


Fig. 1. Normal anatomy of the styloid process (Fig. 1a). Elongated styloid process as found in patients with Eagle Syndrome (Fig. 1b). (We would like to acknowledge Jill Gregory, senior illustrator, from the Mount Sinai Health System for providing this artwork. This artwork has been used with permission from Mount Sinai Health System).

### 3. Background

Abnormalities in the stylohyoid complex were first identified in animals by Vesalius in 1543 [7]. The first description in humans was published by Marchetti in 1656 [8]. Watt Eagle first described the combination of pain associated with an abnormal stylohyoid complex in 1937 and later reported a case series of over 200 patients [1,5]. Eagle found that about 4% of patients that have abnormalities with their stylohyoid complex have pain [5]. He described two different presentations the classic type and the carotid artery syndrome. At the end of his studies he concluded that tonsillectomy was a potential cause. Further studies have examined the relationship between tonsillectomy and Eagle syndrome and have not found the same relationship [9]. Prior to beginning a detailed discussion of Eagle Syndrome, a brief illustrative case will be presented to provide context for the ensuing report.

### 4. Example case illustration

A 56-year old female presented to the clinic with a 2-year history of right-sided throat pain and globus sensation. The patient denied dysphagia, weight loss, or other associated symptoms. The patient had tried several courses of anti-inflammatory medication and antibiotics without sufficient relief. A complete head and neck examination including fiberoptic laryngoscopy was performed, and the only pertinent finding was pain in the right neck with deep palpation. Intraoral palpation of the right retromolar trigone and right peritonsillar region also elicited pain. A computed tomography scan of the neck was obtained as displayed in Figs. 2 and 3. Based on the radiographic analysis, the diagnosis of Eagle Syndrome was made. As the patient had failed medical management, surgical intervention was offered and the patient was keen on pursuing this option. The patient underwent a tonsillectomy sparing transoral resection of the styloid process with primary closure, and had immediate resolution of symptoms following awakening in the recovery unit. She was discharged the same day and had an uneventful post-operative course with only minimal pain medication requirements and quick resolution of regular oral intake.

### 5. Epidemiology

There have been many studies since the identification of Eagle Syndrome that have sought to determine the incidence and prevalence

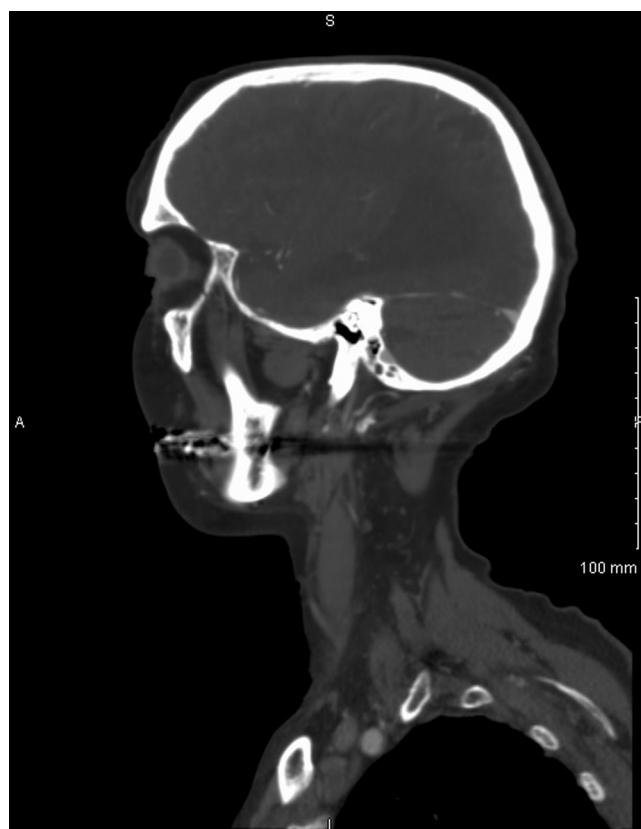
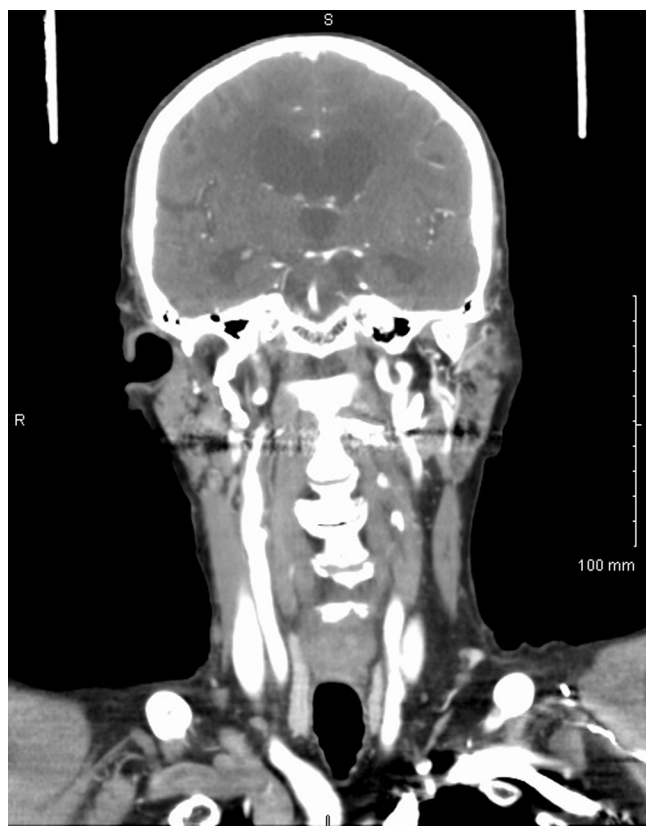

Fig. 2. A sagittal CT scan of a patient with an elongated styloid hyoid complex (We would like to acknowledge Dr. Roy Holliday from Mount Sinai Health System for providing these images).

of this condition. The variability in determining the epidemiology of this condition is likely due to differences in the diagnostic criteria in radiologic imaging. Some have suggested that the accepted length of the normal styloid process is approximately 2.5 cm, with 3 cm regarded as the upper limit of normal [10,11]. Radiologically, some studies have used stylohyoid length greater than 2.5 cm as abnormal [10]. Other studies have defined length greater than 4.0 cm as abnormal as this



**Fig. 3.** A coronal CT scan of a patient with an elongated styloid hyoid complex (We would like to acknowledge Dr. Roy Holliday from Mount Sinai Health System for providing these images).

length has a higher association with pain [11]. Incidences of abnormal stylohyoid length range from 4% to 7.3% [5,12]. The incidence is higher if calcification of the stylohyoid complex is included 22%–84% [13,14]. Despite the high incidence of abnormal stylohyoid complex, the incidence of pain associated with these abnormalities is 4–10% [15]. While stylohyoid abnormalities often occur bilaterally, pain usually presents unilaterally [10].

## 6. Embryology/pathophysiology/etiology

The development of the stylohyoid complex develops from the Reichert cartilage of the second branchial arch early on during the embryologic development. As development progresses the second branchial arch becomes four separate segments, the stylohyal, ceratohyal, hypohyal, and basihyal. The stylohyal develops with the tympanohyal to become the styloid process. Through ossification the stylohyal develops into the stylohyoid ligament, while the hypohyal develops into the minor horn of the hyoid and the basihyal becomes the hyoid body [16,17].

There are many different etiologies that have been proposed to explain Eagle syndrome. Murtagh listed three possible explanations, which lead to abnormal stylohyoid complexes [15]. One of the theories relates to retained embryologic cartilage tissue from Reichert's cartilage. The second theory is calcification of the stylomandibular ligament. The third explanation is expansion of osseous tissue at the origin of the stylomandibular ligament.

Steinmann detailed other explanations relating to trauma [18]. He described trauma leading to reactive hyperplasia. His second theory was traumatic induced reactive metaplasia, which leads to ossification. His third theory is the abnormal stylohyoid complex is an anatomic variant without any trauma. Other explanations by Camarda have focused on changes due to aging leading to inflammation [19].

While the underlying cause for Eagle syndrome has not yet been settled, there is better understanding of how an abnormal stylohyoid complex causes the symptoms. An elongated or ossified stylohyoid complex leads to compression of the neurovascular structures surrounding the stylohyoid complex. The facial nerve, auriculo-temporal nerve, lingual nerve, chorda tympani, glossopharyngeal nerve, and hypoglossal nerve are in close proximity to the stylohyoid complex. In addition the stylohyoid complex bifurcates the internal and external carotid arteries. As such compression/impingement of these structures by an elongated styloid or abnormal stylohyoid complex can present in a variety of different manners.

## 7. Clinical presentation

Eagle first described two syndromes associated with elongation/aberrant ossification of the stylo-hyoid apparatus. The first, classic Eagle syndrome was described as pain, dysphagia, and a foreign body sensation that presents immediately after tonsillectomy. Eagle also described stylocarotid syndrome in which an elongated styloid compresses the carotid artery and results in pain (parietal/peri-orbital), visual disturbances, and syncope [3,4,6].

Subsequent studies have documented that an elongated styloid process can present with a myriad of symptoms and with no relation to tonsillectomy. Pain is one of the most common symptoms. Patients often complain of unilateral pain, on the side of the elongated styloid process. Some of this pain may refer or radiate to the ear/jaw and present as otalgia or temporomandibular joint pain. Pharyngeal symptoms are also commonly reported in cases of Eagle syndrome. These complaints range from dysphagia/odynophagia, foreign body sensation, pain with yawning, or pain with turning of the head [16,20–22]. In addition to pain reports exist of various neurological complaints being associated with an elongated styloid process. Chang et al. describe a patient with an elongated styloid process who developed Horner's syndrome after chiropractic neck manipulation [23]. Eagle syndrome has also been associated with potential catastrophic complications. The literature contains many reports of transient ischemic attacks and stroke being associated with Eagle Syndrome. Moreover elongated styloid process is a known risk factor for carotid artery dissection [24–28]. Eagle syndrome has also been associated with carotid stent fracture [29].

The literature also contains reports of persistent mouth ulceration, toothache, and auditory symptoms including hearing loss, tinnitus, and ear “popping” [30,31]. Case reports also exist of dysphonia being associated with an elongated styloid [32]. Reports also exist of patients with glossodynia experiencing symptom relief with resection of an elongated styloid and Eagle syndrome presenting a cervical neck mass [33,34].

## 8. Diagnostic work up

The diagnosis begins with a history that raises the clinical suspicion for Eagle syndrome. Physical exam coupled with the patient history can guide further work-up. Pharyngeal palpation, especially of the tonsil or within the tonsillar fossa can be diagnostic. Relief of symptoms upon infiltration of lidocaine into the anterior pillar and into the tonsillar fossa can be diagnostic for Eagle syndrome [16].

Imaging is another useful tool in both diagnosis and treatment of an elongated styloid. Plain radiographs of the skull may be useful in showing an elongated styloid. Lateral views may be enable visualization of an elongated styloid. Panoramic radiographs too have been shown to be effective in diagnosing Eagle syndrome. The oral surgery and dental literature describes the efficacy of cone beam CT in evaluating styloid length [35]. CT scans represent the gold standard for diagnosis of an elongated styloid process. CT scans add soft tissue data that allow for an appreciation of the relationship between the bony styloid and adjacent neuro-vascular structures [15,36]. CT Angiography can provide further



information regarding carotid flow especially if stroke or dissection is suspected. Other imaging modalities have been explored such as transoral ultrasound and bone scintigraphy but their efficacy remains unknown at this time [25,37].

## 9. Management

### 9.1. Conservative management

The management of Eagle syndrome is commonly divided into conservative methods of medical management or more definitive surgical treatment.

Basic medical therapy can be further divided into first-line analgesics such as NSAIDs and alternative management consisting of a combination of anticonvulsants, antidepressants, local injections and manipulation [38]. For patients who refuse surgery, Han et al report on a viable multi-drug approach with gabapentin, tianeptine, tramadol, and acetaminophen, coupled with local injections of 1 mg triamcinolone/mepivacaine. A weekly stellate ganglion block added to this regimen can result in near complete resolution of symptoms [39]. Case reports have shown additional success utilizing a dual therapy with pregabalin and anticonvulsants such as carbamazepine [40]. Taheri et al. demonstrated an 80% decrease in symptoms after 6 months of treatment with pregabalin (75 mg daily) and amitriptyline (10 mg daily) [41]. Local injection of anesthetic and dexamethasone has been proven effective as a final conservative option. However the effects of these injections diminish with time [19,42]. While there have been reports of physical manipulation and manual transpharyngeal fracture, recommendations have come out against these techniques due to the risk to adjacent structures such as the carotid artery [43–45].

### 9.2. Surgical treatment

The literature tends to support that surgical treatment results in more definitive treatment and long lasting symptomatic relief [46]. Surgical management is typically divided into the intraoral and cervical approaches [47].

The traditional intraoral approach begins with a tonsillectomy, after which the tonsillar fossa is palpated to identify the tip of the styloid process. Dissection is then conducted down through the medial pterygoid and superior constrictor muscles. Blunt dissection is then used to identify the styloid tip. The dissection is taken to the periosteum of the styloid process and the ligamentous attachments to the process are removed. Finally a rongeur tool is used to fracture and remove the styloid tip as proximally as possible. The tonsillar fossa is then sutured closed [46]. The lack of an external scar allows for better cosmesis, however it does not allow for complete exposure of the styloid process. Nevertheless it does allow for adequate resection to alleviate symptoms in most cases. Postulated risks of this intraoral approach include infection and poor exposure to control bleeding, especially in the case of a carotid injury. There is also some risk of post-operative airway edema and as such bilateral cases are a relative contraindication [48].

There has been a renewed focus on tonsil sparing intraoral techniques. These begin with an incision in the anterior tonsillar pillar and retraction of the tonsil medially on a bipediced flap. A dissection similar to the one in the traditional approach is then carried out down to the styloid periosteum. Torres et al. recently reported on success with this approach [49]. Transoral approaches have advanced further as demonstrated by an endoscopic assisted approach by Al Weteid [50].

An external, cervical approach provides the best exposure with the caveat of a scar. This approach begins with an oblique incision made at the angle of the mandible and dissection is carried down to the sternocleidomastoid muscle. The sternocleidomastoid is retracted posterolaterally. Subsequently the space between the parotid gland and the posterior belly of the digastric muscle is explored. The dissection is completed with subperiosteal dissection onto the styloid process and

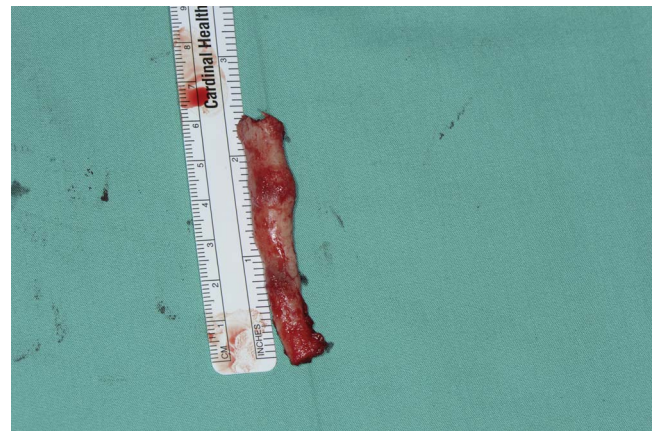

Fig. 4. Intraoperative view of excised styloid process in a patient with Eagle Syndrome. (We would like to acknowledge Dr. Yadranko Ducic for providing this photograph).

resection of the styloid process. One of the concerning risks of this approach is potential for injury to the marginal mandibular branch of the facial nerve [48]. Ultimately various surgical techniques exist for the treatment of Eagle syndrome, each with its own merits. Fig. 4 shows an intraoperative photograph of an excised styloid process from a patient with Eagle Syndrome.

## 10. Conclusion

Eagle syndrome has a large variety of clinical presentations as evidenced by the multitude of nonspecific symptoms. As a result, it is important to understand the diagnostic workup, relevant imaging, and ultimate treatment options. With advances in medical management and surgical approaches to the styloid process, Eagle syndrome has become recognized more readily and has an established group of treatment options.

## References

- [1] W.W. Eagle, Elongated styloid processes: report of two cases, *Arch. Otolaryngol. Head Neck Surg.* 25 (5) (1937) 584–587, <http://dx.doi.org/10.1001/archotol.1937.00650010656008>.
- [2] W.W. Eagle, Sphenopalatine ganglion neuralgia, *Arch. Otolaryngol. Head Neck Surg.* 35 (1) (1942) 66–84, <http://dx.doi.org/10.1001/archotol.1942.00670010067004>.
- [3] W.W. Eagle, Elongated styloid process; further observations and a new syndrome, *Arch. Otolaryngol.* 47 (5) (1948) 630–640.
- [4] W.W. Eagle, Symptomatic elongated styloid process; report of two cases of styloid process-carotid artery syndrome with operation, *Arch. Otolaryngol.* 49 (5) (1949) 490–503.
- [5] W.W. Eagle, Elongated styloid process; symptoms and treatment, *AMA Arch. Otolaryngol.* 67 (2) (1958) 172–176.
- [6] W.W. Eagle, The symptoms, diagnosis and treatment of the elongated styloid process, *Am. Surg.* 28 (1962) 1–5.
- [7] Vesalius, A., *De Humani Corporis Fabrica*, Padua, Italy, 1543.
- [8] Marchetti, D., *Anatomia*, 1656.
- [9] M. Fritz, Elongated styloid process: a cause of obscure throat symptoms, *Arch. Otolaryngol. Head Neck Surg.* 31 (6) (1940) 911–918, <http://dx.doi.org/10.1001/archotol.1940.00660010926002>.
- [10] R.W. Correll, J.L. Jensen, J.B. Taylor, R.R. Rhyne, Mineralization of the stylohyoid-stylomandibular ligament complex. A radiographic incidence study, *Oral Surg. Oral Med. Oral Pathol.* 48 (4) (1979) 286–291.
- [11] P.A. Monsour, W.G. Young, Variability of the styloid process and stylohyoid ligament in panoramic radiographs, *Oral Surg. Oral Med. Oral Pathol.* 61 (5) (1986) 522–526.
- [12] S.M. Kaufman, R.P. Elzay, E.F. Irish, Styloid process variation: radiologic and clinical study, *Arch. Otolaryngol.* 91 (5) (1970) 460–463.
- [13] M.K.O. Carroll, Calcification in the stylohyoid ligament, *Oral Surg. Oral Med. Oral Pathol.* 58 (5) (1984) 617–621, [http://dx.doi.org/10.1016/0030-4220\(84\)90089-6](http://dx.doi.org/10.1016/0030-4220(84)90089-6).
- [14] D. Miller, Eagle's syndrome and the trauma patient. Significance of an elongated styloid process and/or ossified stylohyoid ligament, *Funct. Orthod.* 14 (2) (1997) 30–35.
- [15] R.D. Murtagh, J.T. Caracciolo, G. Fernandez, CT findings associated with eagle syndrome, *Am. J. Neuroradiol.* 22 (7) (2001) 1401–1402.

- [16] L. Montalbetti, D. Ferrandi, P. Pergami, F. Savoldi, Elongated styloid process and Eagle's syndrome, *Cephalalgia* 15 (2) (1995) 80–93.
- [17] J. Perellò, La Apofisis Estiloides, *Acta Orl. Iber. Am.* (1953) 325–346.
- [18] E.P. Steinmann, Styloid syndrome in absence of an elongated process, *Acta Otolaryngol.* 66 (4) (1968) 347–356.
- [19] A.J. Camarda, C. Deschamps, D.I. Forest, Stylohyoid chain ossification: a discussion of etiology, *Oral Surg. Oral Med. Oral Pathol.* 67 (5) (1989) 508–514.
- [20] F. Costantinides, G. Vidoni, C. Bodin, R. Di Lenarda, Eagle's syndrome: signs and symptoms, *Cranio* 31 (1) (2013) 56–60, <http://dx.doi.org/10.1179/crn.2013.008>.
- [21] P. Lindeman, The elongated styloid process as a cause of throat discomfort. Four case reports, *J. Laryngol. Otol.* 99 (5) (1985) 505–508.
- [22] P. van Schaik, G.-J. de Borst, Compression of the internal carotid artery by turning the head to the left, *Eur. J. Vasc. Endovasc. Surg.* 50 (6) (2015) 701, <http://dx.doi.org/10.1016/j.ejvs.2015.09.026>.
- [23] C.A. Chang, T. Lin, K. Fung, M. Sharma, J.A. Fraser, Isolated horner syndrome from an elongated styloid process (Eagle syndrome), *J. Neuroophthalmol.* 35 (4) (2015) 387–389, <http://dx.doi.org/10.1097/WNO.0000000000000260>.
- [24] B. Hebant, E. Guegan-Massardier, V. Macaigne, A. Triquenot-Bagan, Ischemic stroke due to internal carotid artery dissection associated with an elongated styloid process (Eagle syndrome), *J. Neurol. Sci.* 372 (2017) 466–467, <http://dx.doi.org/10.1016/j.jns.2016.10.055>.
- [25] N. Ohara, M. Sakaguchi, S. Okazaki, K. Nagano, K. Kitagawa, Internal carotid artery dissection caused by an elongated styloid process: usefulness of transoral ultrasonography, *J. Stroke Cerebrovasc. Dis.* 21 (8) (2012) 918.e7–918.e8, <http://dx.doi.org/10.1016/j.jstrokecerebrovasdis.2012.05.014>.
- [26] D. Renard, S. Azakri, C. Arquizan, B. Swinnen, P. Labauge, V. Thijs, Styloid and hyoid bone proximity is a risk factor for cervical carotid artery dissection, *Stroke* 44 (9) (2013) 2475–2479, <http://dx.doi.org/10.1161/STROKEAHA.113.001444>.
- [27] J.M. Raser, M.T. Mullen, S.E. Kasner, B.L. Cucchiara, S.R. Messé, Cervical carotid artery dissection is associated with styloid process length, *Neurology* 77 (23) (2011) 2061–2066, <http://dx.doi.org/10.1212/WNL.0b013e31823b4729>.
- [28] T. Todo, M. Alexander, C. Stokol, P. Lyden, G. Braunstein, B. Gewertz, Eagle syndrome revisited: cerebrovascular complications, *Ann. Vasc. Surg.* 26 (5) (2012) 729.e1–729.e5, <http://dx.doi.org/10.1016/j.avsg.2011.12.005>.
- [29] J.D. Hooker, D.A. Joyner, E.P. Farley, M. Khan, Carotid stent fracture from stylocarotid syndrome, *J. Radiol. Case Rep.* 10 (6) (2016) 1–8, <http://dx.doi.org/10.3941/jrcr.v10i6.1618>.
- [30] J.E. Sivers, G.K. Johnson, Diagnosis of Eagle's syndrome, *Oral Surg. Oral Med. Oral Pathol.* 59 (6) (1985) 575–577.
- [31] R.L. Ettinger, J.G. Hanson, The styloid or Eagle syndrome: an unexpected consequence, *Oral Surg. Oral Med. Oral Pathol.* 40 (3) (1975) 336–340.
- [32] S.J. Blatchford, S.W. Coulthard, Eagle's syndrome: an atypical cause of dysphonia, *Ear. Nose. Throat J.* 68 (1) (1989) 48–51.
- [33] C. Texier, N.P. Dang, R. Dallel, C. Deschaumes, J.M. Garcier, M. D'Incan, Eagle syndrome, a rare cause of glossodynia, *Eur. J. Dermatol.* 22 (5) (2012) 702–703, <http://dx.doi.org/10.1684/ejd.2012.1801>.
- [34] S. Kouki, M. Guerfel, Eagle's syndrome presenting as a cervical mass, *BMJ Case Rep.* 2013 (2013), <http://dx.doi.org/10.1136/bcr-2013-200312>.
- [35] H. Oztunç, B. Evlice, U. Tatli, A. Evlice, Cone-beam computed tomographic evaluation of styloid process: a retrospective study of 208 patients with orofacial pain, *Head Face Med.* 10 (5) (2014), <http://dx.doi.org/10.1186/1746-160x-10-5>.
- [36] H. Chen, Y. Cheng, X. Liu, G. Li, L. Wang, X. Li, Function of three-dimensional reconstruction of CT scan to the operation of eagle syndrome, *Lin Chung Er Bi Yan Hou Tou Jing Wai Ke Za Zhi* 28 (21) (2014) 1688–1690.
- [37] S. Yildiray, G. Cumali, C. Ismail, T.E. Elif, A patient with Eagle syndrome: radiological and scintigraphic evaluation, *Indian J. Dent. Res.* 23 (2) (2012) 283–285, <http://dx.doi.org/10.4103/0970-9290.100442>.
- [38] M. Piagkou, S. Anagnostopoulou, K. Kouladouros, G. Piagkos, Eagle's syndrome: a review of the literature, *Clin. Anat.* 22 (5) (2009) 545–558, <http://dx.doi.org/10.1002/ca.20804>.
- [39] M.K. Han, D.W. Kim, J.Y. Yang, Non surgical treatment of Eagle's syndrome—a case report, *Korean J. Pain* 26 (2) (2013) 169–172, <http://dx.doi.org/10.3344/kjp.2013.26.2.169>.
- [40] Y. Malik, J.A. Dar, Seizures with an atypical aetiology in an elderly patient: Eagle's syndrome—how does one treat it? *BMJ Case Rep.* 2015 (2015), <http://dx.doi.org/10.1136/bcr-2014-206136>.
- [41] A. Taheri, S. Firouzi-Marani, M. Khoshbin, Nonsurgical treatment of stylohyoid (Eagle) syndrome: a case report, *J. Korean Assoc. Oral Maxillofac. Surg.* 40 (5) (2014) 246–249, <http://dx.doi.org/10.5125/jkaoms.2014.40.5.246>.
- [42] T. Maher, H. Shankar, Ultrasound-guided peristyloid steroid injection for eagle syndrome, *Pain Pract.* (November) (2016), <http://dx.doi.org/10.1111/papr.12497>.
- [43] B.N. Green, L.K.M. Browske, Elongated styloid processes and calcified stylohyoid ligaments in a patient with neck pain: implications for manual therapy practice, *J. Chiropr. Med.* 13 (2) (2014) 128–133, <http://dx.doi.org/10.1016/j.jcm.2014.06.006>.
- [44] D.C. Chase, A. Zarmen, W.C. Bigelow, J.M. McCoy, Eagle's syndrome: a comparison of intraoral versus extraoral surgical approaches, *Oral Surg. Oral Med. Oral Pathol.* 62 (6) (1986) 625–629.
- [45] P.S. Murthy, P. Hazarika, M. Mathai, A. Kumar, M.P. Kamath, Elongated styloid process: an overview, *Int. J. Oral Maxillofac. Surg.* 19 (4) (1990) 230–231.
- [46] C. Mortellaro, P. Biancucci, G. Picciolo, V. Vercellino, Eagle's syndrome: importance of a corrected diagnosis and adequate surgical treatment, *J. Craniofac. Surg.* 13 (6) (2002) 755–758.
- [47] T. Müderris, S. Bercin, E. Sevil, S. Beton, M. Kırıs, Surgical management of elongated styloid process: intraoral or transcervical? *Eur. Arch. Otorhinolaryngol.* 271 (6) (2014) 1709–1713, <http://dx.doi.org/10.1007/s00405-013-2664-0>.
- [48] D.J. Fusco, S. Asteraki, R.F. Spetzler, Eagle's syndrome: embryology, anatomy, and clinical management, *Acta Neurochir. (Wien)* 154 (7) (2012) 1119–1126, <http://dx.doi.org/10.1007/s00701-012-1385-2>.
- [49] A.C. Torres, J.S. Guerrero, H.C. Silva, A modified transoral approach for carotid artery type Eagle syndrome: technique and outcomes, *Ann. Otol. Rhinol. Laryngol.* 123 (12) (2014) 831–834, <http://dx.doi.org/10.1177/0003489414538770>.
- [50] A.S. Weteid Al, M. Miloro, Transoral endoscopic-assisted styloidectomy: how should Eagle syndrome be managed surgically? *Int. J. Oral Maxillofac. Surg.* 44 (9) (2015) 1181–1187, <http://dx.doi.org/10.1016/j.ijom.2015.03.021>.