

Face Transplant Graft Procurement: A Preclinical and Clinical Study

Jean-Paul Meningaud, M.D.,
Ph.D.

Antoine Paraskevas, M.D.

Fabio Ingallina, M.D.

Eric Bouhana, M.D.

Laurent Lantieri, M.D.

Créteil, France

Background: Most articles on face composite tissue allotransplantation have considered ethical and immunologic aspects. Few have dealt with the technical aspects of graft procurement. The authors report the technical difficulties involved in procuring a lower face graft for allotransplantation.

Methods: After a preclinical study of 20 fresh cadavers, the authors carried out an allotransplantation of the lower two-thirds of the face on a patient in January of 2007. The graft included all the perioral muscles, the facial nerves (VII, V2, and V3) and, for the first time, the parotid glands.

Results: The preclinical study and clinical results confirm that complete revascularization of a graft consisting of the lower two-thirds of the face is possible from a single facial pedicle. All dissections were completed within 3 hours. Graft procurement for the clinical study took 4 hours. The authors harvested the soft tissues of the face en bloc to save time and to prevent tissue injury. They restored the donor's face within approximately 4 hours, using a resin mask colored to resemble the donor's skin tone. All nerves were easily reattached. Voluntary activity was detected on clinical examination 5 months postoperatively, and electromyography confirmed nerve regrowth, with activity predominantly on the left side. The patient requested local anesthesia for biopsies performed in month 4.

Conclusions: Partial facial composite tissue allotransplantation of the lower two-thirds of the face is technically feasible, with a good cosmetic and functional outcome in selected clinical cases. Flaps of this type establish vascular and neurologic connections in a reliable manner and can be procured with a rapid, standardized procedure. (*Plast. Reconstr. Surg.* 122: 1383, 2008.)

Face composite tissue allotransplantation has been the subject of heated debate between surgeons and ethics specialists over the past 5 years.¹ Most scientific publications on this procedure have considered ethical,^{2,3} immunologic,⁴ or other aspects relating to the recipient.^{5,6} Very few have dealt with the technical problems involved in graft procurement.⁷ Most plastic surgeons trained in microsurgery have a perfect understanding of facial anatomy and can perform the vascular and nervous anastomoses required for such flaps. However, they are not accustomed to being involved in activity related to allotransplantation. Facial transplants differ from hand transplants in that very few cases of facial replan-

tation have been described, whereas finger and hand replantation is common. As in heart and liver transplantation, specific surgical techniques and training are required before the procedure can be incorporated into clinical practice.

Several important questions must be addressed concerning the procurement of grafts for facial allotransplantation. For example, what type of graft is most reliable in terms of the subsequent establishment of vascular connections? How should muscles, nerves, and salivary glands be transferred to ensure correct function? How can the graft be procured reliably under the time constraints required to preserve the other organs of a hemodynamically unstable donor? How can the donor's face be restored in a manner acceptable to his or her family? We report here the technical

From the Université Paris 12, Faculté de Médecine, and Assistance Publique-Hopitaux de Paris, Groupe Henri Mondor-Albert Chenevier, Service de Chirurgie Plastique, Reconstructrice, et Esthétique.

Received for publication February 12, 2008; accepted April 24, 2008.

Copyright ©2008 by the American Society of Plastic Surgeons

DOI: 10.1097/PRS.0b013e3181882146

Disclosure: None of the authors has a financial interest in any of the products, devices, or drugs mentioned in this article.

difficulties involved in the procurement of a lower facial graft for allotransplantation.

MATERIALS AND METHODS

Anatomical Observations on Cadavers

We studied 20 fresh cadavers in a two-step preclinical study. In the first step, we used 10 cadavers to investigate the possibilities for harvesting various facial units. These dissections were carried out to evaluate the various anatomical structures of the face, their relationships, and different surgical planes. In the second step, we used the other 10 cadavers to develop methods for reconstructing the lower two-thirds of the face.

For all dissections, we attempted to simulate real transplantation procedures as closely as possible. A pair of cadavers was used for each dissection. The facial flap removed from the first cadaver was used to restore the defect created by procurement of the facial flap from the second cadaver and vice versa. This made it possible to evaluate the adaptation of the procured facial flap to a different skeletal structure and, thus, to estimate the possible final aesthetic result. Photographs were taken before and after every "facial switch" and compared.

The vascular anatomy within the free facial flap was studied both by simple transillumination and by the intraarterial injection of radiopaque material (lead oxide gel) in three cadavers. All of these flaps were photographed (Fig. 1). We recorded the time from the start of the dissection to the end of the restoration process.

Donor Mask Production

French law requires the appearance of the donor's body to be respected, and conformity with

this regulation is carefully checked by the French Transplantation Agency. In the case of facial allotransplantation, a molded mask must be made during graft procurement to ensure that this obligation is respected. During the cadaver study, we compared two different methods of mask manufacture based on two different materials: silicone and acrylic resin. The evaluation criteria were the speed with which the mask could be produced and resemblance to the original face.

Graft Procurement Protocol and the Clinical Case

The facial graft was procured from a brain-dead donor in January of 2007. Donors were screened based solely on ABO compatibility, skin phototype, and gender. Tracheotomy was the first step in the procedure. A mold was then made of the donor's face for the subsequent manufacture of a mask to restore the appearance of the donor after graft procurement (Fig. 2). A layer of alginates was placed over the face, followed by bands of plaster to prevent distortion during unmolding and to reinforce the mold. Once set, the mold was removed and used to produce a resin mask during the procurement procedure.

The face was harvested from a donor with a beating heart, before the removal of the other organs. The head and neck region was in the operative field; the anesthesiologists had access to only the lower part of the donor. This arrangement made it impossible to remove other organs

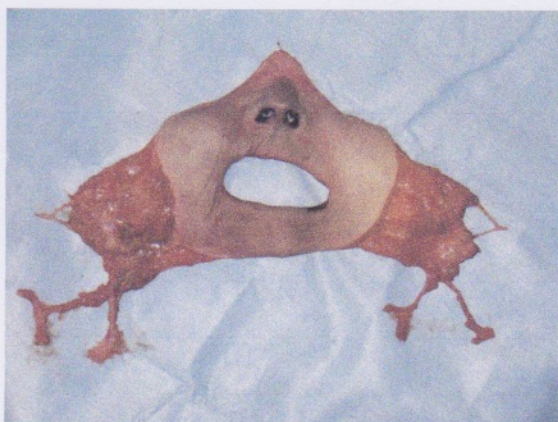


Fig. 1. A partial face transplant, including the lower two-thirds of the face, in the preclinical study.

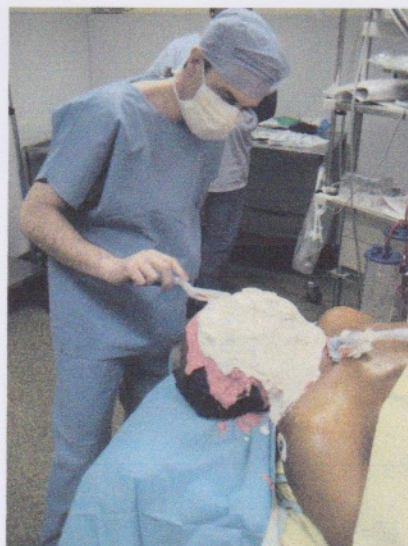


Fig. 2. Mold of the donor's face, produced from alginates and plaster before graft procurement.

simultaneously, even if all the transplant teams could, in theory, operate at the same time. The drawing of the flap began in the glabella and followed the lateral limit of the nose and the infraorbital rim to the root of the helix. It then continued downward in the preauricular area to a location 5 cm below the mandibular angle, and continued forward to join the opposite side in the anterior cervical area above the tracheotomy site (Fig. 3). The dissection started on the right side. The temporal vessels were ligated. The facial nerve was approached by means of a parotidectomy access route (Fig. 4, *above, left*). It was dissected until its bifurcation and transected at its exit from the stylomastoid foramen. The flap was raised toward the front, following the masseter plane (beneath its aponeurosis) to the oral mucosa, along with the facial nerve, the parotid gland—including Stensen's duct, the superficial portion, and part of the deep portion—the mental nerve, the orbicularis oris, and most of the smile muscles (including both the zygomaticus and levators). At the anterior edge of the masseter muscle, the dissection plane was subperiosteal at the level of the horizontal branch of the mandible. The mental nerve was identified at its exit from the mental foramen and communicated with the oral cavity at the level of the cheek. The entire cheek mucosa was harvested along the parotid ostium. The buccal fat pad was left behind. On the dental part of the maxilla and mandible, the mucosa was cut at the gingiva.

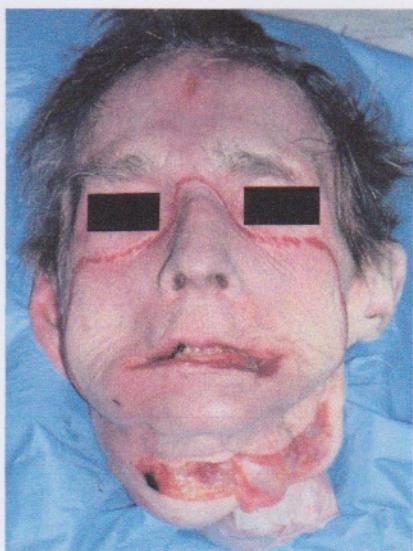

Fig. 3. The outline of the nasolabial complex to be procured from a cadaver (legal restrictions prevent us from showing a drawing of the donor for the clinical case).

The upper incision ran along the zygomatic arch, followed the infraorbital margin, and ended on the nasofrontal suture. The dissection was subperiosteal to the malar bone (Fig. 4, *above, right*). The infraorbital nerve was isolated and transected at its foramen. The insertions of the zygomatic muscles were divided and the muscles were included in the flap. The nose was removed, along with the skin, cartilage (alar, triangular, and most of the septum), nasal bones, and mucosa. A low-to-low lateral osteotomy was performed, as for rhinoplasty. This dissection of the nose as an intact unit was carried out to save time. A similar sequence was performed on the left side. In our protocol, simple stitches were used for nasal bone fixation on the recipient, with no mucosal suturing or splinting.

A cervical flap (skin and the platysma muscle) was then generated by undermining. The anterior border of the sternocleidomastoid muscle was retracted laterally and both facial arteries and veins were isolated. The vessels were dissected from their origin by means of a cervical approach, leaving a graft attached by both external carotid arteries and thyrolinguofacial trunks (Fig. 4, *center, left*). The submandibular glands were included in the flap, in a sort of en bloc dissection, minimizing the risk of dissecting the marginal branch of the facial nerve and the facial vessels at this level (Fig. 4, *center, right*). The graft (Fig. 4, *below, left*) was washed with heparin-containing saline and transported in a standard icebox in preservation solution (Solution de Conservation des Organes et des Tissus; MacoPharma, Mouvaux, France). Once all the organs had been harvested and a painted resin mask, prepared during the operation, had been fitted to the donor's face (Fig. 4, *below right*), the cadaver was returned to the family. Simultaneously, a different team prepared the recipient, namely, by debulking a massive plexiform neurofibroma of the face.

RESULTS

Anatomical Observations on Cadavers

The preclinical cadaver study showed that, for a partial face transplant including the lower two-thirds of the face, it was possible to obtain complete revascularization from a single facial pedicle. Investigations of vascular anatomy within the flap, by both transillumination and radiography, showed there to be a sufficient and rich anastomotic network in facial flaps. The facial vessels of the donor must be dissected and harvested at their origin with part of the exter-

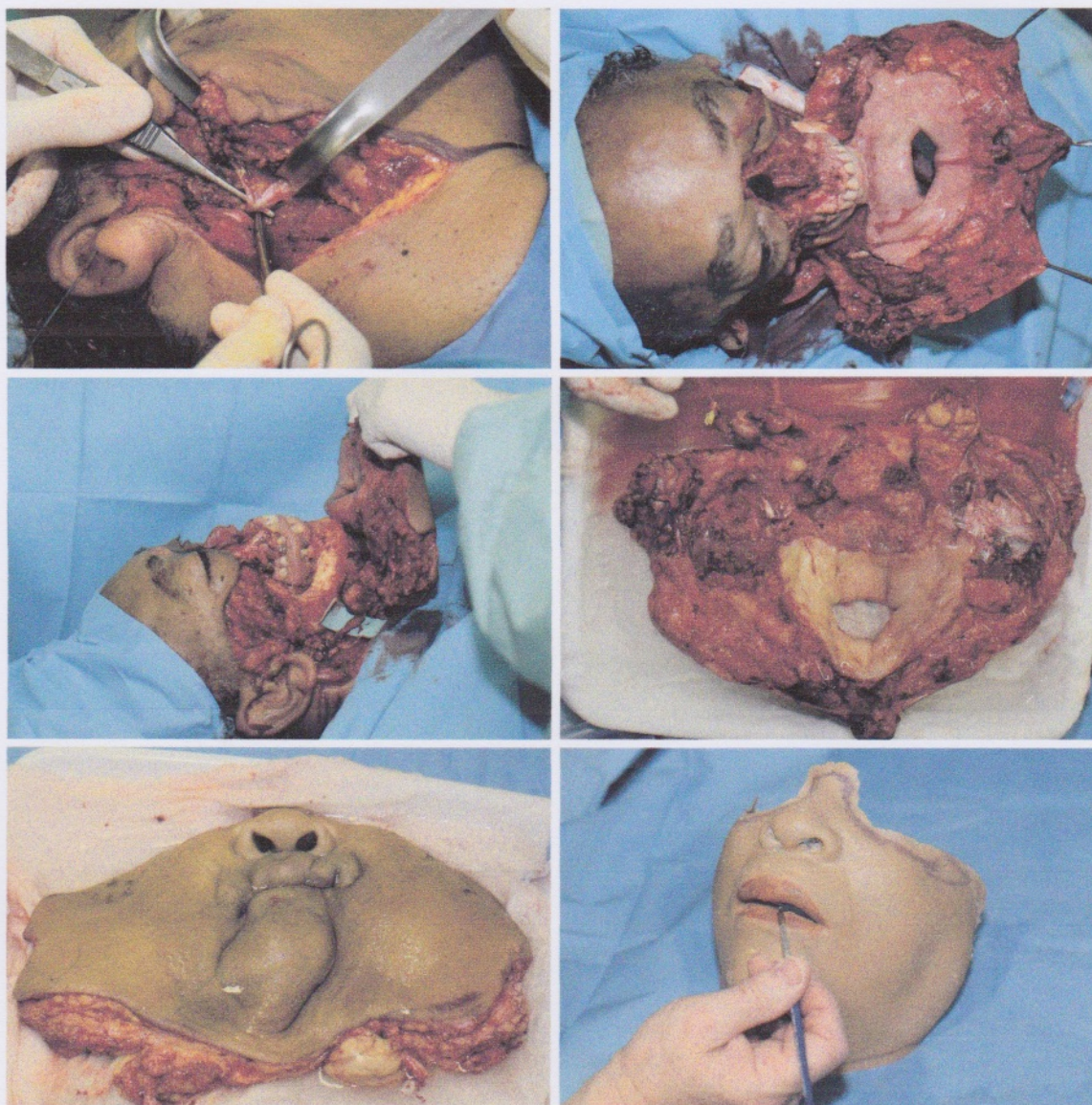


Fig. 4. (Above, left) Exposure of the facial nerve trunk. (Above, right) Subperiosteal dissection. (Center, left) The transplant attached by pedicles to both external carotid arteries and the thyrolinguofacial trunk. (Center, right) Deep view of the harvested nasolabial complex. (Below, left) Superficial view of the harvested nasolabial complex. (Below, right) The resin mask, after coloration (legal restrictions prevent us from showing the mask placed on the face of the donor for the clinical case).

nal carotid artery and internal jugular vein. In this way, we were able to achieve a good match, in terms of size and length, with the recipient during anastomosis.

The facial nerves were easily dissected from their exit from the stylomastoid foramen to their bifurcation. The facial nerve was easily reattached in every case. The dissection plane on the mandible and the upper maxillary bone was subperi-

osteal and allowed easy identification of the infraorbital and mental sensory nerves at their exit from the bone.

All dissections were achieved within 3 hours. During the cadaver study, it became clear that it was possible to remove the full thickness of the soft tissues of the face en bloc to ensure the rapid procurement of a "free facial flap" with minimal tissue damage. The procured flap could then be

adapted to the particular clinical situation of the recipient by removing the extra skin. When soft-tissue facial flaps were "switched" between different bony structures, intermediate facial features not matching the initial characteristics of either donor or recipient were obtained.

Donor Mask Production

Silicone gave excellent results, but mask generation by this method required at least 10 hours. The silicone mask had a more natural texture on palpation but took too long to produce for use in clinical practice. Resin masks gave a less satisfactory result but could be produced in approximately 3 hours. A further 60 minutes was required for coloration of the mask to match the donor's skin. In the *in vivo* study, it was necessary to take postmortem pallor into account.

Clinical Case

Complete revascularization from a single facial pedicle was confirmed during the clinical study: the first end-to-end arterial anastomosis to the left external carotid artery was sufficient for full perioperative revascularization of the flap and the immediate reestablishment of venous flow on both sides. Nevertheless, anastomosis was also carried out on the right side, in case of compression caused by hematoma or inappropriate head rotation. End-to-end anastomoses to the thyrolinguofacial trunks were performed.

Anastomosis of the facial and infraorbital nerves was challenging in this case, because of major incongruence resulting from the neurofibromatosis. Effective nerve anastomoses should follow a strict sequence, from one side to the other, like a gradually closing book. After the first vascular anastomosis, the facial nerve on the same side was sutured, followed by the branches of the trigeminal nerve on the same side. The nasal bones were set and the trigeminal nerve was sutured on the contralateral side. Contralateral vascular anastomoses were then carried out and the facial nerve was sutured. This method ensured effective coaptation between nerves. Truncal anastomosis was performed on the right side in this patient, who already had a paralyzed eyelid, with anastomosis of the lower branch after the bifurcation on the left side. Another difference between the cadaver study and our clinical case was the swelling observed at the end, indicating slight tension in our last nerve suture. Neurologic tests performed 45 days after surgery (clinical testing and electromyograms) detected no nerve re-

growth, despite the presence of spontaneous muscle activity. As expected, voluntary activity was detected on clinical examination 5 months after surgery and was confirmed by electromyography, with activity predominantly on the left side. Sensory improvement was also noted, with the patient requesting local anesthesia for biopsies performed at month 4.

Graft procurement for use in this clinical case took 4 hours. The total clinical procedure lasted 15 hours and involved two senior surgeons, three fellows, and four residents. A two-team approach was used to minimize ischemia time, with one team for the donor and another for the recipient.

The conclusions of our cadaver study concerning the appearance of the face after transplantation were confirmed by our clinical case. Clearly, the patient no longer had his original highly disfigured appearance. However, this patient has an unusual bone structure, largely attributable to neurofibromatosis, and he therefore did not resemble the donor after transplantation. The facial appearance of the recipient improved gradually, together with nerve regrowth, with the development of changes in expression and the appearance of nasolabial folds (Fig. 5). The transplanted parotid glands were entirely functional in the clinical case, with extensive salivary flow on both sides and normal sialography and ultrasound results.

DISCUSSION

Our results show that partial facial composite tissue allotransplantation of the lower two-thirds of the face is technically feasible, with a good cosmetic and functional outcome, in selected clinical cases. The flap used gave reliable vascular⁸⁻¹⁰ and neurologic results and could be obtained rapidly, in a standardized way. The flap contained all the perioral muscles, the facial nerves (VII, V2, and V3), and the major salivary glands.

Unlike others,⁷ we advocate a procurement technique involving removal of the full thickness of soft tissues, as this method limits tissue damage, maximizing the changes of rapid functional recovery after motor nerve anastomosis, even in challenging cases of type 1 neurofibromatosis.¹¹ The flap used here provides the muscles together with the cutaneous attachments essential for facial expression. The preservation of the muscles in a full-thickness transplant is also beneficial in terms of vascularization, because the musculocutaneous perforators are preserved. Potential candidates for face transplantation may present ballistic trauma, severe burns, or genetically induced disfigurement (e.g., xeroderma pigmentosum, neurofibro-

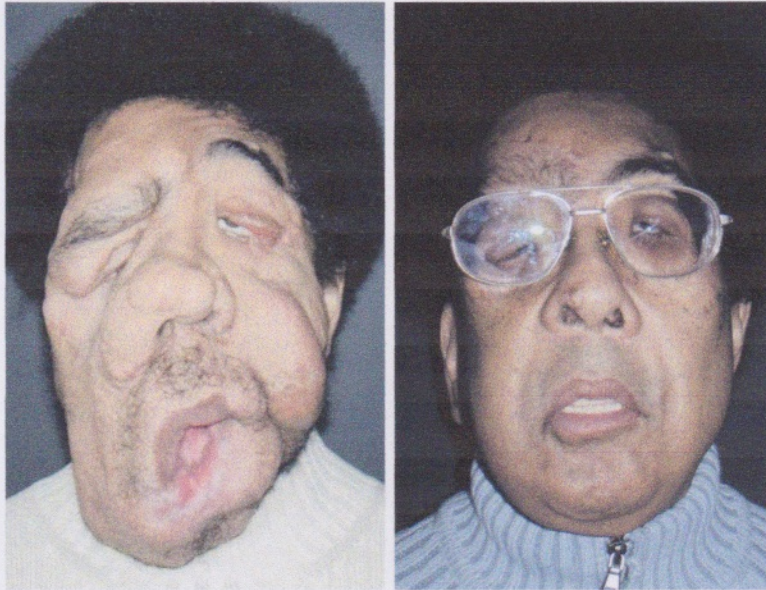

Fig. 5. The clinical result 1 year after face allotransplantation in a 29-year-old patient with a massive plexiform neurofibroma.

matosis), but will probably always be patients with deep tissue damage that has abolished or severely impeded function. We suggest that face transplants should be offered to patients with destruction of the circular muscles of the face (orbicularis oculi or orbicularis oris) in isolation (partial transplant) or combination (total transplant). Otherwise, there is no indication for face transplantation and classic plastic surgery should be used. Furthermore, because much of the dissection is subperiosteal (avascular) and far from the noble structures, this technique ensures that graft procurement can be achieved rapidly.

This need for rapidity may appear strange to plastic surgeons unused to the procurement of grafts for allotransplantation. Indeed, the procurement of a facial graft takes a long time and must be performed first in donors with beating hearts, before removal of the kidney, liver and, obviously, the heart. The donor is hemodynamically unstable so, if it takes too long to obtain the facial graft, the collection of other organs may be jeopardized, endangering the life of potential recipients, which is ethically unacceptable. Ideally, graft procurement should take the same amount of time as preparation of the recipient and fabrication of the prosthetic mask.

Another key element is the restoration of the donor's appearance. This has been straightforward for other types of transplantation, because

organs are internal and hands can be replaced by standard prostheses. It is much more difficult for the face, which must be restored for the benefit of the donor's family, particularly given its potential importance for the mourning process. Our technique, based on the production of a resin mask from an alginate mold, yields rapid (within 4 hours) and acceptable reconstruction. Knowing that the corpse's appearance will be restored helps the family to accept this type of donation and may make this procedure more acceptable to society. The care taken with the restoration procedure has also helped other transplant surgeons to accept this procedure, allowing us to be the first to operate.

The flap, once transplanted, no longer has the physical attributes of the donor's face, because of differences in the underlying bony structures. In addition, it is widely accepted that the expressions of the face, including mimicry in particular, are under cerebral control and are not registered in the tissue. As the face is usually left uncovered and is the principal means of identifying an individual, fears about possible identity problems have been raised in the media. There is no scientific evidence to support the existence of such problems.

We experienced some mismatch in the repair of donor and recipient infraorbital nerves. Neurofibromatosis aside, this may remain a problem, as the infraorbital nerve may branch immediately

after its exit from the infraorbital foramen. As shown by Siemionow et al.,¹² proximal nerve dissection by orbital rim osteotomy may resolve this technical problem.

CONCLUSIONS

Compassion for the candidates for face transplantation is not enough to justify this procedure. Face allotransplantation carries high risks and must still be considered in the framework of clinical research. Several cases are required to evaluate the risk-to-benefit ratio. Immunologic aspects, psychological impact, and long-term functional outcome must also be assessed and the findings published. This work will undoubtedly be extended to the procurement of a total face transplant, but further preclinical work on cadavers is required, as the upper face is very different from the lower face.

Jean-Paul Meningaud, M.D., Ph.D.

Department of Plastic and Aesthetic Surgery
CHU Henri Mondor
51 Avenue du Maréchal de Lattre de Tassigny
Créteil 94010, France
jean-paul.meningaud@hmn.aphp.fr

ACKNOWLEDGMENTS

This work was supported by a grant from the Fondation des Gueules Cassées (a First World War Veterans' foundation) and the Programme Hospitalier de Recherche Clinique (the French Ministry of Health's Program of Clinical Research in Hospitals). The authors thank Danny Faroy, the maxillofacial prosthesis maker of the Department of Plastic and Esthetic Surgery, CHU Henri

Mondor, and the Anatomy Department of Paris V University (René Descartes University) for their support.

REFERENCES

1. Hettiaratchy, S., and Butler, P. E. Face transplantation: Fantasy or the future? *Lancet* 360: 5, 2002.
2. Petit, F., Paraskevas, A., and Lantieri, L. A surgeons' perspective on the ethics of face transplantation. *Am. J. Bioeth.* 4: 14, 2004.
3. Petit, F., Paraskevas, A., Minns, A. B., Lee, W. P., and Lantieri, L. A. Face transplantation: Where do we stand? *Plast. Reconstr. Surg.* 113: 1429, 2004.
4. Toure, G., Meningaud, J. P., Bertrand, J. C., and Hervé, C. Facial transplantation: A comprehensive review of the literature. *J. Oral Maxillofac. Surg.* 64: 789, 2006.
5. Devauchelle, B., Badet, L., Lengele, B., et al. First human face allograft: Early report. *Lancet* 368: 203, 2006.
6. Dubernard, J. M., Lengele, B., Morelon, E., et al. Outcomes 18 months after the first human partial face transplantation. *N. Engl. J. Med.* 357: 2451, 2007.
7. Morris, P., Bradley, A., Doyal, L., et al. Face transplantation: A review of the technical, immunological, psychological and clinical issues with recommendations for good practice. *Transplantation* 27: 709, 2007.
8. Wilhelmi, B. J., Kang, R. H., Movassaghi, K., Ganchi, P. A., and Lee, W. P. First successful replantation of face and scalp with single-artery repair: Model for face and scalp transplantation. *Ann. Plast. Surg.* 50: 535, 2003.
9. Nakajima, H., Imanishi, N., and Aiso, S. Facial artery in the upper lip and nose: Anatomy and a clinical application. *Plast. Reconstr. Surg.* 109: 855, 2002.
10. Pinar, Y. A., Bilge, O., and Govsa, F. Anatomic study of the blood supply of perioral region. *Clin. Anat.* 18: 330, 2005.
11. Wolkenstein, P., Zeller, J., Revuz, J., Ecosse, E., and Leplège, A. Quality-of-life impairment in neurofibromatosis type 1: A cross-sectional study of 128 cases. *Arch. Dermatol.* 137: 1421, 2001.
12. Siemionow, M., Papav, F., Kulachi, Y., et al. Coronal-posterior approach for face/scalp harvesting in preparation for face transplantation. *J. Reconstr. Microsurg.* 22: 399, 2006.