FACE TRANSPLANTATION SURGICAL OPTIONS AND OPEN PROBLEMS IN CADAVERIC MODELS: A REVIEW ARTICLE

Alessio Baccarani, M.D., F.A.C.S.,[1*] Keith E. Follmar, M.D.,[2] Detlev Erdmann, M.D., Ph.D.,[3] and L. Scott Levin, M.D., F.A.C.S.[4]

Being first conceptualized in 2005–2006, total face transplantation is now a clinical reconstructive option in the treatment of patients with acquired facial deformity. The authors propose a review on the status of total face transplantation based on their clinical experience in dealing with traditional microsurgical head and neck reconstructions and on the basis of their published pre-clinical research investigating technical aspects of the facial allotransplantation procedure in cadaveric models. The authors first discuss the harvesting options and propose two facial flaps which address different reconstructive needs. Next, the concept of donor–recipient anatomical compatibility is introduced, and the possible outcome of the chimeric face is studied, following the insetting of a fasciocutaneous facial allograft. Finally, the authors address the major technical challenges associated with transplanting the most complex osteomyocutaneous allograft. Significant improvement has been made in the field of vascularized composite tissue allotransplantation over the last 5–6 years. The results of the 13 face transplants performed worldwide are encouraging both functionally and aesthetically, when compared with traditional reconstructive procedures. ©2013 Wiley Periodicals, Inc. Microsurgery 33:239–246, 2013.

Acquired facial deformity may result from trauma, burns, infection,[1] and tumor resection. The reconstruction of the resulting defect remains a substantial challenge. Over the past several years, face transplantation has begun to emerge as a valuable option in the treatment of patients with extensive facial disfigurement.[2–4] Conventional reconstructive procedures provide satisfactory outcomes in most patients in need of facial reconstruction. However, the final outcome remains unsatisfactory in a number of patients, both from a functional and aesthetic standpoints.[5] The principal limitation of conventional procedures is that the tissues being used for reconstruction are inherently different than those they are replacing.[5,6] Face transplantation potentially solves this problem by allowing the surgeon to place an entire donor face onto a recipient patient, *en-block*. Despite this advantage, face transplantation has significant challenges that have limited its application.

The side effects associated with an immunosuppressive regimen that are necessary to prevent rejection remain substantial.[7] While many scientists are actively working to better understand the science of allograft rejection, the possibility of inducing tolerance to composite tissue allografts[8,9] and the interference of ischemia time on rejection[10,11] remains little more than a theoretical goal.

Furthermore, ethical and psychological considerations are associated with placing one person's face onto another's body.[3,4]

A third challenge associated with face transplantation is defining and solving all the technical aspects of harvesting and implanting a face. The flap would have to include one or more vascular pedicles. The anatomy of the face has been well known for many years, but the facial angiosomes were first described in 2000.[12] The successful cases of autologous face replantation in the literature[13–15] provided clinical confirmation that the technical challenge of face transplantation could be overcome, and that the face could be revascularized by one or more vascular pedicles. This anatomical knowledge, together with the successes of face replantation, has led us to the conceptualization of a bipedicled full facial flap based on the external carotid arteries.[16–18]

The morphological and aesthetic outcome of a face transplantation is of great relevance to the surgeon in answering the technical question of whether a given donor face is compatible with the recipient's needs.[19,20] Just as any transplant surgeon must consider the donor's blood type, human leucocytes antigen (HLA) typing, and cytomegalovirus (CMV) status, a face transplant surgeon must also consider the donor's skin color, texture, soft-tissue features, and anthropometric measurements. The question of how the chimeric face of a transplant recipient would appear when compared to his or her native face and to that of the donor is of great interest and importance for a number of reasons.[19] A result that is perceived to look like "someone else," could be psychologically challenging. Most anatomical studies in the literature have focused exclusively on the possibility of composite cutaneous face transplantation, in which a soft tissue only flap is harvested in the sub-galeal,

[1]Division of Plastic Surgery, Modena University Hospital, Modena, Italy
[2]Division of Plastic Surgery, Johns Hopkins University, Baltimore, MD
[3]Division of Plastic Surgery, Duke University Medical Center, Durham, NC
[4]Department of Orthopaedic Surgery, Hospital of the University of Pennsylvania, Philadelphia, PA

This review was presented at the 10th Congress of the International Society for Experimental Microsurgery (ISEM), held on October 29-November 1, 2010 in Sao Paulo, Brazil and received the "Robert Zhong Award".

*Correspondence to: Alessio Baccarani, MD, FACS, Division of Plastic Surgery, Modena University Hospital, Largo del Pozzo 71, 41100 Modena, Italy. E-mail: alessio.baccarani@unimore.it

Received 26 July 2012; Accepted 28 November 2012
Published online 26 February 2013 in Wiley Online Library (wileyonlinelibrary.com). DOI 10.1002/micr.22083

sub-superficial muscular aponeurotic system (sub-SMAS), sub-platysmal plane. Focus on this type of flap may be justified because many conceivable defects amenable to facial transplantation involve only soft tissues. However, there is a subset of massive facial defects that include extensive involvement of the facial skeleton.[21] Although these defects are more rare, they also are the most extensive by their definition. In accordance with the American Society for Reconstructive Microsurgery (ASRM) position that face transplantation is only potentially indicated for defects that are not reconstructable by conventional techniques,[22] where bony as well as soft tissue replacement is needed.

In the current article, the authors propose a comprehensive review of the findings derived from a set of published studies carried out on cadaveric models to address the issues described above. These data will be then discussed in the perspective of the recent findings from the clinical application.

APPROACHES TO TOTAL FACE HARVEST—SURGICAL TECHNIQUES IN CADAVERIC MODELS

Using cadaver dissections we have hypothesized two techniques demonstrating what might be included in the harvest.[16,17] In the first one, the skin and soft tissue of the face were harvested by dissecting in a subgaleal, sub-SMAS, subplatysmal plane. This is similar to the technique described by Siemionow et al.[19] in the same year. In the second one, the entire soft tissue and the bony structure of the midface was harvested as an osteocutaneous composite flap by dissecting in a subperiosteal plane and harvesting the bones of the midface after performing a Le Fort III osteotomy.[23]

Sub-SMAS Harvest

Surgery began in the neck with bilateral isolation of the vascular pedicles (external carotid artery, external jugular vein, and facial vein). Next orifices were incised and the flap was then dissected from the vertex downward in the sub-galeal, sub-SMAS, and sub-platysmal plane. This flap included supraorbital, infraorbital, and mental sensory nerves bilaterally (Figs. 1a and 1b).

Subperiosteal Le Fort III Harvest

A similar approach was taken in the neck, with bilateral Schobinger incisions and careful skeletonization of the external carotid arteries, of the external jugular veins, and of the facial veins. The dissection from the vertex downward was carried out in the subperiosteal plane.

Once sufficient exposure was obtained, a Le Fort III osteotomy was then performed by creating fractures through the nasal bridge, the lateral orbital walls, and the zygomatic arches. The pterygoid plates were fractured via an intraoral approach. Vascular dissection of the external carotid system was extended to the pterygomandibular fossa to include the internal maxillary artery. This complex osteomyocutaneous flap included the facial nerve bilaterally in addition to all sensitive nerves (Figs. 2a and 2b).

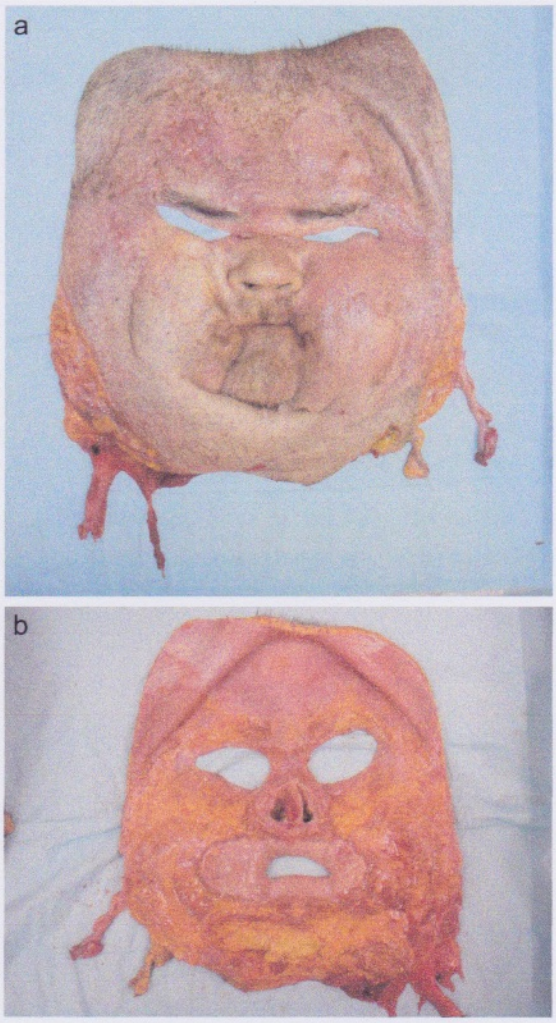

*Figure 1. Harvested sub-SMAS facial allograft (**a**,**b**). [Color figure can be viewed in the online issue, which is available at wileyonline library.com.]*

ASSESSING OUTCOME AND DEFINING DONOR–RECIPIENT ANATOMICAL COMPATIBILITY FOR THE SUB-SMAS—SUB-PLATISMAL FACIAL HARVEST IN CADAVERIC MODELS

The donor–recipient anatomical compatibility was investigated by performing mock cadaveric transplantations. In our experimental setting, four heads obtained from fresh human cadavers without any specific regard to

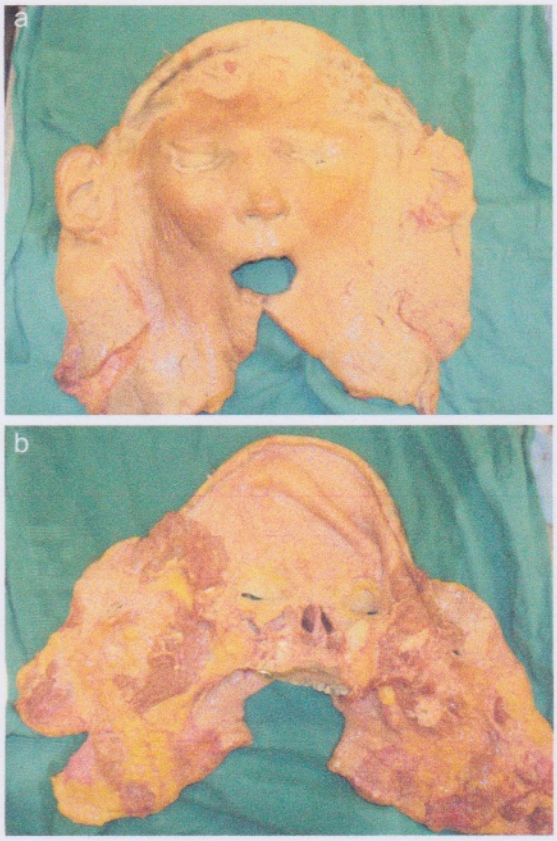

*Figure 2. Harvested sub-periosteal Le-Fort III facial allograft (**a**,**b**). [Color figure can be viewed in the online issue, which is available at wileyonlinelibrary.com.]*

size, skin color, or anthropometric measurements[20] were labeled, photographed, scanned by CT radiography, and analyzed using several standard anthropometric measurements. Each face was then harvested from its native cranium in a subgaleal, sub-SMAS, subplatysmal plane, and was inset onto two of the three other crania to create a total of eight chimeric faces. The insetting was performed according to a predetermined, standardized procedure. Each of these chimers was again photographed, scanned by CT radiography, and anthropometrically analyzed.

To assess whether the chimers were anthropometrically more similar to the donors or the recipient faces, each chimer's anthropometric measurements (craniofacial height, intracanthal width, skull base width, and middle third depth) were compared with those of the donors and with those of the recipients. The average absolute values of the differences between chimers and donors, and between chimers and recipients, were calculated for each of the four measurements. As a result, the chimers were significantly more similar to the recipient faces than to the donor ones with respect to skull base width ($P = 0.025$, simple t-test). They were also more similar to the recipient faces with respect to craniofacial height, although this difference was not significant ($P > 0.10$). They were approximately equally similar to the donor and recipient with respect to intracanthal width and middle third depth.

Every reader is able to draw his or her own conclusions as to how each face appears compared to the native donor and recipient faces (shown along the main diagonal—Table 1). It is the authors' contention that, when one ignores skin color, the chimeric faces more closely resemble the recipient's than the donor's. This is most easily observed by looking at the CT reconstructions, where skin color differences are eliminated. There are clearly greater resemblances in the rows than there are in the column (Table 1).

ASSESSING OUTCOME AND DEFINING THE INSETTING OF THE SUB-PERIOSTEAL—LE FORT III FACIAL HARVEST IN CADAVERIC MODELS

A third report from our group described a cadaver experiment on the feasibility and outcome of a mock osteocutaneous Le Fort III face transplantation in a cadaver model, and discusses the various challenges associated with this type of osteocutaneous facial allo-transplantation.[21]

In this experimental setting, two fresh human cadaver heads quite similar with respect to size were obtained. One of the heads was chosen to be the donor and the other was chosen to be the recipient. The face was dissected from each of the two heads according to the authors' technique,[17] by elevating in a subperiosteal plane and performing a Le Fort III osteotomy. The harvested donor face was placed upon the recipient cranium. The details and sequencing of the insetting procedure with respect to (1) bony reduction, (2) bony fixation by means of craniomaxillofacial titanium internal fixation plates, (3) soft tissue muscular approximation, and (4) skin and mucosal closure were defined. The procedure was documented by a series of photographs, and the chimer face was imaged by computer tomography to allow visualization of the bony fixation (Figs. 3a–3c).

FACIAL FLAPS INDICATIONS AND TECHNICAL ASPECTS

The sub-SMAS flap was harvested in the most superficial plane possible, without compromising vascular (specifically venous) integrity.[10] The sub-priosteal Le-Fort III flap was harvested in the deepest plane of the face, and is the most complete facial harvest that can be performed. The exact details of either flap can be modified in order to meet the recipient's specific needs.

Table 1. Volumetric CT Radiographs of Native Faces and Cranium-Face Chimera Complexes

	Face a	Face b	Face c	Face d
Cranium A				Not Assessed
Cranium B			Not Assessed	
Cranium C		Not Assessed		
Cranium D	Not Assessed			

The sub-SMAS flap was designed with the intent of meeting the reconstructive needs of a wide soft-tissue defect, as is sometimes encountered in severely burned patients. It is a non-innervated flap and is designed for soft tissue coverage only. Sensory recovery may be achieved with this flap following neurorrhaphy of the appropriate nerves. According to the aforementioned Gillies' principle of replacing "like with like," this may be the most appropriate tissue for total facial reconstruction in terms of texture and contour. Prior to the transfer, the recipient face would have to undergo preparation, including serial debridements. Facial animation would rely at least primarily on the integrity of the recipient's underlying musculature. Insetting of the flap would also include attachment of the flap at each of the eight suspensory ligaments.[21] The subperiosteal flap was designed to meet the reconstructive needs of a patient with more extensive injuries to the face. Such a patient would have damage to the skin, bone, and muscles. Sensory innervation might be achieved through neurorraphy of the appropriate nerves if the recipient nerves are located and found to be intact. Neurorraphy of the infraorbital-maxillary nerve under the Le Fort III segment to the remaining recipient stump would be technically very difficult. Additionally, the principle masticatory muscles (temporalis and masseter) are included in this flap, and may be connected to the remaining stumps of the recipient's muscles, or directly to the recipient's mandible. These muscles may become functional in providing some masticatory function possibly through neurorraphy to the masseteric branch of the trigeminal nerve, or by coaptation to the recipient's residual functional muscles. These muscles may also allow for more complete vascularization due to their role in connecting three of the facial angiosomes (superficial temporal, facial, and posterior auricular).[10] This flap was designed to include eyelids, ears, lips, and the entire osseous Le Fort III segment. In practice, this flap would be harvested and then customized prior to insetting, to meet the recipient's needs.

Latex injections of the external carotid artery appeared to supply the vast majority of the Le Fort III osseous segment without any supply from the internal

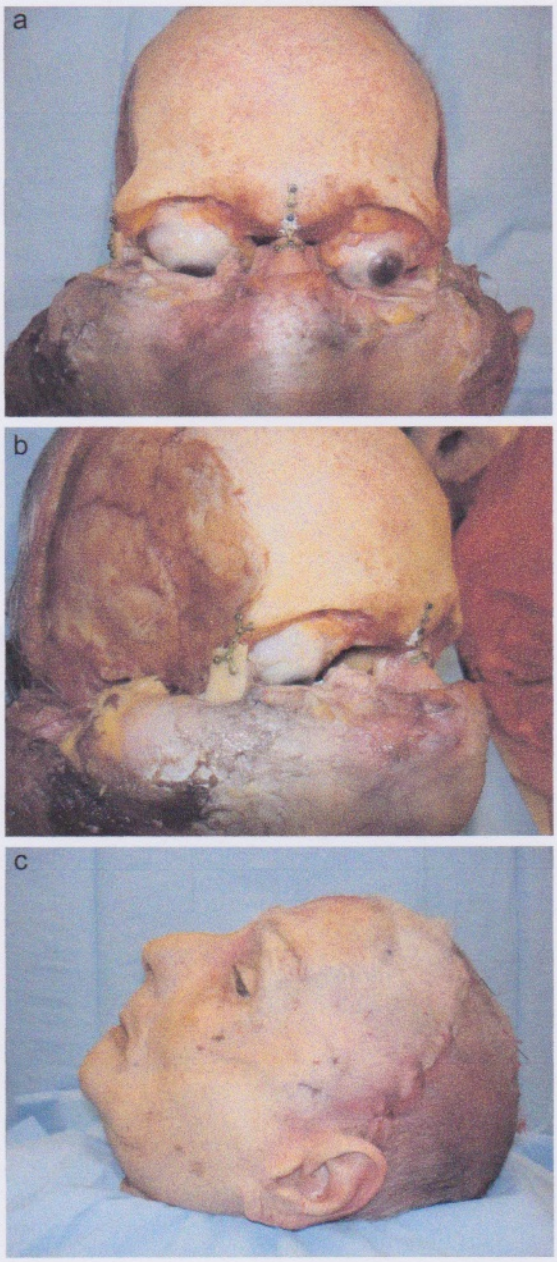

*Figure 3. Sub-periosteal Le-Fort III flap is inset into the recipient cranium. Traditional skeletal fixation is performed with miniplates (**a**,**b**). Transplanted specimen in lateral view (**c**). [Color figure can be viewed in the online issue, which is available at wileyonlinelibrary.com.]*

carotid system. Still, even if a small portion of the bony structures remain devascularized, they should provide some mechanical strength and a matrix for cellular substitution, as typically occurs in autologous nonvascularized bone grafting.[24] The latex perfusion confirmed previous reports[25–27] showing that, at least, the superior alveolar ridge and the anterior portion of the Le Fort III segment can be vascularized by the gingival periosteal system. Although injection with latex prior to dissecting is the standard technique used in assessing vascular anatomy,[28–30] it does have substantial limitations. Both of these dissections are challenging, but not beyond the ability of an experienced reconstructive microsurgeon. Harvest of the sub-SMAS flap is somewhat more challenging in the upper and midface. Overall, it is the less time-consuming of the two harvest techniques, since osteotomies are not required. Harvest of the subperiosteal Le Fort III flap proceeded more quickly through the area of the upper and midface where all structures were inherently preserved due to their supraperiosteal location. The vascular dissection into the pterygomandibular fossa was challenging, but all structures can be preserved.

In addition to the technical challenges, harvesting an osteocutaneous Le Fort III flap may present a greater immunological challenge compared to the sub-SMAS flap. The presence of immunocompetent cells and hematopoetic stem cells in the preauricular lymph nodes and the bone allograft poses the potential risk of graft-versus-host disease. These cells may alternatively provide the potential benefit of immunological chimerism. The most likely outcome, however, would be repopulation of these structures by the recipient's native stem cells and leukocytes.[31]

IDENTITY ISSUES

Attempting to scientifically assess whether the chimeras as a group more closely resemble the donors or the recipients is a somewhat artificial exercise. The cadaveric face transplantations carried out in our studies were performed without selecting for skin color, face size, soft tissue feature, or any other factors which a face transplant surgeon would clearly attempt to control. Instead than analyzing the outcomes of these randomly assembled chimeras as a group, it is more relevant to ask the following question. Is it possible to obtain a morphologically and aesthetically acceptable result that resembles the recipient's native face reasonably well? Chimer Cd (Table 1) illustrates that such a result can be obtained when the donor face is appropriate for the recipient's native cranium.[20]

The success of this particular transplantation has led us to hypothesize a list of parameters to define compatibility between a donor and recipient for face transplantation. The patient's skin color and texture must be reasonably well matched to prevent the recipient's face from having a chimeric appearance. Significant difference in skin color, as in a cross-racial transplant, or significant

differences in skin texture, perhaps due to a large age discrepancy, would not be practicable. Modest differences, however, would be tolerable, and could be mitigated through the use of traditional dermatologic techniques.

Anthropometric differences in the range of 1–4% (with respect to craniofacial height) are not problematic, as was demonstrated by the first set of chimers. The second set of chimers demonstrated that differences in the range of 9–14% are technically unfeasible and yield unacceptable results. The cut-off that should be used in determining the acceptability of a donor for a given recipient is somewhere between these two ranges. Furthermore, because skin stretches more efficiently than it can be surgically tailored by resection, the acceptable size mismatch may be somewhat greater when a small face is being inset onto a larger cranium. This conclusion became clear during the course of the insettings.

Soft tissue features comprise a fourth class of parameters that must be considered when attempting to match a donor face with a potential recipient. Features that should be considered include the cartilaginous nose, the lips, the eye brows, and the cheeks. In order for the chimeric face to closely resemble the recipient's native face, all of these features must be grossly similar. The nose is the most distinctive of these features, as is seen in chimers Ba and Ca. The importance of these features is lessened, however, because they can be customized, either at the time of insetting or as a secondary procedure.

Gender is another parameter that should be considered, but is not of critical importance. The gender-specific pattern of facial hair would pose some problems, but these may be lessened over time as the hormonal milieu of the recipient is allowed to take its effects on the allograft.

Anthropometric measurements have shown that the chimers are more similar to the recipient faces than to the donor ones with respect to some variables, but of approximately equal similarity with respect to others.[20] This finding is consistent with our conclusion that an appropriately matched transplanted face can give an adequate match to the recipient's native face. It is somewhat dubious, however, to draw conclusions based on anthropometric measurements, as they have been shown to be poor predictors of subjective facial resemblance.[12] More rigorous studies with larger sample sizes would allow specific compatibility ranges for each anthropometric measure to be defined.

OSTEOMYOCUTANEOUS FACE TRANSPLANTATION CHALLENGES

The experience gained in the course of this and other cadaver dissection studies and in performing craniofacial surgery for both congenital deformities and traumatic injuries helped us identify what we believe to be the principal challenges of, and issues raised by, ostemyocutaneous face transplantation. Multiple areas of technical challenge associated with osteocutaneous face transplantation are introduced and discussed below in anticipation of future further analysis.

Customizing the Bony Segment

The defect being repaired in this experiment was unrealistic in that it was a post-face harvest defect. Since the two heads were of similar dimensions and the two faces were harvested according to the same harvest protocol, it was not surprising that the donor face fit into its recipient defect site with minimal customization.[21] In reality, the recipient defect that necessitates an osteocutaneous face transplantation procedure would by irregular and asymmetric. Regardless of the defect's etiology, the bony defect would have to be substantial to necessitate such a procedure. Designing the bony segment of the allograft to fit such a defect would be a challenge. This might best be accomplished by determining whether each half of the defect (hemi-face) most nearly matches a Le Fort I, II, or III hemi-segment.[17] One would have to carefully consider whether any portion of the recipient's maxillofacial skeleton should be sacrificed for the purpose of inset fitting, as might be done if, for example, a portion of the recipient's maxillary arch remained intact. The allograft could then be harvested accordingly and customized in situ at the time of insetting. Clearly, the donor and recipient would have to have similar skeletal dimensions to facilitate a reasonable match. Once such a match is made, the allograft could be inset by traditional internal fixation. Smaller residual bony defects might be filled with non-vascularized bone grafts (autologous or cadaveric), or with tissue engineered products that facilitate osteogenesis.[21]

Sensory and Motor Innervation

Sensory innervation of the face is provided primarily by four bilateral nerves—the great auricular, supraorbital, infraorbital, and mental nerves. In the cases of the great auricular, supraorbital, and infraorbital nerves, some sensory function would be gained by neurorraphy of the donor and recipient stumps. While straightforward in theory, this might be impossible in the clinical scenario, since any injury that is sufficient to necessitate a face transplant is also likely to cause significant damage to these nerves. The infraorbital nerves are unique in that they are located within the bony structures that would potentially be transplanted. The maxillary nerve, from which the infraorbital nerve derives, could be isolated more proximally at the inferior orbital fissure, which is in continuity posteriorly with the pterygopalatine fossa. The donor and recipient stumps of this nerve could potentially be coapted under the osseous segment. Supraorbitary to infraorbitary nerve transfer has also been described as a

technical option to restore midface sensation when recipient infraorbitary nerves are not available.[32] Regardless of the specific neurorraphies performed, sensory innervation of the transplanted face would likely be incomplete and variable.[21]

The overall outlook for innervation of the facial muscles would be similar, again depending largely on the extent of injury—specifically the level of injury to the facial nerve. Injury requiring coaptation of the facial nerve distal to the stylomastoid foramen but proximal to demonstrable branching would be expected to result in significant cross-innervation and resultant synkinesis. If, however, the proximal branch pattern of the facial nerve has been preserved to some extent, neurorraphy of selected branches could be performed. Experience with facial reanimation surgery has demonstrated that even a minimally, yet selectively innervated face that allows a social smile can be of great value to the patient. Facial reanimation with autologous free muscle transfer would remain a viable option as a secondary procedure. Because of its depth beneath the masseter muscle, the motor branch to the massester muscle (cranial nerve V) would likely be preserved and would provide a suitable donor source of motor input. Free muscle transfer utilizing the masseteric nerve was demonstrated as a highly effective method for facial reanimation among several facial paralysis centers, including the authors'.[33,34]

Extra-Ocular Movements

A facial defect requiring alloplastic reconstruction to the level of the inferior orbital floor may also include the orbit and thereby require enucleation. However, in the event that the orbit and the optic nerve remain intact, the orbital floor and lateral orbital wall could be transplanted as part of the facial allograft and the donor lateral and inferior rectus muscles could be coapted to their remaining counterparts in the recipient. In this manner, reasonable extraocular function could be obtained. It is likely, however, that secondary muscle balancing be necessary.[21]

Dentition

Any facial defect requiring bony reconstruction would likely include at least some of the maxilla with its associated dentition. Additionally, part of the mandible and its associated dentition may be harvested with the allograft if there was a need for interpositional repair of a segmental mandibular defect.[21] The most obvious implication of dentition in the allograft is that the dentition of any potential donor would need to be evaluated as a donation criterion. Patients with poor dentition would make poor donors, even if the dentition was removed at the time of harvest, due to the potential for sepsis as well as local infection in the setting of immunosuppression. For the same reason, the dentition of the recipient must also be evaluated and treated, as would normally be done prior to conventional solid organ transplantation.[21]

Mastication

There are two crucial aspects to mastication. First, the mandible must be moved by innervated muscles of mastication and, next, the viability of the temporo-mandibular joint (TMJ) must be maintained. If the mandible and all muscles of mastication were left intact, mastication would not pose a significant clinical challenge, but it is unlikely that an osteocutaneous allograft be required in any such case. If the proximal stumps of temporalis and/or masseter were left intact and innervated, they could be coapted to the corresponding musculature of the donor allograft.[21] More challenging would be innervation of transplanted muscles of mastication, which would be subject to the limitations and challenges of reinnervation previously discussed.

Vascular Considerations

Anatomical studies, clinical experience with face and scalp replantation, and orthognathic surgery have provided evidence that the face can be well vascularized based on the external carotid system, and that an osseous segment can be included. Our own anatomical study concluded that the only portions of the Le Fort III osseous segment that may have marginal blood supply are the posterior portions of the sphenoid and ethmoid bones and the zygomatic arches.[16,17] Even if a small portion of these bony structures remains devascularized, they should nevertheless provide some mechanical strength and a matrix for cellular substitution, as typically occurs in autologous nonvascularized bone grafting.[16,17,21]

Vascular perfusion of the transplanted bony segment would at least be theoretically augmented by dissection in the subperiosteal rather than the supraperiosteal plane. The vascular plexus found in the periosteum should supplement the primary axial blood supply to the osseous segment.

If there was a need to include a mandibular segment in the flap (as discussed above) this segment would be well vascularized based on its gingivo-periosteal blood supply,[17] just as it is in the routine clinical scenario of bilateral mandibular fractures, where the periosteum sometimes provides the interpositional segment's blood supply following the fracture.

CONCLUSIONS

Two distinct techniques for face harvesting, each based on two vascular pedicles containing three vessels, were defined. Their technical feasibility was demonstrated by the studies discussed in this review and, more recently, face transplantation was performed clinically.[35–37] A set of basic

parameters to evaluate the donor/recipient compatibility has also been defined. Many technical challenges are present with performing the most complex osteomyocutaneous allotransplantation. Nonetheless, this procedure has began to demonstrate to provide a real benefit over traditional autologous[6] flap reconstruction.

REFERENCES

1. Tempest MN. Cancrum oris. Br J Surg 1966;53:949–969.
2. Petit F, Paraskevas A, Minns AB, Lee WP, Lantieri LA. Face transplantation: Where do we stand? Plast Reconstr Surg 2004;113:1429–1433.
3. Clark PA. Face transplantation: A medical perspective. Med Sci Monit 2005;11:RA1–RA6.
4. Siemionow M. Until they have faces: The ethics of facial allograft transplantation. Transplantation 2005;80:1374–1375.
5. Siemionow M, Unal S, Agaoglu G, Sari A. A cadaver study in preparation for facial allograft transplantation in humans. I. What are alternative sources for total facial defect coverage? Plast Reconstr Surg 2006;117:864–872; discussion 873–875.
6. Baccarani A, Follmar KE, De Santis G, Adani R, Pinelli M, Innocenti M, Baumeister S, Von Gregory H, German G, Erdmann D, Levin LS. Free vascularized tissue transfer to preserve upper extremity amputation levels. Plast Reconstr Surg 2007;120:971–981.
7. Barker JH, Francois CG, Frank JM, Maldonado C. Composite tissue allotransplantation. Transplantation 2002;73:832–835.
8. Siemionow MZ, Demir Y, Sari A, Klimczak A. Facial tissue allograft transplantation. Transpl Proc 2005;37:201–204.
9. Prabhune KA, Gorantla VS, Perez-Abadia G, Francois GC, Vossen M, Laurentinperez LA, Breidenbach WC, Wang GC, Anderson GL, Barker JH, Maldonado C. Composite tissue allotransplantation in chimeric hosts. II. A clinically relevant protocol to induce tolerance in a rat model. Transplantation 2003;76:1548–1555.
10. Ong YS, Zhang Y, Baccarani A, Follmar KE, Messmer C, Klitzmann B, Erdmann D, Levin LS. Effect of ischaemia time on acute rejection of composite tissue allotransplantation in a rat model. J Reconstr Microsurg 2007;23:448.
11. Pradka SP, Ong YS, Zhang Y, Davis SJ, Baccarani A, Messmer T, Fields TA, Erdmann D, Klitzmann B, Levin LS. Increased signs of acute rejection with ischemic time in a rat musculocutaneous allotransplant model. Transpl Proc 2009;41:531–536.
12. Houseman ND, Taylor I, Pan W. The angiosomes of the head and neck: Anatomic study and clinical applications. Plast Reconstr Surg 2000;105:2287–2313.
13. Wilhelmi BJ, Kang RH, Movassaghi K, Ganchi PA, Lee WP. First successful replantation of face and scalp with single-artery repair: Model for face and scalp transplantation. Ann Plast Surg 2003;50:535–540.
14. Thomas A, Obed V, Murarka A, Malhotra G. Total face and scalp replantation. Plast Reconstr Surg 1998;102:2085–2087.
15. Siemionow M, Agaoglu G. Allotransplantation of the face: How close are we? Clin Plast Surg 2005;32:401–409.
16. Baccarani A, Follmar KE, Marcus JR, Erdmann D, Levin LS. Technical aspects of face transplantation: Two options for total face harvesting. Plast Reconstr Surg 2006;118:33–34.
17. Baccarani A, Follmar KE, Baumeister SP, Marcus JR, Erdmann D, Levin SL. Technical and anatomical considerations of face harvest in face transplantation. Ann Plast Surg 2006;57:483–488.
18. Messmer C, Baccarani A, Follmar KE, Mukundan S, Levin LS, Marcus JR, Erdmann D. Facial allograft transplantation: Fiction or reality? Surgical techniques in a fresh human cadaver model. Chirurg 2008;79:340–345.
19. Siemionow M, Agaoglu G, Unal S. A cadaver study in preparation for facial allograft transplantation in humans. II. Mock facial transplantation. Plast Reconstr Surg 2006;117:876–885; discussion 886–888.
20. Baccarani A, Follmar KE, Das RR, Mukundan S, Marcus JR, Levin SL, Erdmann D. A pilot study in Sub-SMAS face transplantation: defining donor compatibility and assessing outcomes in a cadaver model. Plast Reconstr Surg 2007;118:121–129.
21. Follmar KE, Baccarani A, Das RR, Mukundan S, Levin LS, Erdmann D, Marcus JR. Osteocutaneous face transplantation. J Plast Reconstr Aesth Surg 2008;61:518–524.
22. The United States position: Position paper of the American Society for Reconstructive Microsurgery on Facial Transplantation. South Med J 2006;99:430.
23. Shetye PR, Kapadia H, Grayson BH, McCarty JG. A 10-year study of skeletal stability and growth of the midface following Le Fort-III advancement in syndromic craniosynostosis. Plast Rec Surg 2010; 126:973–981.
24. Furnas DW. The retaining ligaments of the cheek. Plast Reconstr Surg 1989;83:11–16.
25. Delloye C. How to improve the incorporation of massive allografts? Chir Organi Mov 2003;88:335–343.
26. Siebert JW, Angrigiani C, McCarthy JG, Longaker MT. Blood supply of the Le Fort I maxillary segment: An anatomic study. Plast Reconstr Surg 1997;100:843–851.
27. Dodson TB, Bays RA, Neuenschwander MC. Maxillary perfusion during Le Fort I osteotomy after ligation of the descending palatine artery. J Oral Maxillofac Surg 1997;55:51–55.
28. Rucker M, Binger T, Deltcheva K, Menger MD. Reduction of midfacial periosteal perfusion failure by subperiosteal versus supraperiosteal dissection. J Oral Maxillofac Surg 2005;63:87–92.
29. Zenn MR, Heitmann C. Extended TRAM flap: Feasibility study on fresh human cadavers. Ann Plast Surg 2003;50:256–262.
30. Hennerbichler A, Etzer C, Gruber S, Brenner E, Pepp C, Gaber O. Lateral arm flap: Analysis of its anatomy and modification using a vascularized fragment of the distal humerus. Clin Anat 2003;16:204–214.
31. Mathes DW, Randolph MA, Bourget JL, Nielsen GP, Ferrera VR, Arn JS, Sachs DH, Lee WP. Recipient bone marrow engraftment in donor tissue after long-term tolerance to a composite tissue allograft. Transplantation 2002;73:1880–1885.
32. Rodriguez-Lorenzo A, Audolfsson T, Rozen S, Kildal M, Nowinski D. Supraorbitary to infraorbitary nerve transfer for restoration of midface sensation in face transplantation: Cadaver feasibility study. Microsurgery 2012;32:309–313.
33. Bianchi B, Copelli C, Ferrari S, Ferri A, Sesenna E. Successful salvage surgery after treatment failures with cross graft and free muscle transplant in facial reanimation. J Craniomaxillofac Surg 2012;40: 185–189.
34. Adani R, Baccarani A, Guidi E, Tarallo L. Schwannomas of the upper extremity: Diagnosis and treatment. Chir Org Mov 2008;92:85–88.
35. Pomahac B, Pribaz J, Eriksson E, Annino D, Caterson S, Sampson C, Chun Y, Orgill D, Nowinski D, Tullius SG. Restoration of facial form and function after severe disfigurement from burn injury by a composite facial allograft. Am J Transplant 2011;11: 386–393.
36. Pomahac B, Aflaki B. Composite tissue transplantation: A new era in transplantation surgery. E-plast 2010;10:480–482.
37. Siemionow M, Papay F, Alam D. Bernard S, Djohan R, Gordon C, Hendrickson M, Lohman R, Coffman K, Kodish E, Paradis C, Avery R, Fung J. Near-total human face transplantation for a severely disfigured patient in the USA. Lancet 2009;374:203–209.