

# First human face allograft: early report

Bernard Devauchelle, Lionel Badet, Benoit Lengelé, Emmanuel Morelon, Sylvie Testelin, Mauricette Michallet, Cédric D'Hauthuille, Jean-Michel Dubernard

## Summary

**Background** Extended soft tissue defects of the face are difficult to reconstruct, and autologous tissue transfers usually lead to poor cosmetic and functional outcomes. We judged that composite tissue transplantation could be valuable in facial reconstructive surgery.

**Methods** We transplanted the central and lower face of a brain-dead woman onto a woman aged 38 years who had suffered amputation of distal nose, both lips, chin, and adjacent parts of the cheeks. Transplantation consisted of revascularisation of right and left facial arteries and veins (ischaemic time 4 h), mucosal repair of oral and nasal vestibules, bilateral anastomoses of infraorbital and mental sensitive nerves, joining of mimic muscles with motor nerve suture on mandibular branch of the left facial nerve, and skin closure. Immunosuppressive treatment was with thymoglobulin, tacrolimus, mycophenolate mofetil, and prednisone. Two infusions of donor bone-marrow cells were given. Follow-up included routine tests, biopsies, physiotherapy, and psychological support.

**Findings** The initial postoperative course was uneventful. No surgical complication occurred. Bone-marrow graft and immunosuppression were well tolerated. Mild clinical signs of rejection were seen at day 20. Increased corticoids initially did not reverse rejection, but signs of rejection disappeared after three boluses of prednisone. Anatomical and psychological integration and recovery of sensation were excellent. At the end of the first postoperative week, the patient could eat, and speech improved quickly. Passive transmission of muscle contractions to the graft already exists; physiotherapy is being done to restore dynamic motions around the lips.

**Interpretation** The 4-month outcome demonstrates the feasibility of this procedure. The functional result will be assessed in the future, but this graft can already be deemed successful with respect to appearance, sensitivity, and acceptance by the patient.

## Introduction

For several decades, plastic and maxillofacial surgeons have tried to promote the transplantation of autologous tissues to reconstruct patients who have been severely disfigured by burns, ballistic trauma, tumours, or congenital deformities. Despite their quest to find the ideal method to restore simultaneously the aesthetic appearance and expressive function of the face, all conventional techniques—including skin grafts, local flaps, free tissue transfers, and skin expansion—have failed up to now to reach this goal.<sup>1–3</sup> Similarly, attempts to prefabricate autologous tissue transfers had disappointing results with poor motor function and unsatisfactory cosmetic appearance, because of the technical difficulty faced by the even most inventive surgeon to restore inside a flap the structure complexity that exists in each anatomical component of the face.<sup>4–6</sup> However, sporadic reports of successful total face and scalp implantations suggested that, because of their dense anastomotic vascular network, the whole facial tissues could overcome a relative ischaemia and survive entirely after a single arterial repair.<sup>7,8</sup> The idea that face allotransplantation could be used in reconstructive surgery was supported by some studies in rats.<sup>9,10</sup> Furthermore, clinical experience with composite tissue allografts, such as human hand allograft,<sup>11</sup> showed that the immunological obstacle of composite tissue transplantation could be overcome with usual immuno-

suppressive regimens.<sup>12</sup> Consequently, the remaining question in face transplantation was an ethical issue. After reviewing this question, the French National Consultation Ethics Committee allowed a partial functional allotransplantation to reconstruct the central part of the face, including the nose, both lips, and chin. On Nov 27, 2005, we undertook facial allotransplantation on a young female patient with an extended soft tissue defect corresponding exactly to these conditions. We report the results of this face allograft for the first 4 months after surgery.

## Methods

### The patient

The patient, a 38-year-old woman, was admitted to the maxillofacial surgery department of the University hospital in Amiens, France, after a severe dog bite that completely amputated her distal nose, upper and lower lips, the whole chin, and adjacent parts of right and left cheeks. The injury involved all soft tissues of the face, down to the skeleton and teeth, and was largest in the right buccal and zygomatic areas. Since conventional autologous tissue reconstruction would have required at least four or five operations to restore the four missing anatomical units, and would probably have led to poor aesthetic and functional outcomes, composite tissue allotransplantation was chosen as the first therapeutic option to reconstruct the patient's face.



Lancet 2006; 368: 203–09

Published Online

July 4, 2006

10.1016/S0140-6736(06)68935-6

See Comment pages 181 and 183

Département de Maxillofacial Surgery, Centre Hospitalier Universitaire Amiens, France (Prof B Devauchelle MD, Prof S Testelin MD, C D'Hauthuille MD); Centre Hospitalier Universitaire Lyon, Hôpital Edouard Herriot, Lyon, France (L Badet MD, Prof E Morelon MD, Prof M Michallet MD, Prof J-M Dubernard MD); and Experimental Morphology Department, Université Catholique de Louvain, Brussels, Belgium (Prof B Lengelé MD)

Correspondence to:

Prof Bernard Devauchelle, Department of Maxillofacial Surgery, University Hospital (North Hospital), 80054 Amiens, France  
devauchelle.bernard@chu-amiens.fr



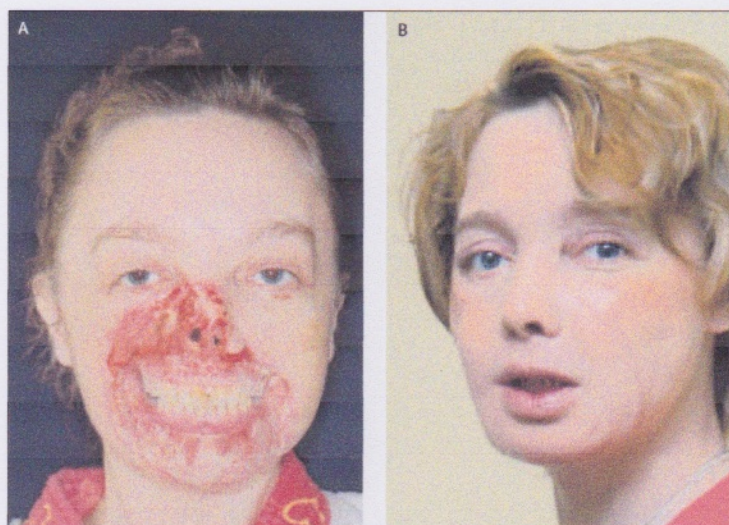

Figure 1: Patient (A) after injury (June, 2005) and (B) 4 months after surgery

After debridement, the facial wound was left in secondary healing. While the patient was waiting for the graft, intensive physiotherapy was done to reduce scar contraction of the surrounding skin and to prevent atrophy of the remaining muscles responsible for facial expressions.

Authorisation to harvest a partial face transplant on a dead, beating-heart donor and to transfer it to our patient were requested according to the guidelines of the French National Ethics Committee. Final approvals certifying that the protocol fulfilled all ethical, medical,

and scientific rules were obtained from the French Agency for Health Safety (AFSSAPS), from the French Biomedical Agency (ABM) in charge of organ procurement for transplantation in France, and from the local Protection Consultative Committee in Biomedical Research (CCPPRB, Amiens).

During this time, the patient underwent thorough psychological assessment by three different psychiatrists—one in Amiens and two in Lyon—who agreed with a fourth independent expert that the patient was fully able to cope with the procedure. Furthermore, in coordination with a lawyer, we drew up a detailed informed consent form (available on request from the authors) and a legal contract. This contract mentioned all possible complications related to this potentially life-threatening and non-life-saving procedure, especially well-known or foreseeable drug-related complications. This approach ensured that the patient's consent was given while she was fully aware of the latest available information.

Physical examination of the patient before operation showed that she retained the full integrity of the proximal stumps of her zygomatic and levator anguli oris muscles, on both sides of the injury. Clinically, all these muscles remained functional, indicating that they retained their intrinsic motor nerve supply. No depressor muscle remnants were found in the lower part of the face. Maxillary and mandibular bones were intact, and the patient kept complete healthy dentition, surrounded by undamaged gingival mucosa (figure 1, A). Despite intensive physiotherapy, scar contracture progressed and finally involved the masseter muscles, reducing mouth opening to 19 mm. The soft tissues injury also involved the distal nose; the columella, both nostrils, and the anterior part of the nasal septum were completely absent. Preoperative MRI was done to corroborate the clinical findings, and functional MRI tests were also done after the trauma, to allow study and comparison of cortical brain behaviour in the face frontoparietal areas before and after transplantation.

### Procedures

The donor was a brain-dead woman aged 46 years who died from severe, irreversible cerebral ischaemia. Her skin complexion was similar to that of the patient. The transplant coordinators asked for the family's consent to harvest and transplant a part of the donor's face. The donor and the recipient had the same blood group (O+) and shared five HLA antigens (recipient: HLA A2-3, B8-44, DR 3-7; donor: HLA A2-3, B8-44, DR 15-3). Before procurement of the face, bone marrow was harvested from the donor's iliac crests and cryopreserved in liquid nitrogen.

The face transplant was thereafter pedicled on both right and left facial vessels, first exposed on the basilar border of the mandible. The contour of the skin flap was designed very precisely in accord with a rigid

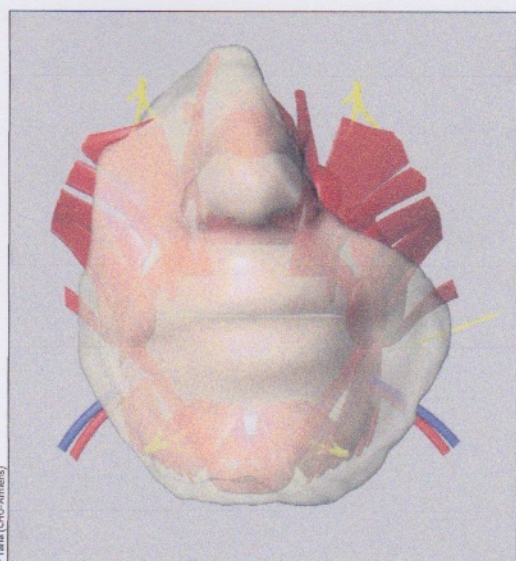


Figure 2: Anatomy of partial allograft with muscles, facial vessels, and motor and sensitive nerves that were repaired microscurgically



metallic pattern manufactured on the recipient to match exactly with the dimensions and shape of the injury. Deep dissection was made on the surface of the masseteric fascia and cheek fat pad laterally, then carried out in a subperiosteal plane medially in order to include in the graft, skin, subcutaneous tissue, all perioral muscles with their intact nerve supply arising from the zygomatic, buccal, and mandibular branches of the facial nerve, and the mucosa of the oral and nasal vestibules. The composite tissue transplant also contained alar and triangular cartilages of the nose, in continuity with the anterior part of the septum, and the right and left infraorbital and mental sensitive nerves (figure 2). At the same time, a conventional radial forearm flap was harvested from the donor's left upper limb to be transferred as a vascularised sentinel graft on the recipient's left axillary vessels.

After harvest, both facial graft and sentinel flap were irrigated with 500 mL of Institut Georges Lopez (ILG-1) organ preservation solution at 4°C, then placed in double plastic bags, in a standard ice box. The donor's nose-lips-chin triangle was reconstructed with a coloured silicone mask, custom-made inside a plaster cast moulded on her face at the beginning of the procedure.

The recipient's face was prepared to receive the graft under anaesthesia and after a tracheotomy. Extended facial dissection was done to remove all scar tissue and to isolate each anatomical structure to be joined to those dissected and individually tagged on the graft. Skin incision followed a regular curved line along the borders of the original injury. Superficial muscle dissection exposed individual stumps of the elevator bellies, with their intact motor nerve supply entering their deep surface. Terminal sensitive branches of the maxillary and mandibular nerves were exposed at the point where they left the infraorbital or mental foramina and were prepared for further microsurgical anastomoses. Blood vessels selected to revascularise the transplant included right and left facial veins, which were quite large, and right and left facial arteries, which were quite small. On the right side, a complementary submandibular approach was therefore needed to expose the proximal part of the artery.

Concomitant bench work was done on the processed allograft on a bed of iced sponges. When all vascular and nervous structures were ready for anastomoses after a complementary microsurgical preparation, the graft was transferred on the recipient's face. The right facial arteries were then anastomosed under microscopy, end-to-end, with 10/0 prolene sutures. When the clamp was released, the whole composite transplant rapidly achieved a normal colour and volume. Due to the right-left arterial anastomoses running in the labial networks, active bleeding was quickly observed on the free end of the left facial artery, attesting that the entire graft was adequately perfused. Total ischaemic time was 230 min. Further repair included the microvascular anastomosis

of the right facial veins, sutured end-to-end with 9/0 prolene, then the circumferential closure of the oral vestibule with separate 4/0 vicryl sutures and the clockwise termino-terminal repair of right and left mental and infra-orbital sensitive nerves using 9/0 prolene sutures. Although the graft perfusion was fully achieved through the right arterial and venous anastomoses, left facial arteries and veins were also repaired under microscope, end-to-end, with 10/0 prolene sutures.

Facial mimic muscles were sutured in layers, with attempts to join them individually whenever possible. On each side of the midface, repaired muscles included the buccinator, zygomaticus major and minor, levator angulae oris and levator labii superioris, risorius, and platysma. On the lower face, depressor muscles of the lower lip were reinserted on the periosteum of the mandibular border. Since all proximal stumps of the midfacial muscles had kept their original motor nerve supply, the decision was made not to sacrifice the zygomatic and buccal rami of the facial nerves to suture them on the homologous branches dissected on the transplant. To reanimate the lower face, however, a nerve termino-terminal coaptation was done on the left mandibular branch of the facial nerve. On the right side, unfortunately, this thin nerve was not found in the graft (figure 2).

Final attachment of the transplant included the ascending repair of both nasal vestibules, closure of the nasal superficial musculo aponeurotic system layer, and finally subcutaneous and skin suture. The latter was done with 6/0 sutures after moderate adaptation of the upper cutaneous edges of the recipient's injury. Silkworm guts were used to drain the subcutaneous space, and wounds were lightly dressed with short

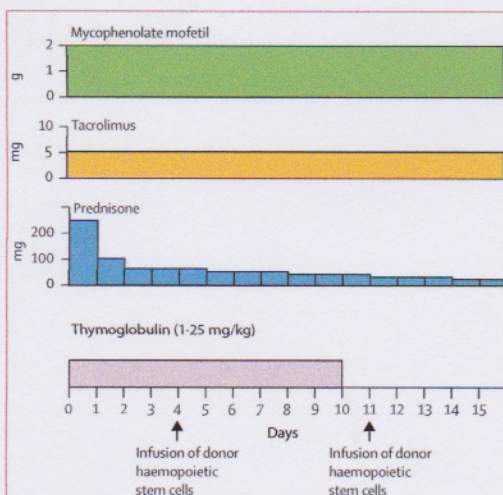


Figure 3: Immunosuppressive treatment during first 2 weeks after surgery, with two stem-cell infusions



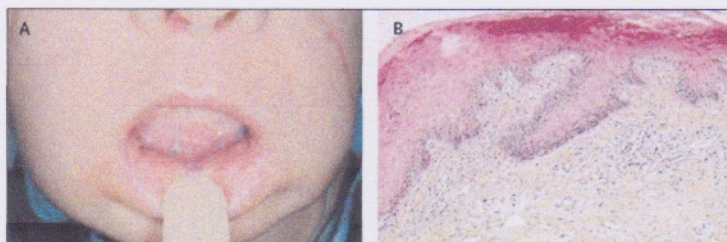


Figure 4: (A) Intraoral mucosa showing oedema and erythrosis at time of first rejection reaction (day 24), and (B) mucosal biopsy sample, day 24, with a mononuclear infiltrate of moderate density that is present in the corium

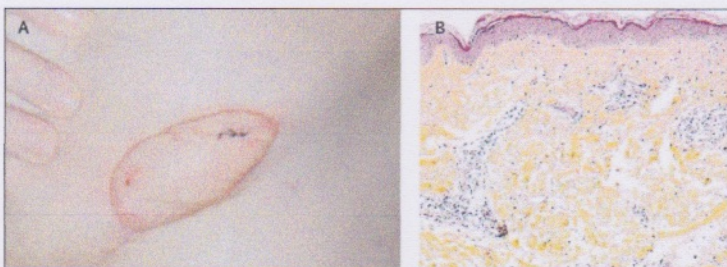


Figure 5: (A) Sentinel flap in sub-mammary fold showing erythrosis and oedema at time of first rejection reaction (day 24) and (B) pathological aspect of the sentinel skin flap with a moderately dense perivascular lymphocytic infiltrate in the dermis.

The epidermis shows a mild degree of basal cell vacuolisation and contains occasional apoptotic keratinocytes (findings suggestive of rejection reaction grade I-II).

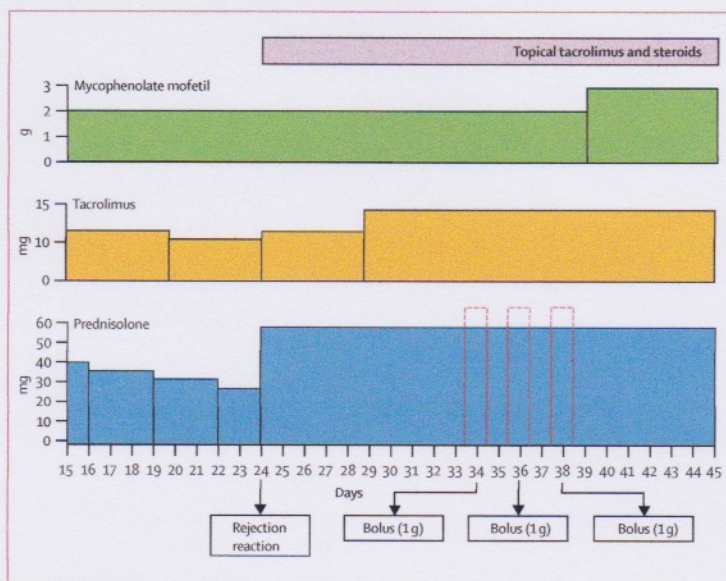


Figure 6: Immunosuppressive treatment between days 15 and 45

steriostrips only. The whole graft was left uncovered for postoperative monitoring.

During revascularisation of the transplant, the donor sentinel flap was transferred in the left submammary fold and sutured end-to-end to the recipient's

thoracodorsal vessels with 9/0 prolene sutures. This vascularised composite tissue flap, hidden under the breast, was used to monitor indirectly the immunological behaviour of the graft, aiming to avoid damage to the reconstructed face by repeated skin biopsies.

The induction immunosuppressive protocol (figure 3) was intravenous antithymocyte globulins (Thymoglobulin, Genzyme, Lyon, France, 1.25 mg/kg per day for 10 days), oral tacrolimus adjusted to maintain concentration in the blood at 10–15 ng/mL during the first month, mycophenolate mofetil (2 g per day), and prednisone (250 mg on day 1, 100 mg on day 2, followed by 60 mg per day for 10 days, then progressively reduced to 5 mg per day). Prophylaxis for cytomegalovirus infection was intravenous gancyclovir (5 mg/kg twice a day) for 5 days, followed by Valgancyclovir (900 mg per day for 5 months). For the prevention of *Pneumocystis jirovecii* pneumonia, the patient received trimethoprim sulfamethoxazole (400 mg per day) for 4 months after transplantation. Amoxicillin-clavulanate prophylaxis (3 g per day) was given for 10 days to prevent postoperative infection. Antithrombotic prophylaxis was with aspirin and subcutaneous heparin.

Frozen bone marrow was thawed immediately before infusions, which were done on days 4 and 11 post-transplant. The total numbers of nucleated haematopoietic cells infused were  $1.6 \times 10^8$  per kg on day 4, and  $1.8 \times 10^8$  per kg on day 11. The graft contained  $2 \times 10^4$  per kg and  $4 \times 10^4$  per kg colony-forming-unit granulocyte cells,  $0.12 \times 10^6$  per kg and  $0.12 \times 10^6$  per kg CD34+ cells, and  $2.7 \times 10^6$  per kg and  $4.1 \times 10^6$  per kg CD3+ cells on days 4 and 11, respectively.

Mucosa and skin biopsies were scheduled every week in the cheek mucosa and sentinel skin graft for 1 month, then monthly for 4 months. Physiotherapy was started 48 h after surgery and was offered twice daily for the entire follow-up period. The rehabilitation programme consisted of supervised controlled-motion passive and active exercises, and an early sensory re-education and cortical reintegration protocol. Psychological support was offered once daily during the first 4 weeks, then twice weekly.

## Results

The initial postoperative course was uneventful. No microsurgical complications occurred and no ischaemic or congestive area was observed on the graft, or on the sentinel flap. Wound healing occurred normally. Minor oedema of both grafts was observed in the early postoperative period, but quickly disappeared and did not delay the immediate start of the rehabilitation programme. The patient's general condition remained excellent. During the second postoperative week, she developed a transient and unexplained thrombocytosis (maximum platelet count 800 000 per  $\text{mm}^3$ ) that was treated by increasing the doses of heparin to prevent microthrombosis.



On day 18, diffuse erythema and oedema were observed on the grafted mucosa (figure 4, A). They were treated as a candida stomatitis because of the demonstrated presence of *Candida albicans* on the patient's oral mucosa. From day 20, mild and diffuse erythema and oedema progressively developed on the facial skin and on the sentinel skin flap (figure 5, A). On day 24, biopsy samples of the mucosa showed dense mononuclear cells infiltrate, some vacuolisation of basal cells, and occasional apoptotic keratinocytes (figure 4, B). At the same time, skin biopsy samples showed a moderate perivascular mononuclear cells infiltrate in the grafted derma (figure 5, B). The lesions were graded I and II according to the classification established for composite tissue acute rejection.<sup>13</sup> Based on the treatment of rejection used in patients with hand allograft (figure 6), prednisone doses were increased from 25 to 60 mg/kg per day. Tacrolimus and clobetazol ointments and steroid mouth rinses were alternately applied twice daily. Because clinical and pathological improvement was very slow, 1 g prednisone was given on days 34, 36, and 38. Tacrolimus doses were increased from 10 to 15 mg per day to maintain the blood concentration between 10 and 15 ng/mL. Mycophenolate mofetil doses were increased from 2 to 3 g per day from day 39. With this regimen, the mucosa rapidly returned to normal. Simultaneously, the redness of the graft and of the sentinel flap progressively faded. Subsequent mucosa and skin biopsies showed a substantial decrease of the cellular infiltrate, with return to normal at day 45. Chimerism was assessed once a week by use of microsatellites and quantitative PCR on total blood and CD3 and CD56 cells, and monthly on bone marrow total cells and CD34 positive cells. All results until day 90 showed a complete recipient profile in blood and marrow.

Physiotherapy started at day 1, the tracheotomy was removed at day 3, and the patient was able to eat and drink almost normally at the end of the first postoperative week. Rehabilitation training took place twice a day, and included static and dynamic facial exercises, mainly focused on the restoration of lips suspension and mouth occlusion. Sensation recovered quite quickly. Assessed by repeated Semmes-Weinstein testing, it reached the lateral part of the upper lip and the lateral mental area on both sides after 10 weeks, and thereafter involved the whole skin surface of the face transplant, including the tip of the nose at the 14th postoperative week. Oral mucosa of the graft also became sensate in the same period, so that from the end of the second postoperative month, mucosal routine biopsies needed to be done under local anaesthesia.

Motor recovery was less fast and less effective. Dynamic movements of the upper lip, due to contraction transmission from the repaired levator and zygomatic muscles, were obvious from the beginning of the 12th postoperative week. Smile, however, remains at present

incomplete and imperfect. Motions of the lower lip are not yet present, causing a slight sagging of the central inferior part of the graft (figure 1, B). Consequently, complete lip closure has not yet been achieved, and although highly improved, phonation still lacks labial occlusive phonemes. At 4 months, it is obviously too early to evaluate recovery of motion.

Psychologically, the transplant was well tolerated in the immediate postoperative period and its quick integration into the patient's new body image was greatly helped by the fast sensate recovery of its skin surface. At the end of the 12th postoperative week, the patient became able to face the outside world and returned progressively to a normal social life.

## Discussion

The early outcome of this human face transplantation confirms what was known from studies in animals<sup>14,15</sup> and from the retrospective multicentre clinical experience with human hand transplantation.<sup>12</sup> The technical feasibility of the procedure has been clearly demonstrated, with no surgical complication. Compared with conventional techniques using serial autologous tissue transfers, face allografting is an advantageous possibility for the reconstruction of severely disfigured patients in a one-stage procedure, providing entire restitution of the missing anatomical units, complete sensate recovery, and promising results in terms of appearance and motor function. Face composite tissues, however, can trigger an allo-immune response that needs to be controlled by a standard immunosuppressive regimen. This immunosuppression should be obviously a lifelong treatment, and the total agreement of the patient is needed.

To monitor this immune response without damaging the reconstructed face, we used a thin composite-tissue free sentinel flap from the donor as a site for further graft-skin biopsies. Although the skin of the forearm and face does not have exactly the same thickness, clinical and pathological changes appeared simultaneously on both during the rejection episode and were similar in the forearm fasciocutaneous flap and in the face allograft. Our observations also showed that clinical and pathological patterns of rejection might appear first on the transplanted oral mucosa, which is easier than skin to biopsy, offering another way to monitor rejection with a grading classification similar to that described in hand transplantation.<sup>13</sup>

The decision to include infusions of donor bone-marrow cells in the immunosuppressive protocol was based on experimental and clinical data showing the long-term efficacy of this approach. Such infusions efficiently induce tolerance in animals.<sup>16</sup> Since the pioneering work by Monaco,<sup>17</sup> donor bone-marrow cell infusions have been used in kidney, kidney and pancreas, liver, and heart transplantations.<sup>18-23</sup> The results of these infusions, combined with immuno-



suppressive drugs including thymoglobulin as induction therapy, has been intensively studied in cadaveric kidney transplantation.<sup>24</sup> In the long term, rates of chronic rejection were decreased and graft survival was improved, compared with controls who did not receive infusions, even in the absence of proven microchimerism. Patients did not develop infusion-related complications, graft-versus-host disease, or an increased rate of infection.<sup>24</sup> Interestingly, the immunoregulatory effect of donor bone-marrow cells on allogeneic cellular immune responses was shown in the same clinical trials.<sup>25,26</sup> Although, using the same number of nucleated cells as in bone marrow transplantation, the risk of graft-versus-host disease was reduced because of the absence of myeloablative preparation in the recipient. Bone-marrow chimerism increased progressively with time after combined kidney and donor bone-marrow cell transplantation. Whether microchimerism helps to induce allograft acceptance or whether it is only an epiphenomenon remains controversial. Allograft rejection can occur in the presence of microchimerism, and long-term graft survival can occur in the absence of microchimerism, so microchimerism cannot be used as a criterion for withdrawal of immunosuppression.<sup>27</sup>

Induction of microchimerism usually correlates with the number of donor bone-marrow cells infused. However, the minimum number of cells necessary to induce tolerance is not known. Very few donor CD34+ cells or dendritic skin cells might have a beneficial effect on the recipient's lymphocyte population in the absence of detectable microchimerism, leading to a so-called cryptochimerism that might explain the occurrence of T-regulatory cells in the skin of long-term accepted hand allografts. To increase the presence and persistence of a higher number of donor bone-marrow cells, a non-myeloablative conditioning regimen, such as those often used before haematopoietic stem-cell allogeneic transplantation, might be useful. Further investigations are needed to assess, with longer follow-up, the real benefit of the donor bone-marrow cell infusion in this face transplant.

#### Contributors

B Devauchelle, S Testelin, and J-M Dubernard organised the procedure. B Lengelé, S Testelin, and B Devauchelle designed the surgical protocol and the postoperative rehabilitation plan; preoperative anatomical work was done in the Experimental Morphology Department, Université Catholique de Louvain, Brussels. J-M Dubernard, L Badet, E Morelon, and M Michallet designed and managed the postoperative immunosuppressive regimen in the Centre Hospitalier Universitaire de Lyon. All surgical procedures and the donor operation were done under the supervision of B Devauchelle. The recipient's operation was done in the Centre Hospitalier Universitaire de Amiens under the supervision of B Lengelé and S Testelin. B Devauchelle, S Testelin, B Lengelé, and C d'Hauthuille worked together in preparation and transplantation of the facial graft and sentinel flap. All authors contributed to the final version of the paper.

#### Conflict of interest statement

We declare that we have no conflict of interest.

#### Acknowledgments

This work is the result of cooperation between the Department of Maxillofacial Surgery at Amiens University Hospital and the Department of Transplantation Surgery at Lyon University Hospital. The authors thank the administration staff of both hospitals for their efficient participation in the project. We also thank C Camby, B Averland, B Loti, and J J Colpart (Agence de Biomédecine); X Martin (head chief of the department of transplantation surgery), S Cremades, D Bachmann, and G Burloux (psychiatrists); J Kanitakis and E Carmi (dermatopathologists), N Lefrançois and P Petruzzo (transplantologists), A El Jaafari (immunologist), O Hecquet and J P Bourgeot (Etablissement Français du Sang), S Ducastelle and D Revesz (haematologists), A S Bracq, K Cheboubi, G Vilain, and J Tchoussoff (anaesthesiologists), J L Beziat (maxillofacial surgeon in Lyon); G Bitar, C Moure, S Dakpe, S Carton, F Taha, S Garson, G de Marco, and B Guichard (assistant surgeons, imaging); H Parmentier, J P Girbon, P Stefaniak, and C Couturaud (physiotherapists), A Marton and N Lisek (facial prosthetists), E Blin (operating nurse) and her team (operating theatre, Amiens); J Gouigoux (head nurse) and her team (maxillofacial surgery, Amiens), I Cengia (head nurse) and her team (transplantology, Lyon), C Berthillot (research assistant), and M P Auboyer (procedure coordinator).

#### References

- Latifoglu O, Ayhan S, Abtay K. Total face reconstruction: skin graft versus skin flap. *Plast Reconstr Surg* 1999; 103: 1076–78.
- Angrigiani C, Grilli D. Total face reconstruction with one free flap. *Plast Reconstr Surg* 1997; 99: 1566–71.
- Kawashima T, Yamada A, Ueda K, et al. Tissue expansion in facial reconstruction. *Plast Reconstr Surg* 1994; 94: 944–50.
- Pribaz JJ, Fine N, Orgill DP. Flap prefabrication in head and neck: a ten-year experience. *Plast Reconstr Surg* 1999; 103: 808–20.
- Teot L, Cherenfant E, Otman S, et al. Prefabricated vascularised supraclavicular flaps for face resurfacing after postburn scarring. *Lancet* 2000; 355: 1695–96.
- Lengelé BG, Testelin S, Bayet B, Devauchelle B. Total lower lip functional reconstruction with a prefabricated gracilis muscle free flap. *Int J Oral Maxillofac Surg* 2004; 33: 396–401.
- Thomas A, Obed V, Murkara A, et al. Total face and scalp replantation. *Plast Reconstr Surg* 1998; 102: 2085–87.
- Wilhelmi BJ, Kang RH, Movassaghi K, et al. First successful replantation of face and scalp with a single artery-repair: a model for face and scalp transplantation. *Ann Plast Surg* 2003; 50: 535–40.
- Siemionow M, Gozel-ulusal B, Ulusal A, et al. Functional tolerance following face transplantation in the rat. *Transplantation* 2003; 75: 1607–09.
- Ulusal BG, Ulusal AE, Ozmen S, et al. A new composite facial and scalp transplantation model in rats. *Plast Reconstr Surg* 2003; 112: 1302–11.
- Dubernard JM, Owen E, Herzberg G, et al. Human hand allograft: report on first 6 months. *Lancet* 1999; 353: 1315–20.
- Petruzzo P, Revillard JP, Kanitakis J, et al. First human double hand transplantation: efficacy of a conventional immunosuppressive protocol. *Clin Transplant* 2003; 17: 455–60.
- Kanitakis J, Petruzzo P, Jullien D, et al. Pathological score for evaluation of allograft rejection in human hand composite tissue allotransplantation. *Eur J Dermatol* 2005; 15: 235–38.
- Siemionow M, Agaoglu G. Allotransplantation of the face: how close are we? *Clin Plast Surg* 2005; 32: 401–09.
- Unal S, Agaoglu G, Zins J, Siemionow M. New surgical approach in facial transplantation extends survival of allograft recipients. *Ann Plast Surg* 2005; 55: 297–303.
- Prigozhina T, Slavin S. Transplantation of hematopoietic stem cells for induction of unresponsiveness to organ allografts. *Springer Semin Immunopathol* 2004; 26: 169–85.
- Monaco AP, Clark AW, Wood ML, et al. Possible active enhancement of a human cadaver renal allograft with antilymphocytic serum and donor specific bone marrow: case report of an initial allograft. *Surgery* 1976; 79: 384–92.
- Fontes P, Rao AS, Demetris AJ, et al. Bone marrow augmentation of donor-cell chimerism in kidney, liver, heart, and pancreas islet transplantation. *Lancet* 1994; 344: 151–55.



- 19 Garcia-Morales R, Esquenazi V, Zucker K, et al. Assessment of the effects of cadaver donor bone marrow on kidney allograft recipient blood cell chimerism by a novel technique combining PCR and flow cytometry. *Transplantation* 1996; **62**: 1149–60.
- 20 Corry RJ, Chakrabarti PK, Shapiro R, et al. Simultaneous administration of adjuvant donor bone marrow in pancreas transplant recipients. *Ann Surg* 1999; **230**: 372–81.
- 21 Delis S, Burke GW 3rd, Ciancio G. Bone marrow-induced tolerance in the era of pancreas and islets transplantation. *Pancreas* 2006; **32**: 1–8.
- 22 Ricordi C, Karatzas T, Nery J, et al. High dose bone marrow infusions to enhance cutaneous allograft survival: the effect of timing. *Transplantation* 1997; **63**: 7–11.
- 23 Pham SM, Rao AS, Zeevi A, et al. A clinical trial combining donor bone marrow infusion and heart transplantation: intermediate-term results. *J Thorac Cardiovasc Surg* 2000; **119**: 673–81.
- 24 Miller J, Mathew JM, Garcia-Morales R, et al. The human bone marrow as an immunoregulatory organ. *Transplantation* 1999; **68**: 1079–90.
- 25 Mathew JM, Garcia-Morales R, Fuller L, et al. Donor bone marrow-derived chimeric cells present in renal transplant recipients infused with donor marrow. I. Potent regulators of recipient antidonor immune responses. *Transplantation* 2000; **70**: 1675–82.
- 26 Mathew J-M, Garcia-Morales RO, Carreno M. Immune responses and their regulation by donor bone marrow cells in clinical organ transplantation. *Transpl Immunol* 2003; **11**: 307–21.
- 27 Monaco AP, Maki T, Hale D, Umemura A, Morita H. The enigma of tolerance and chimerism: variable role of T cells and chimerism in induction of tolerance with bone marrow. *Transplant Proc* 2001; **33**: 3837–39.