Novel Surgical Technique for Full Face Transplantation

Bohdan Pomahac, M.D.
Julian J. Pribaz, M.D.
Ericka M. Bueno, Ph.D.
Geoffroy C. Sisk, M.D.
J. Rodrigo Diaz-Siso, M.D.
Akash Chandawarkar, B.S.
Tormod S. Westvik, M.D.
Edward W. Malin, M.D.
Elof Eriksson, M.D., Ph.D.

Boston, Mass.

Background: Full face transplantation raises a new set of ethical concerns and technical difficulties when compared with partial face transplantation. Previously, it was thought that full face allografts must include bilateral superficial temporal and facial arteries, dictating the need for inclusion of donor parotid glands. This would lead to poor aesthetic outcomes and limit facial nerve coaptation to the level of the main trunk, which often results in synkinesias. The authors present a new approach to full facial allograft recovery based on blood supply from facial arteries alone. This approach eliminates the need to include parotid glands, enabling more distal coaptation of facial nerve branches and targeted innervation of effector muscles. The recovery can be reproducibly performed within 4 hours.

Methods: Three mock cadaver dissections and three full face transplantations were performed.

Results: Donor facial allografts were dissected in cranio-caudal and lateral-to-medial fashion. Individual facial nerve branches were cut medial to parotid glands and coapted to corresponding recipient nerve branches. With the exception of one parotid gland used to add bulk, parotids were generally not included in the allografts. Relevant sensory nerves were coapted. External carotid arteries were dissected, leaving only bilateral facial arteries as the primary arterial supply. All full facial allografts were well perfused immediately following transplantation and are surviving.

Conclusions: The authors describe a new, simple, and reproducible technique of full facial allograft recovery that allows perfusion using only bilateral facial arteries. Their technique follows critical principles of targeted sensory and motor nerve coaptation. (*Plast. Reconstr. Surg.* 130: 549, 2012.)

CLINICAL QUESTION/LEVEL OF EVIDENCE: Therapeutic, V.

Face transplantation is evolving as the only surgical option capable of restoring the worst facial defects. Full face transplantation presents increased technical complexity when compared with partial face transplantation. Adequate allograft perfusion is the hallmark of planning and execution of full face allotransplantation. Our understanding of angiosomes and blood supply to the soft tissues of the face is well-described.[1,2] Due to limitations of adynamic vascular injections in anatomy laboratories, the true extent of tissue perfusion beyond the borders of angiosomes is, however, unclear. Nonetheless, the available knowledge has lent foundation to the notion that full facial allograft perfusion must be based on at least facial and superficial temporal vessels. Inclusion

From the Division of Plastic Surgery, Brigham and Women's Hospital and Harvard Medical School, and the Harvard Combined Plastic Surgery Residency Program, Harvard Medical School.

Received for publication February 1, 2012; accepted March 20, 2012.

This article reports partial results of the trial registered under the name "Face Transplantation for Treatment of Severe Deformity," Clinical Trials.gov identification number NCT01281267 (http://clinicaltrials.gov/ct2/show/NCT01281267).

DOI: 10.1097/PRS.0b013e31825dc25c

Disclosure: *All work described in this article was supported by a research contract between Brigham and Women's Hospital and the U.S. Department of Defense's Biomedical Translational Initiative (contract no. W911QT-09-C-0216). Drs. Bueno, Diaz-Siso, Pomahac, and Pribaz receive partial or full salary support from this contract. None of the authors has any financial interests or commercial associations that might pose or create a conflict of interest with information presented in this article.*

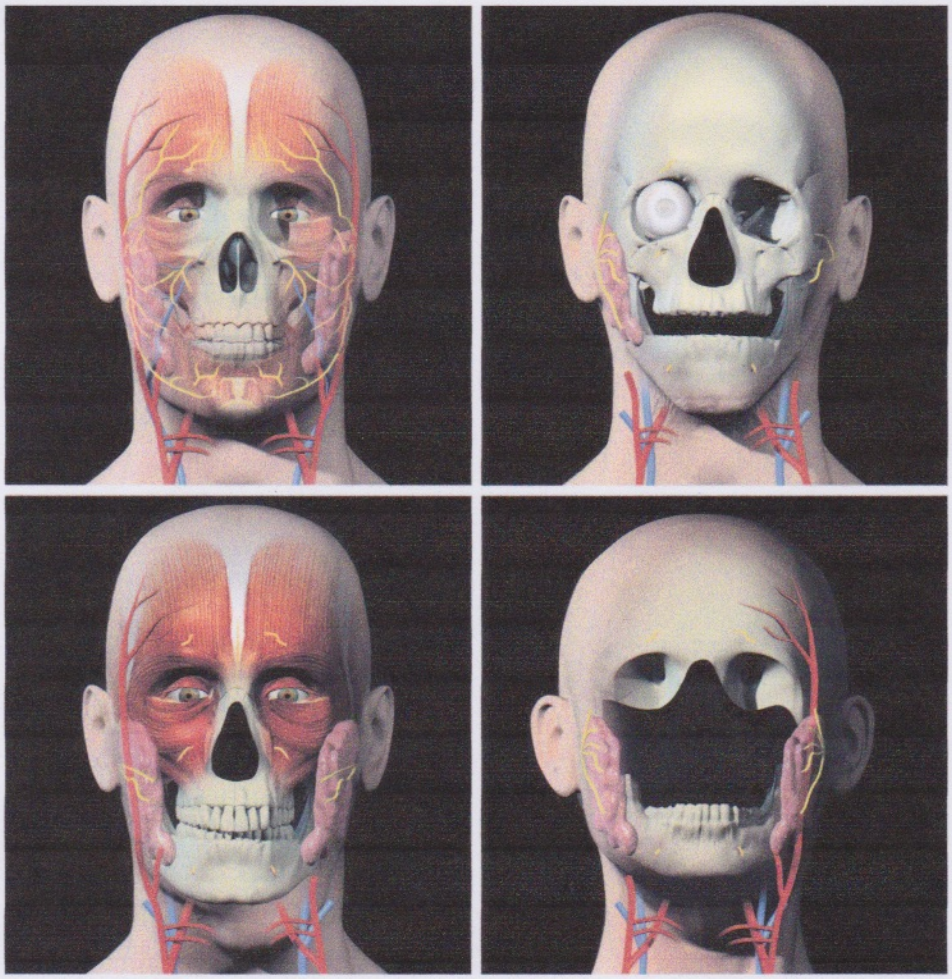

Sensory nerve (infraorbital, supraorbital, buccal, mental)
Motor nerve (facial nerve and branches)
Artery (common, internal and external carotid and branches)
Vein (internal and external jugular with facial tributaries)

Fig. 1. Vascular, nervous, and bony/soft-tissue anatomy of recipients and donor allografts: (*Above, left*) Normal anatomy, including all structures relevant to the described surgical technique. (*Above, right* and *below*) Representations of actual preoperative anatomy for transplant recipients (patients 1 to 3, respectively).

of the superficial temporal vessels requires that the parotid glands be incorporated in the allograft, imparting an unsightly fullness to the cheeks of the recipient unless superficial parotidectomy is performed before transplantation. This adds considerable time and complexity to an already prolonged and difficult operation, as well as potential morbidity to the recipient. In addition, when including the parotid glands, branching of the facial nerve is not accessible, limiting facial nerve coaptation to the level of the trunk. For targeted reinnervation of effector muscles, coaptation of motor nerve branches at more distal sites allows retention of greater native nerve length and lowers the likelihood of synkinesia and thus is highly desirable.

We present a new technique that allows for expeditious recovery of facial allografts based on facial vessels alone. The technique was utilized in three consecutive patients.[3] Our approach simpli-

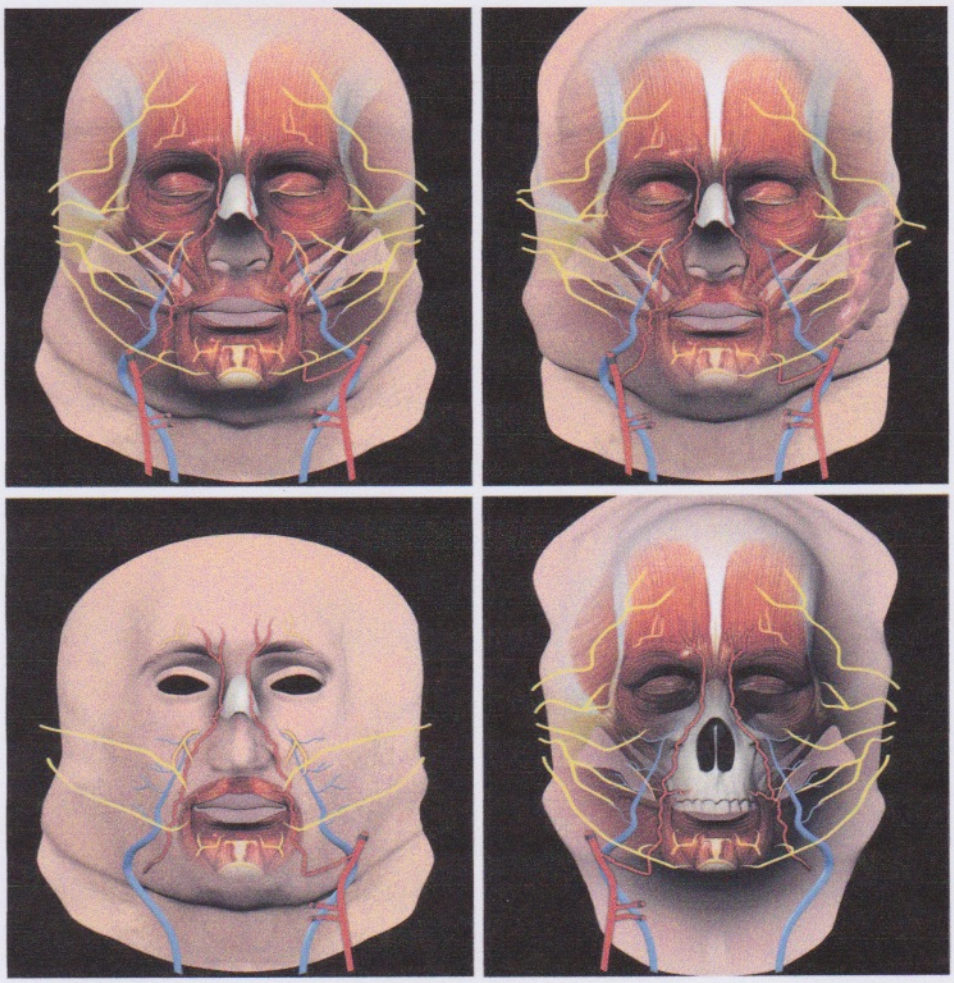

Sensory nerve (infraorbital, supraorbital, buccal, mental)
Motor nerve (facial nerve and branches)
Artery (common, internal and external carotid and branches)
Vein (internal and external jugular with facial tributaries)

Fig. 2. (*Above, left*) Full facial allograft containing all structures needed to be affixed and/or coapted in a transplantation procedure for a hypothetical patient lacking all nervous, vascular, and soft-tissue anatomy. (*Above, right* and *below*) Representations of donor allografts used for full face transplantation in patients 1 to 3, respectively. All vessels used for anastomosis and nerves used for coaptation are illustrated; any structure that was unable to be surgically reintegrated is omitted from these images.

fies the recovery and transplantation of full facial allografts by addressing technical and anatomical concerns.

METHODS

Brigham and Women's Hospital (Boston, Mass.) obtained institutional review board approval to perform full face transplantation (protocol no. 2008P000550) in the spring of 2010, when full face transplantation was unprecedented in the world. The team performed mock dissections of three freshly injected cadavers, procuring allografts that included the fronto-temporo-parietal regions of the scalp to the coronal level, eyelids, nose, and/or maxilla, muscles of facial animation, lips, motor and sensory nerves, skin of the neck to the level of the hyoid bone, and vessels to

ensure blood supply. In the spring of 2011, the team performed the first three full face transplantations in the United States in three patients who had previously given written informed consent. The dissection techniques were successfully applied and further developed in this series of clinical cases.

RESULTS AND DISCUSSION

Donor Operation

Careful analysis of the recipient defect's dimensions and composition was performed as part of preoperative planning. Procurement of donor tissues was tailored to the specific needs of each recipient (Figs. 1 and 2). Despite the individual intricacies of each donor recipient pair, an overall operative plan was established and communicated to all surgical members of the team.

Donor Allograft Dissection

In general, our approach progressed in cranio-caudal and lateral-to-medial fashion, with optimal exposure of facial and neck vessels and limited neck dissection. A coronal incision made at a position determined by the tissues needed was continued in a caudal direction to the preauricular region. Dissection continued in a subgaleal plane toward the supraorbital region. One centimeter above the supraorbital rim, dissection transitioned to the subperiosteal plane. The supraorbital and supratrochlear nerves were identified as they exited their bony foramina; the bone was trimmed using a 3-mm osteotome to allow for longer nerve length, and the nerves were tagged (Fig. 2, *above, right* and *below*).

All three recipients needed eyelids (Fig. 1, *above, right* and *below*), although two of them were missing orbits and levator muscles (Fig. 1, *above, right* and *below, right*). Donor dissections were thus approached by performing release along the palpebral conjunctival reflection with transection of the levator muscles, incision through the conjunctiva, and release of the canthal ligaments at their bony insertions. Release of these ligaments allowed "peeling" the facial allograft through the deep soft-tissue layer until reaching the inferior orbital rim, preserving the full thickness of upper and lower eyelids (Fig. 2, *above, right* and *below*). In anticipation of osteotomies, the infraorbital dissection was carried out in a subperiosteal plane along the anterior maxilla, close to the nasal bones. Staying in this deep level appears crucial to the preservation of angular arteries and their flow to the forehead and temporoparietal regions.

To facilitate central positioning of the nose, all allografts included the nasal bone pyramid. To preserve the anatomic structure of the nose, a curved osteotome was used to separate the nasal bone from the underlying malar eminence, creating a full nose composite within the facial graft (Fig. 1, *above, right* and *below*). Before elevation of the remainder periorbital soft tissues from the underlying bone, the infraorbital nerves along the floor of the orbit were tagged,[4] allowing for additional length for coaptation. In the third case, the entire maxilla was included within the allograft (Fig. 1, *below, right*). This portion of the surgery was performed as described previously.[4]

From the preauricular incisions, dissection was carefully performed in a lateral-to-medial direction on top of the parotid fascia in the sub–superficial musculoaponeurotic system layer. As they exited medially from the parotid gland, facial nerve branches were identified, individually tagged, and elevated as part of the allograft. The parotid duct was ligated and divided in all cases. More medial dissection from the anterior border of the masseter was guided by specific recipient needs; in patients requiring only muscles of facial expression and superficial soft tissues (Fig. 2, *above, right* and *below, left*), the dissection continued in the subperiosteal plane over the anterior surface of the zygoma and maxilla. In one patient who required extensive intraoral mucosal resurfacing and maxilla (Fig. 2, *below, right*), the buccal nerve was localized and dissected below the buccal fat pad. Osteotomies were then performed in the plane between the maxillary tuberosity and the pterygoids and through the nasal septum, allowing for reflection of the bilateral zygomas and midface anteriorly.

All recipients needed orbicularis oris and variable degrees of intraoral mucosa. Having released the graft in a superior-to-inferior direction until the level below the piriform aperture and a lateral-to-medial direction approaching the modiolus, perioral tissues were raised in a subperiosteal plane along the gingivobuccal sulcus and inferiorly to the mandibular border, allowing for a good cuff of tissue to use for intraoral inset in the recipient. Allografts that included a substantial maxillary component were procured to the level of soft palate.

Before releasing the lower portion of the grafts, the facial artery and vein were identified and protected. The bilateral facial artery was the sole vascular supply to all allografts. The facial artery was identified by dissection from the carotid arteries distally. The greatest difficulty of continuing this dissection to the face was presented by the

course of the facial artery around the submandibular gland. The dissection was simplified by using a subperiosteal plane in a cranio-caudal direction over the mandible, keeping the facial vessels safe within the elevated tissues. Once the facial vessels were identified and protected, dissection continued onto the mentum with preservation of the mental nerve. Submandibular glands were left in the allograft in the first patient (Fig. 2, *above, right*), but due to salivary collection and excessive bulk,[3] we carefully excluded them from subsequent allografts.

After complete dissection of the lower face, bilateral preauricular incisions were extended inferiorly to the neck. Neck dissections were carried out in the subplatysmal plane. The sternocleidomastoid muscle and its accompanying veins, including the internal and external jugular and retromandibular, were identified, and the superior aspect of the internal jugular vein was ligated and divided. By connecting the plane of the external carotid artery from the neck, and the facial artery from the face, the remaining isolation of the complete vascular pedicle was straightforward.

Simultaneous to the facial procurement, a second surgical team procured a radial forearm flap to be used as sentinel of rejection. The significance of the sentinel flap is subject to a separate future report, but briefly, it is used as an alternative site to monitor for rejection.

Although a standard procedure for donor allograft procurement was established and remains the framework of our approach, these three clinical experiences were not completely uniform. Also, the protocol evolved based on gained clinical experience and outcomes. Modifications to protocol were mostly case-by-case alterations based on recipient needs. For example, the amount of midface tissue (including bone, soft palate, and deep facial structures) recovered was adjusted as discussed above. In addition:

- The location of the coronal incision depended on the amount of scalp needed.
- Due to an extensive contour deficiency on the left side of patient 1's face (Fig. 1, *above, right*), a decision was made to include the left parotid gland with the donor allograft (Fig. 2, *above, right*) to provide bulk and improve the aesthetic outcome.
- For patient 2, the radial forearm sentinel flap included a radial sensory nerve, a portion of the flexor carpi ulnaris tendon, the flexor carpi radialis tendon, and the palmaris longus tendon to reconstruct the right hand.
- Patient 3 received bilateral hand transplants in conjunction with the full face, and thus we decided to forgo sentinel flap procurement and transplantation.

Certain aspects of allograft procurement were dictated by the overall plan for solid organ procurement. The first case (patient 1) did not allow adequate time for recovery before aortic cross-clamping and recovery of life-saving organs. This necessitated cannulation of the carotid artery and flushing of the incompletely recovered allograft face in situ. In this case, we expedited the neck dissection to ensure that our facial vascular pedicle was visualized before losing physiologic perfusion. The graft was then perfused with cold preservation solution throughout the submandibular dissection. University of Wisconsin solution was used for cold perfusion after removal of all facial allografts. The ischemia time tolerated by a facial graft has not been challenged in a clinical setting, but based on known effects of ischemia-reperfusion injury on its individual components, we recommend reperfusing within 4 hours of onset of cold ischemia. This is based on ischemia time limitations of the muscle, the most sensitive part of the allograft. Therefore, careful coordination of the donor and recipient operations and of the transport of the graft from donor to recipient was needed. Working with the organ processing organization, we safely planned for recovering the facial allografts before the solid organs, with priority on solid organ safety. The organ processing organization provided transport for our donor recovery team and packaging materials for the allograft. Close communication between both operating rooms (donor's and recipient's) allowed us to carefully synchronize the recipient's preparation and facilitate prompt revascularization of the allograft shortly after arrival.

In our three full and one central face transplantations, we used donor recovery teams of four to five surgeons. This team size allowed having one primary surgeon on each side of the face, with a shared assistant or one assistant each, while the remaining team member recovered the sentinel flap.

Recipient Operation

Under general endotracheal anesthesia via tracheostomy, patients were placed supine on the operating table. Induction immunosuppression was provided as described.[5] The first incision was approximately simultaneous to the donor's. The

facial bed was prepared by removing the overlying reconstructive layers and isolating relevant structures with emphasis on preservation/integration of functional units (Fig. 1, *above, right* and *below*), should the facial allograft ever fail. Vascular anastomoses followed, and operations ended with inset of remaining allograft tissues in a layered approach. Teams of two surgeons with a resident assistant worked at each side of the recipients' faces during the operation, with periodic rotations for rest or specialty tasks.

Extensive preoperative vascular mapping with computed tomography angiography and magnetic resonance image[6,7] informed a specific plan for each recipient's vascular anastomoses; vascular anatomies were unique, depending on the extent of the original injury and reconstructive efforts (Fig. 1, *above, right* and *below*). All existing major motor and sensory nerves were dissected. All operations proceeded without significant complications and were completed within 14 to 19 hours.

Recipient Dissection

Dissection of the neck was performed in conventional fashion, focusing on isolating the external carotid and its facial, superior thyroid, and lingual branches, the internal and external jugular veins, all available branches of the facial nerve, and all relevant sensory nerves. The main trunk of the facial nerve was identified and traced retrograde. In patient 1, it was found cut and clipped on left side, with only the upper and lower divisions available (Fig. 1, *above, right*). In patient 2, only the buccal and marginal mandibular branches were needed for the return of motor function to the lips (Fig. 1, *below, left*). In patient 3, all six branches were isolated on each side (Fig. 1, *below, right*).

Only patient 3 received an allograft including a bony component (Fig. 2, *below, right*). The patient had a small amount of bone removed from the nasal root to help fit the transplanted bone segment into the correct position. The allograft itself was also modified to remove some of the nasal root bone as well as the zygomatic buttresses bilaterally. The lining of patient 1's perioral region was preserved to serve as adequate sewing surface. The skin over the orbits of patients 1 and 3 was removed, but the grafted surfaces were preserved (Fig. 1, *above, right* and *below*). Skin grafts were removed from the surface of the upper and lower eyelids of patient 2. Supraorbital and infraorbital nerves could not be found on the left side of patient 1, due to orbital exoneration (Fig. 1, *above, right*).

Allograft Inset

Vascular anastomoses were performed with the face flipped down on the recipient's chest and under microscope magnification (one microscope per side). A vessel size mismatch was observed in patient 1, with the allograft's common and external carotid arteries and internal jugular vein approximately 50 percent larger than the recipient's. This was addressed by performing a single anastomosis between the external carotid of the recipient and linguofacial trunk of the allograft in end-to-end fashion. Internal jugular veins were anastomosed end-to-end on one side and end-to-side on the other to prevent cerebral edema. In patient 2, the external carotids were anastomosed on the left side and facial arteries on the right side to preserve adequate perfusion to the hypopharynx and tongue, with internal jugular to retromandibular veins on the left side and retromandibulars on the right. In patient 3, facial arteries were connected on the left, but due to previous operations, we decided to connect the right-sided external carotids in an end-to-end fashion. Retromandibular veins were anastomosed on the left side and internal jugular veins on the right. On retiring the clamps, excellent blood flow without significant bleeding complications was observed in all three allografts. Full revascularization took approximately 5 to 10 minutes. After vascular anastomoses, the general sequence of inset followed the direction central-to-lateral, and inferior-to-superior. Preoperatively customized ocular spacers were sutured in place in patients 1 and 3. Patient 2 had skin-grafted upper and lower eyelids, the latter of which were contracted, but the eyelids were functional. It was decided to preserve the canalicular structure together with the eyelid margins and transfer only the well-perfused thin eyelid skin with some underlying orbicularis muscle as an overlay.

Neurorrhaphies were also performed under microscope magnification. Nerve grafts were needed in patients 1 (thoracodorsal and contralateral) and 3 (greater auricular nerve) to bridge distances. Patient 2's facial nerve neurorrhaphies were simpler, because only the mental and buccal branches were needed. Sensory and motor neurorrhaphies were performed before bone fixation in patient 3.

Nasal bones were fixed into patient 1 and 2's facial beds by using 1.5-mm-thick titanium plates (Synthes, West Chester, Penn.) secured to the nasal frontal junction with 4- to 6-mm screws. In patient 3, the bony components were inset with Synthes matrix midface plating system utilizing

two L-shaped plates at the nasofrontal junction, two semilunar plates at the zygomaticofrontal-zygomatic junction, and an H plate and a straight plate at the right zygomaticofrontal or zygomatic right osteosynthesis. The left osteosynthesis was performed with a semilunar plate and straight plate. The nasal frontal junction was secured with two inverted L plates going from the nasal bones to the frontal bar. These plates were secured with 2.0-mm screws of 6- and 8-mm depth. In all patients, numerous Mitek (Burnsville, Minn.) anchors were used in different locations in the zygoma, supraorbital bar, and mandible as securing items for the transplant. Intraoral closure used sutures in simple and horizontal mattress fashion to achieve a watertight seal. Patient 3's allograft was inset from inside at the level of the palate, as the intraoral opening was rather limited and prevented suturing the mucosa to the mucosal incision line from inside the mouth. To make certain that the maxilla was in proper position, malleables were used to measure the distance from the infraorbital rim to the porion and the level of the occlusal plane. The malleables were approximately parallel, indicating a maxillary position consistent with Bolton normative data for an 18-year-old normal male subject.

The operation finished with skin suturing tailored to promote optimal contour and integrity. Drains were inserted on each side of the face and centrally. A third surgical team transplanted the sentinel flap to the right groin of patient 1 and to the dorsal aspect of the hand of patient 2 for reconstruction. The initial postoperative follow-up has been described elsewhere.[3] Briefly, patients were discharged within 2 to 6 weeks. They were followed closely with respect to allograft survival, rejection, immunosuppression, infectious complications, and others. All facial allografts survived and recovered according to expectations.

CONCLUSIONS

We present a simple and reproducible technique for full facial allograft recovery supporting full face allograft vascularization based on the facial vessels only and including all main sensory and motor nerves. In addition, our technique excludes the parotid glands from full facial allografts, allowing more distal nerve coaptation and an improved aesthetic result. We successfully recovered three full facial allografts using this technique, each under 4 hours and without surgical complications. The allografts demonstrated rapid and complete reperfusion after the first arterial anastomosis. Small alterations to our technique can be easily implemented based on the unique characteristics of a recipient's defect. Our approach to facial allograft recovery supports the practice of simpler and more efficient full face transplantation.

Bohdan Pomahac, M.D.
Division of Plastic Surgery
Brigham and Women's Hospital
75 Francis Street
Boston, Mass. 02115
bpomahac@partners.org

ACKNOWLEDGMENTS

The authors thank the sponsor of this study, the United States Department of Defense's Biomedical Translational Initiative (research contract no. W911QY-09-C-0216). The authors also wish to convey their gratitude to Benoit Lengele, for hosting and collaboration with cadaver dissections at the Catholic University of Louvain, as well as to all members of the multidisciplinary face transplantation team at Brigham and Women's Hospital, the Brigham and Women's Hospital administration, and the Partners Human Research Committee, for enabling the interventions described in this article. The authors also express special gratitude to the donor families and the New England Organ Bank for their roles in procuring for their patients the gift of a facial allograft.

REFERENCES

1. Taylor GI, Palmer JH. The vascular territories (angiosomes) of the body: Experimental study and clinical applications. *Br J Plast Surg.* 1987;40:113–141.
2. Houseman ND, Taylor GI, Pan WR. The angiosomes of the head and neck: Anatomic study and clinical applications. *Plast Reconstr Surg.* 2000;105:2287–2313.
3. Pomahac B, Pribaz J, Eriksson E, et al. Three patients with full facial transplantation. *N Engl J Med.* 2012; 366:715–722.
4. Pomahac B, Lengele B, Ridgway EB, et al. Vascular considerations in composite midfacial allotransplantation. *Plast Reconstr Surg.* 2010;125:517–522.
5. Pomahac B, Pribaz J, Eriksson E, et al. Restoration of facial form and function after severe disfigurement from burn injury by a composite facial allograft. *Am J Transplant.* 2011;11:386–393.
6. Soga S, Pomahac B, Mitsouras D, et al. Preoperative vascular mapping for facial allotransplantation: Four-dimensional computed tomographic angiography versus magnetic resonance angiography. *Plast Reconstr Surg.* 2011;128:883–891.
7. Soga S, Ersoy H, Mitsouras D, et al. Surgical planning for composite tissue allotransplantation of the face using 320-detector row computed tomography. *J Comput Assist Tomogr.* 2010;34:766–769.