The Technical and Anatomical Aspects of the World's First Near-Total Human Face and Maxilla Transplant

Daniel S. Alam, MD; Frank Papay, MD; Risal Djohan, MD; Steven Bernard, MD; Robert Lohman, MD; Chad R. Gordon, DO; Mark Hendrickson, MD; Maria Siemionow, MD, PhD, DSc

Objective: To discuss the technical and anatomical analysis and design of an osteocutaneous allograft transplant incorporating the donor maxilla and the execution of the operative protocol during the transplant.

Methods: The Cleveland Clinic reported the world's first successful combined face and maxilla transplant in December 2008. Unlike the 3 prior face transplants, this surgical procedure was done as a salvage operation in a patient who had undergone 23 major reconstructive procedures. The additional complexity due to significant postoperative scarring and recipient vessel depletion presented a unique challenge in this case. The extensive 3-dimensional losses of facial structures in multiple tissue planes required a Le Fort III osteomyocutaneous allotransplant incorporating the donor maxilla.

Results: We report the first successful transfer of a complete bony framework and soft-tissue envelope. The allograft has shown excellent integration and no long-term rejection. The traditional conception based on anatomical studies suggested that this transfer would require independent dissection of the internal maxillary vascular system. This was not required in our patient whose allograft was based solely on the facial arterial system and its arcades.

Conclusions: Successful near-total face and maxilla allograft transplant can be accomplished based on the facial arterial system and its arcades. This presents a novel method for reconstructing massive facial injuries with significant involvement of the facial skeleton.

Arch Facial Plast Surg. 2009;11(6):369-377

Our group at The Cleveland Clinic, Cleveland, Ohio, performed the first near-total face and maxilla transplant on December 9, 2008.[1] This surgical procedure is the fourth in a series of facial transplant cases and the first in the United States. At the time this article was written, a total of 7 transplants had been performed. The first reported case in 2005 by Devauchelle et al[2] reconstructed a low triangular-shaped soft-tissue facial injury. The subsequent 2 procedures (Lantieri et al[3] and Guo et al[4]) were for larger facial defects but still lacked a significant component of facial skeleton transfer. This case is unique in that the majority of the maxilla and palate were included in the allograft. Also, the previous 3 cases were done as primary reconstructive procedures for extensive facial defects. In our procedure, the patient had undergone multiple attempts at conventional free flap–based reconstruction prior to her transplant. While this arguably strengthens the ethical basis of the procedure, as traditional surgical means were used to their limits, the transplant procedure was done in a field of scar and recipient vessel depletion that required a thorough vascular workup of the recipient to determine feasibility before the procedure was undertaken.

Videos available online at www.archfacial.com

For editorial comment see page 366

This report discusses the technical and anatomical details of this unprecedented procedure. While there are common themes to the prior cases, it is clear that the individual, unique nature of the tissue defect in each patient requires a specific-tailored operation for each individual. The following 3 critical elements are presented and discussed: a recipient analysis in terms of surgical defect and recipient vascular status; the design of the allotransplant based on critical anatomical elements and angiosomal considerations; and finally, a detailed description of the surgical procedure.

Author Affiliations: Section of Facial Aesthetic and Reconstructive Surgery, Head and Neck Institute (Dr Alam) and Dermatology & Plastic Surgery Institute (Drs Papay, Djohan, Bernard, Lohman, Gordon, Hendrickson, and Siemionow), The Cleveland Clinic, Cleveland, Ohio.

Figure 1. Preoperative patient images. Standard frontal (A), lateral (B and C), and three-quarter (D and E) images are shown.

METHODS

RECIPIENT PATIENT ANALYSIS

The recipient patient was a 46-year-old woman with a history of a gunshot wound to the midface. She was originally seen in 2004 by the Plastic Surgery Department, and underwent 23 reconstructive procedures in an attempt to repair her completely absent midfacial segment including multiple local/pedicle flaps (ie, temporalis transfers and paramedian forehead flap, among others), 3 microvascular flaps (ie, fibula, anterolateral thigh, radial forearm), and numerous split-thickness calvarial grafts. She continued to have significant disfigurement and functional limitation after these procedures and therefore was seen for evaluation by the multidisciplinary Cleveland Clinic Face Transplant Team (established following institutional review board approval protocol in 2004). The surgical team included 7 plastic surgeons and 1 facial plastic surgeon (D.S.A.).

The preoperative images of the recipient patient are shown in **Figure 1**, and a 3-dimensional facial reconstruction series is shown in **Figure 2**. The entire midface of this patient was essentially absent or surgically altered. An abbreviated list of the major anatomical deficits in the recipient patient includes the following:

1. Complete midfacial structural loss with absent nasal structure covered by a paramedian forehead flap, absent maxilla, zygoma, and orbital rims bilaterally
2. Loss of vertical facial height due to midface collapse and retrusion
3. Relative excess midfacial width
4. Right eye enucleation with prosthesis
5. Bilateral canthal tendon irregularities with telecanthus
   - The right had neither medial or lateral canthal tendon attachments with significant vertical eyelid shortening
   - The left had an intact lateral attachment; it also had significant eyelid shortening.
6. Right brow malposition from prior paramedian forehead flap
7. Right temporal wasting from prior temporalis flap
8. Right facial bulk from prior anterolateral thigh flap
9. Oral commissure droop due to the absence of midfacial mimetic musculature and orbicularis suspension

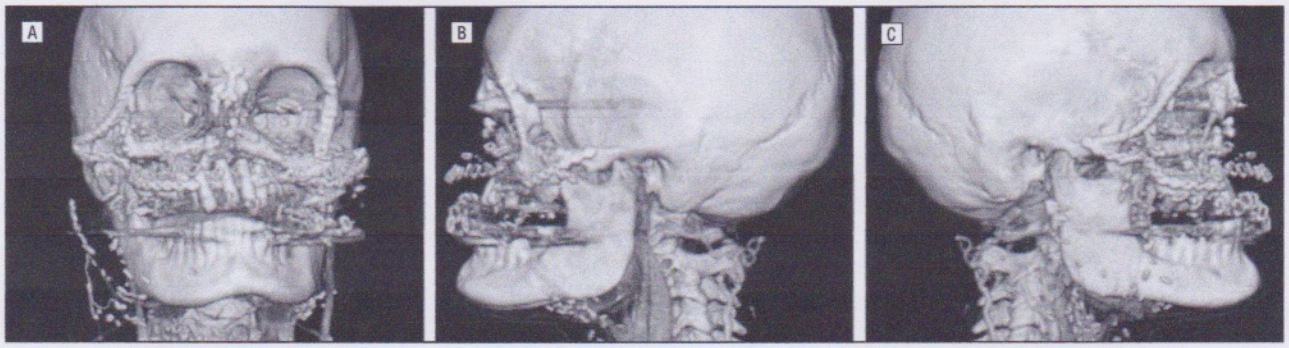

Figure 2. Preoperative computed tomographic reconstruction of patient. Three-dimensional reconstruction of the patient's preoperative bony skeleton: frontal view (A) and left (B) and right (C) views.

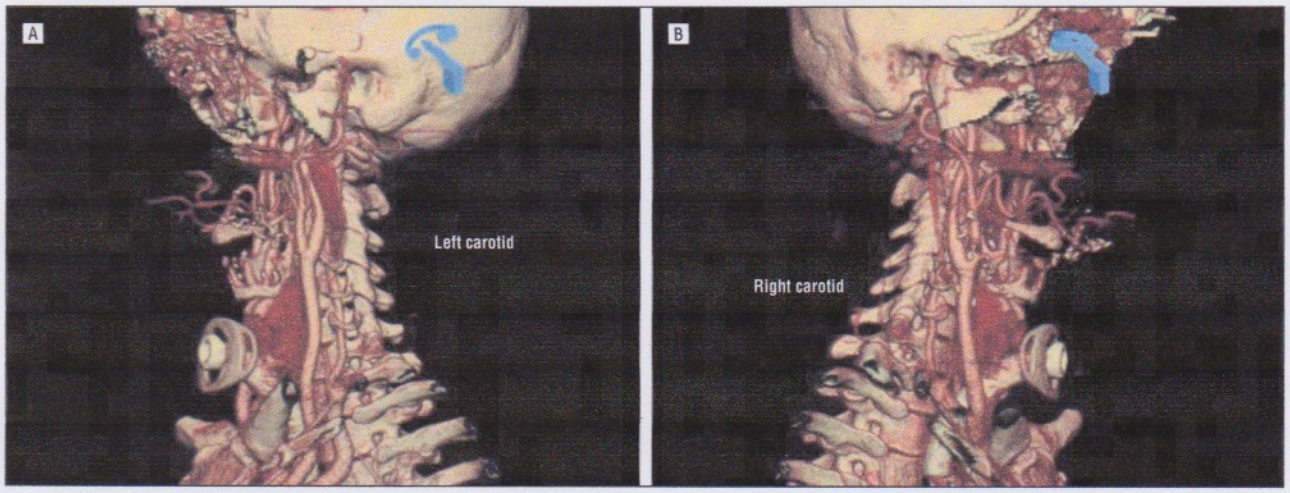

Figure 3. Preoperative angiogram. Computed tomographic angiogram images of the left (A) and right (B) carotid systems.

10. Supraorbital hollowing from loss of inferior orbital support and relative ptosis of the orbital contents
11. Maxillary soft-tissue retrusion and displacement
12. Facial nerve
    - No midface function (no nerve or muscle)
    - Right brow paralysis (left functions)
    - Lower division paresis

The extent of the defect included a complete absence of any nasal or septal structure. This had been previously managed by soft-tissue coverage using a paramedian forehead flap. She also had no maxilla, zygomatic arches, or orbital rims. The scar contracture in the region and the prior flap coverage had eliminated a nasal passageway, rendering the patient anosmic and an obligate mouth breather. The absence of any mimetic musculature in the midface left her with a functional bilateral facial paralysis and significant oral incompetence. The majority of the tissues in this region were residual components of her prior reconstructions and were nonfunctional.

Another consequence of her extensive surgical history was scarring and fibrosis in the soft tissues of the neck and the resultant depletion of recipient vessels. To evaluate her vascular candidacy for transplant, a computed tomographic angiogram of the neck was performed as a part of her preoperative workup. The image results are shown in **Figure 3**. The left-sided vascular tree had an intact external carotid and facial arterial system and a patent internal jugular (IJ) vein for venous outflow. The right system, however, showed compromised external carotid artery (ECA) branching and facial artery absence in the neck (from prior free flap reconstruction in the neck) with only an intact distal ECA. This side also had a significant narrowing and stricture in the superior IJ veins. Both sides had loss of the internal maxillary system early in its course as a part of the patient's original facial trauma.

The preoperative vascular map of the patient presented 2 distinct challenges for safe allotransplantation. The first was the ability to identify vessels in the multiply operated necks with significant scar formation. The second, and perhaps of more concern, involved accomplishing safe transfer of the donor flap while preserving critical blood supply to the native face. Because of the complete structural absence of the midface, the transverse facial arteries and the midface vascular arcades connecting the superficial temporal-supratrochlear-supraorbital system in the upper face to the facial arterial system in the lower face were absent. In essence, the lower face was supplied almost exclusively by the single left facial artery (because the right facial artery was absent). The upper face was supplied by bilateral ECA systems but without any contribution from the facial vessels due to the relative vascular division of the midface. The angiosomal divisions of the patient's face are shown in **Figure 4**.

In summary, the ideal donor allograft would include skin and soft-tissue coverage for the majority of the lower face excluding the lower lip and chin aesthetic subunits. The parotids would be included to capture the facial nerve, and the midface muscles would have to be transferred to restore mimetic function. In addition, the upper lip and buccal mucosa would need to be included. The optimal recipient vessel choices would require preservation of the left facial artery and at least 1 distal

ECA to the scalp to preserve native facial tissue from potential vascular compromise.

ANATOMICAL DESIGN AND FLAP PREPARATION

Based on these specific anatomical requirements of this patient, the technical design of the donor flap was undertaken once our exhaustive pretransplant workup was finalized. This included evaluations from the departments of transplant surgery, transplant psychiatry, and bioethics. The complex nature of the patient's skeletal loss presented a unique challenge of incorporating vascularized maxilla into the transplanted face. Numerous prior anatomical studies have been reported in the literature of potential transplant options for osteocutaneous transfer involving the use of the external carotid system with the internal maxillary vessels as the primary blood supply to the palate.[5-10] While the anterior wall of the maxilla can be vascularized based on the periosteal supply from the overlying soft tissue, which is supplied by the facial arterial system, the potential of the facial arterial system supplying the potential watershed area of the posterior hard palate had not previously been considered. The question remained of how much blood supply this region would get from mucosal arcades from the buccal mucosa intraorally and from Kiesselbach plexus communications to the posterior nasal vessels from the anterior nasal cavity. Because these anastomotic networks occur at the level of microscopic vessels, they have not been readily identified in latex injection vascular studies. Therefore, our preoperative plan in this case was to harvest the entire hard palate and then determine the posterior limits of the transfer based on intraoperative findings such as distal bleeding. The decision to avoid separate dissection of the internal maxillary artery system was chosen in an effort to avoid excess blood loss and to reduce surgical time, since the palatine vessels are the last branch in this system and all others would need to be ligated. In this case, the facial arterial system was more than adequate to supply the entire palate, and brisk bleeding was noted from the posterior limits of the dissection. Had this not been the case, the palate would have been backcut to healthy bleeding tissue.

Figure 4. Preoperative facial angiosomes. Due to the complete absence of midface vascularity and prior recipient vessel depletion, the recipient face had essentially become 2 isolated angiosomes. The upper angiosome supplied by bilateral distal external carotids is shown in blue and the lower angiosome supplied by the left facial artery primarily is shown in green. (Reprinted with permission, Cleveland Clinic Center for Medical Art & Photography © 2009. All Rights Reserved.)

The design of the donor facial soft-tissue and skin envelope incorporated the entire cheek subunit, the entire nose, and the entire upper lip. The flap was planned as a full-thickness flap including the buccal mucosa in the midface. In the lower third of the face where the patient had existing viable tissue, the flap was harvested in the subplatysmal plane with incorporation of both the parotid and portions of the submandibular gland for safe preservation of the neurovascular pedicles. This design intentionally incorporates redundant glandular tissue, which will need to be removed in a planned revision procedure in the future. Our team's mission was to reconstruct the craniofacial skeleton and overlying soft tissue for primary function; facial aesthetics would be delayed as a second-stage operation.

The donor facial nerve was taken at the exit of the stylomastoid foramen, and the donor's hypoglossal and vagus nerves were also harvested as a motor nerve bridge graft to encompass the gap between the recipient's upper division branches and the donor facial nerve trunk. Because the donor flap only includes midfacial musculature, the presumption is that the upper division axonal ingrowth, although it could track down any of the donor facial nerve branches, will only innervate the midfacial segment. This should result in appropriate volitional movement with minimal synkinesis.

Based on these considerations, a detailed operative protocol was prepared for the guidance of multiple tailored mock dissections prior to listing our patient as a candidate for face transplantation. The complete donor allograft specimen is shown in **Figure 5** with a schematic diagram in **Figure 6** (video 1 available at http://www.archfacial.com).

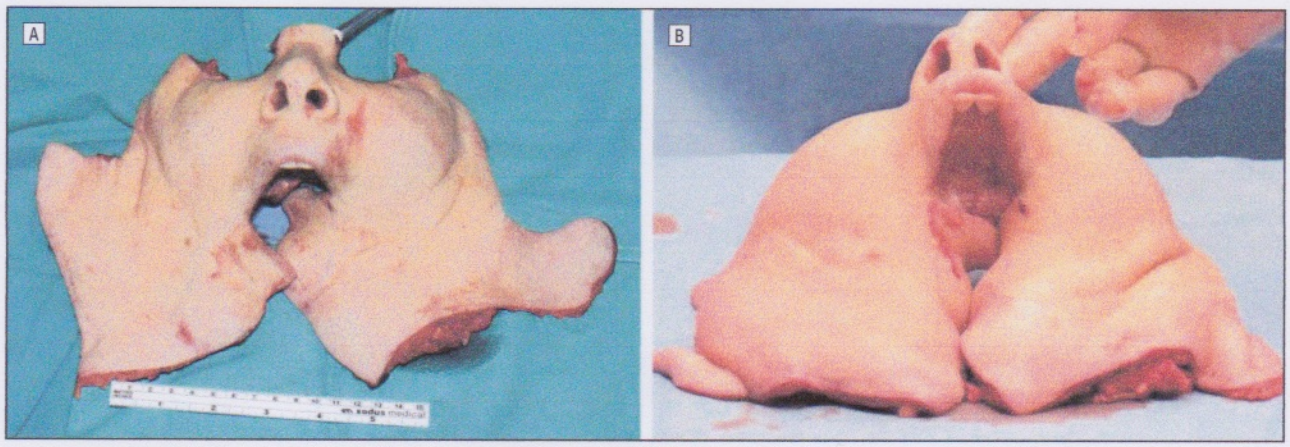

Figure 5. Donor allograft specimen. Intraoperative photographs of the donor allograft are shown in frontal view (A) and from the inferior aspect (B).

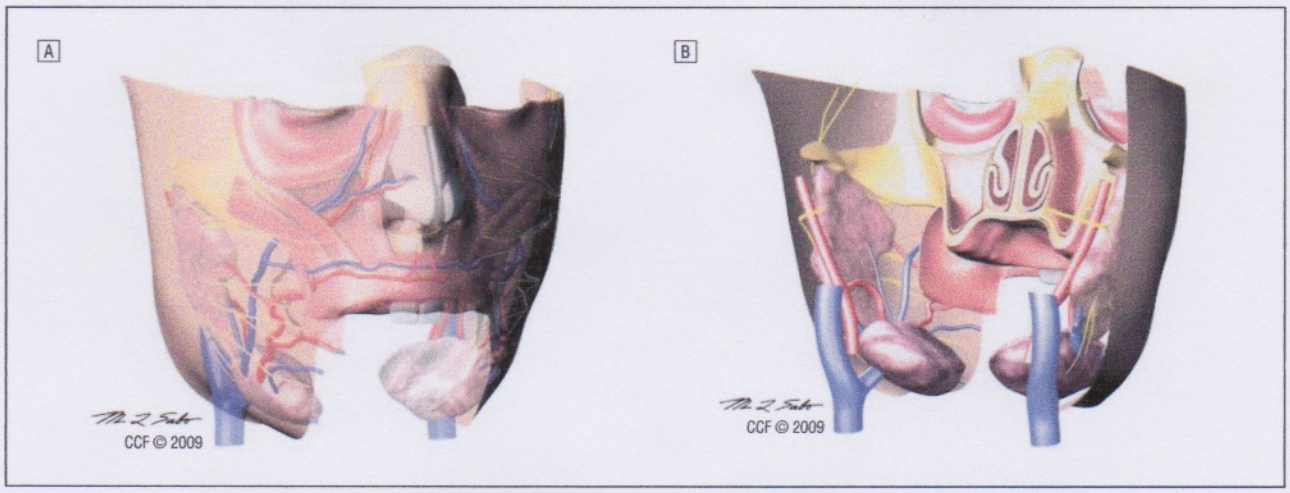

Figure 6. Donor allograft schematic diagrams. The tissue composition of the donor allograft is illustrated from the frontolateral view (A) and the posterolateral view (B). (Reprinted with permission, Cleveland Clinic Center for Medical Art & Photography © 2009. All Rights Reserved.)

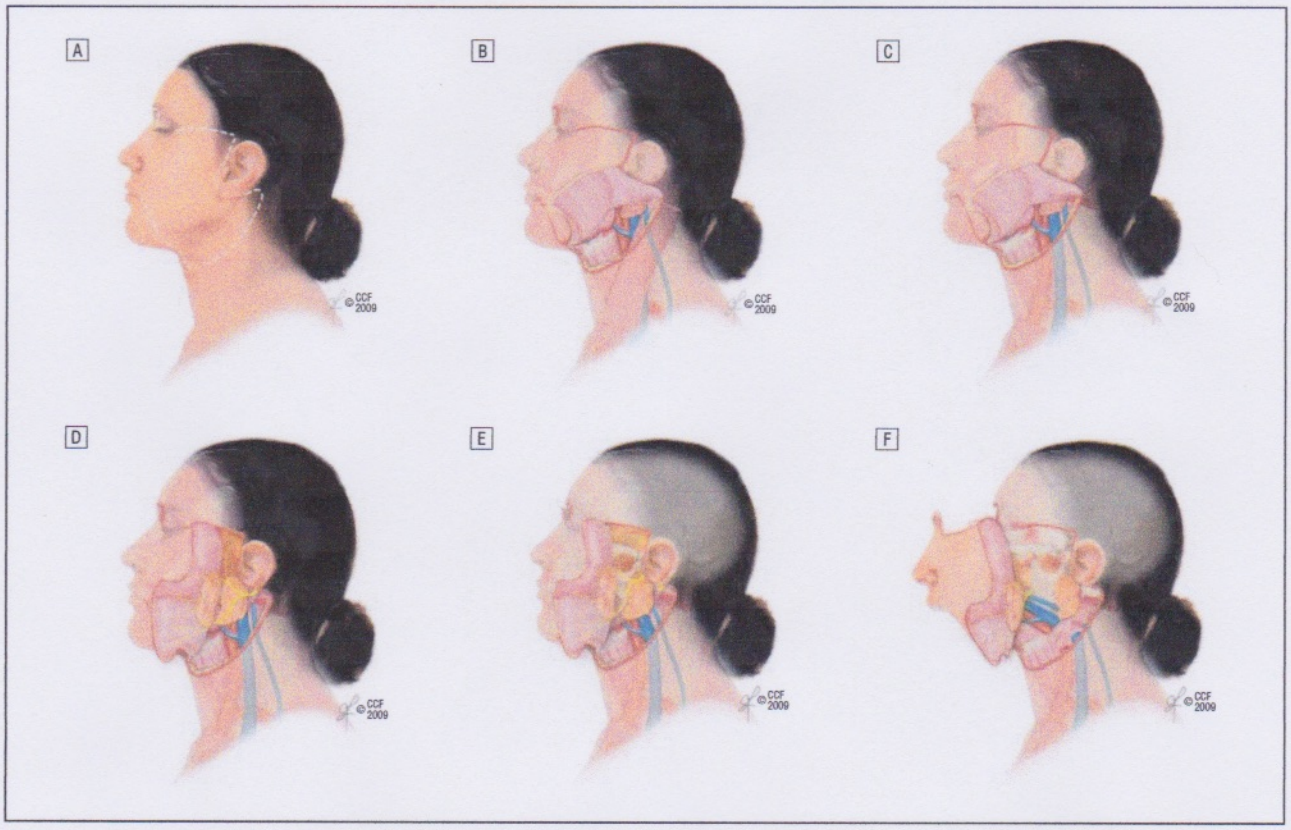

Figure 7. Harvest operative illustrations. A, Initial incision diagram; B, subplatysmal flap elevation with exposure of submandibular and parotid glands; C, sternocleidomastoid muscle excision to improve great vessel exposure; D, superficial parotidectomy to expose facial nerve; E, exposure of zygoma, orbital rims, frontal bone, and sectioning of facial nerve at the proximal trunk; F, Le Fort III osteotomies and mobilization of allograft. (Reprinted with permission, Cleveland Clinic Center for Medical Art & Photography © 2009. All Rights Reserved.)

RESULTS

OPERATIVE PROTOCOL

The principle steps of the procedure are shown in **Figure 7**, which illustrates the facial organ recovery and inset procedures. Briefly, the recovery was begun with an apron incision 4 cm below the mandible, which was extended to the postauricular region overlying the mastoid tip and then extended in a preauricular fashion up to a point 1 cm above the level of the zygoma and parallel with the lateral canthus. The inferior limb was similar to a standard Blair incision. After the incisions were complete, the superior portion of the flap was dissected through the soft tissues to expose sites of the osteotomies (Le Fort III). This dissection was aided by bilateral enucleations.

The soft-tissue dissection began by dividing the platysma inferiorly and beginning the subplatysmal dissec-

tion of the pedicle vessels. The great vessels were isolated low in the neck below the carotid bifurcation. Meticulous dissection was carried superiorly to identify facial arterial system. The venous system was then dissected in a similar inferior to superior manner. Bilateral IJ, common facial, and retromandibular vein systems were dissected away from the underlying deep neck tissue.

After the inferior vascular dissection was completed, the retromandibular vein and the superior IJ vein were then traced to the parotid gland and through this tissue. This, along with the posterior belly of the digastric muscle, was used for identification of the facial nerve trunk as it exited the stylomastoid foramen. The nerve was divided as proximally as possible to provide for extended length.

The facial vessels were dissected to the submandibular gland, which was included in the donor allograft to limit risk of vessel injury and/or spasm. Distal to the gland, a cuff of mandibular periosteum and master muscle was included to protect the facial artery as it crossed over the mandibular notch. The intraoral mucosal cuts were then performed.

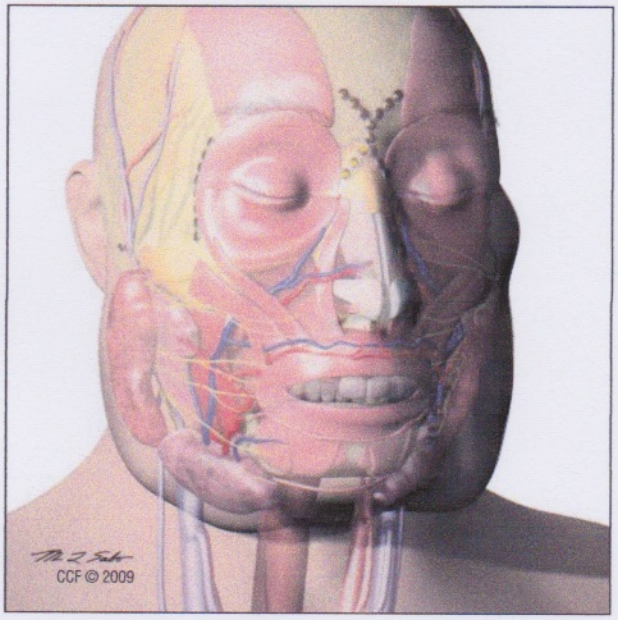

Figure 8. Schematic diagram of the complete allograft inset. Complete allograft inset shown in right three-quarter view. (Reprinted with permission, Cleveland Clinic Center for Medical Art & Photography © 2009. All Rights Reserved.)

After all of the soft-tissue dissection was complete and the flap was freed up inferiorly, the Le Fort III osteotomies were made. The endonasal septal cuts, lateral nasal wall cuts, and lateral maxillary sinus cuts were then made as the flap was "mobilized" in a superior to inferior fashion. The final elevation of the midface region (ie, buccal fat, a cuff of masseter muscle, intra-oral mucosa) was performed to allow the allograft to flip inferiorly, exposing the deep bony surface. Any bony irregularities and spurs were taken down with a high-speed drill and irrigation.

Concurrently, during the donor recovery procedure, the patient had the residual hardware and scar tissue removed in preparation for her transplant. Unfortunately, because of the extensive soft-tissue loss and fibrosis, the proximal ends of the infraorbital nerve were unidentifiable, and so sensory nerve reinnervation was not done. Bilateral superficial parotidectomies were performed to identify the facial nerve and the upper division in particular. The orbital floor was reconstructed posteriorly with Medpor implants (Porex Surgical Inc, Newnan, Georgia).

Once the recipient wound bed was prepared, the vessels were divided in the donor room and the transplant allograft was taken to the adjoining recipient operating room. The first step of the ischemic period was rigid fixation. The plating was done at 5 points including bilateral zygomatic arches and orbital rims and the nasofrontal region. Once primary bony fixation was complete, the microvascular anastomoses were performed.

The anastomoses were begun on the left side owing to the better condition of recipient vessels on this side. The left recipient ECA was sutured to the donor facial artery. The left common facial vein and external jugular vein were sutured to their recipient counterparts in the neck. The recipient's native left facial artery was left intact to perfuse the lower face-chin region. All of the anastomoses were performed with 9-0 nylon sutures placed in an interrupted fashion.

After the first side was completed, the vascular clamps were released prior to starting the second side. The total ischemia time for the rigid fixation, plating, and the left-sided microvascular anastomosis was 2 hours and 40 minutes. There was excellent blood flow from the contralateral skin flap suggesting a good perioral vascular arcade along the labial vessels. The right microvascular anastomosis was then performed. On this side the proximal stump of the recipient facial artery was used leaving the recipient ECA intact. The only venous outflow used on

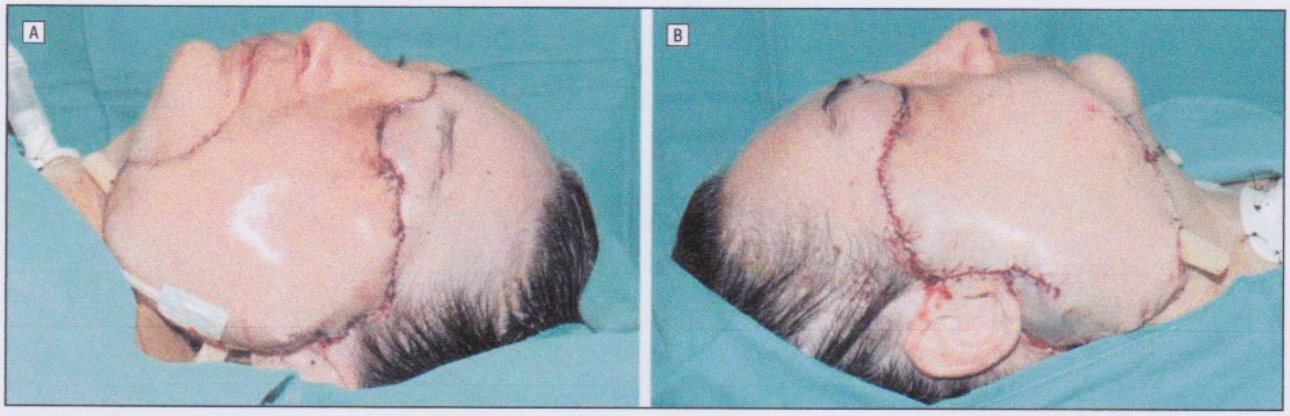

Figure 9. Immediate postoperative photographs. Frontolateral (A) and lateral (B) views of the allograft at the conclusion of the surgery.

Figure 10. Seven-month follow-up photographs of the patient. Standard frontal (A), lateral (B and C), and three-quarter images (D and E) are shown.

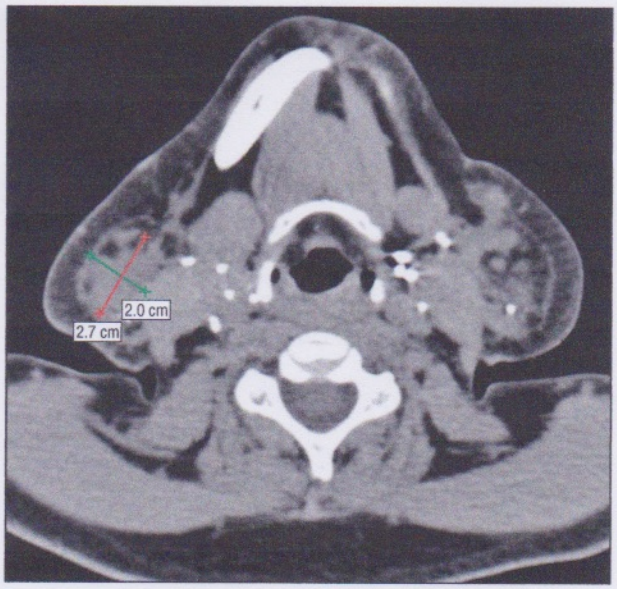

Figure 11. Postoperative axial computed tomographic scan at 5 months. Excess glandular bulk is seen and labeled.

the right was the IJ vein because the external jugular was noted to be thrombosed.

The facial nerve neurorrhaphy was then undertaken with a fascicular graft of the donor hypoglossal acting as an interpositional bridge between the recipient upper division and the donor main trunk on the left side and donor vagus nerve on the right side. This was done with a standard epineural repair with an end-side neurorrhaphy to the recipient facial nerve outflow tract. After this was completed bilaterally, a layered closure was undertaken from deep to superficial. The oral mucosa was approximated, followed by the orbicularis oris and oculi muscles. Finally, the subcutaneous and skin closures were performed. A diagrammatic illustration of the complete inset is shown in **Figure 8** (video 2).

SURGICAL OUTCOME AND FUTURE PROCEDURES

The patient had an uneventful postoperative course and has had no surgical complications to date. The immediate postoperative results are shown in **Figure 9**, and the 7-month follow-up images are shown in **Figure 10**. The

Figure 12. Potential final outcome after completing future debulking procedure. The present outcome is shown schematically (A) and photographically (B), and the potential final outcome after debulking is shown schematically (C) and as an artist-rendered photographic modification (D) to the final intended outcome. (Reprinted with permission, Cleveland Clinic Center for Medical Art & Photography © 2009. All Rights Reserved.)

donor allograft has shown complete integration into the recipient face along the suture lines. With resolution of the postoperative swelling, the residual redundant glandular tissues have become more apparent in the lateral facial region. The majority of the bulk in this area is this redundant glandular tissue, as shown in the postoperative computed tomographic scan of the patient in **Figure 11**.

The patient has tolerated her immunosuppressive regimen well and has been weaned appropriately. Her initial treatment regimen included thymoglobulin for induction, and standard triple-therapy including tacrolimus, mycophenolate mofetil, and prednisone. She has had 1 episode of presumed acute rejection (Banff III/IV) identified on a routine mucosal biopsy but not seen on skin biopsy or clinical examination. This resolved before the

planned single dose of Solu-Medrol (methylprednisolone sodium succinate) was given to the patient.

Beyond the structural benefit, the patient has obtained significant functional benefits from the procedure. She is able to breathe through her nose and has regained her sense of smell and taste. She is no longer tracheotomy dependent and has been decannulated. She is able to eat by mouth and has had significant improvement in her speech. Sensory and motor recovery is progressing appropriately but will require time to further evaluate final outcomes.

The planned removal of the redundant glandular tissue will be performed in late 2009 after the facial nerve function returns and the nerve can be stimulated and therefore traced safely. A potential final outcome is shown in **Figure 12**.

COMMENT

The concept of facial transplantation has become a reality with 7 successful procedures at the time of this report. With many other institutions interested in performing this procedure, the number of cases will likely increase in the future, and if the promising initial results continue, the operation may become standard of care for extensive facial injuries. In this report we discuss the surgical procedure and outcomes of a human near-total face and maxilla transplant. While many common elements exist in our case and the ones performed previously, there are a number of distinctions worth noting. The inclusion of the maxilla based on the facial arterial system represents a first attempt, and the feasibility of this has not been previously shown clinically. The importance of transferring facial bone to incorporate important facial ligaments and prevent ptosis of the donor flap is an important anatomical concept that is becoming clear as the initial transplant cases are followed up further from their surgery. These patients have needed suspension and/or lift revisions to keep the facial tissues elevated. The need for these procedures may be greatly obviated by including the bony attachments of the cutaneous ligaments. On the basis of our findings, we believe that this may be feasible with the facial arterial arcade alone. While this is a notable distinction, it may not be the clinically most important one. Unlike the other transplants performed to this point, this patient had undergone multiple failed prior reconstructions and had significant recipient vascular depletion. This raises the important potential role of facial transplant as a salvage procedure in cases in which other options are unavailable and/or suboptimal. As with any novel surgical innovation, information gathered in the nascent stages of the procedure will be vital to define the indications and appropriate patient selection. Our findings will hopefully contribute to this active discussion.

Accepted for Publication: July 30, 2009.
Correspondence: Daniel S. Alam, MD, The Cleveland Clinic Foundation, 9500 Euclid Ave, Desk A71, Cleveland, OH 44195 (alamd@ccf.org).
Author Contributions: *Study concept and design:* Alam, Djohan, Bernard, and Siemionow. *Acquisition of data:* Alam, Djohan, Lohman, Gordon, and Hendrickson. *Analysis and interpretation of data:* Alam, Papay, and Gordon. *Drafting of the manuscript:* Alam, Djohan, and Gordon. *Critical revision of the manuscript for important intellectual content:* Alam, Papay, Bernard, Lohman, Gordon, Hendrickson, and Siemionow. *Statistical analysis:* Alam. *Administrative, technical, and material support:* Alam, Papay, and Gordon. *Study supervision:* Alam and Siemionow.
Financial Disclosure: None reported.
Additional Information: Two videos are available at http://www.archfacial.com.

REFERENCES

1. Siemionow M, Papay F, Alam D, et al. Near-total human face transplantation for a severely disfigured patient in the USA. *Lancet.* 2009;374(9685):203-209.
2. Devauchelle B, Badet L, Lengelé B, et al. First human face allograft: early report. *Lancet.* 2006;368(9531):203-209.
3. Lantieri L, Meningaud JP, Grimbert P, et al. Repair of the lower and middle parts of the face by composite tissue allotransplantation in a patient with massive plexiform neurofibroma: a 1-year follow-up study. *Lancet.* 2008;372(9639):639-645.
4. Guo S, Han Y, Zhang X, et al. Human facial allotransplantation: a 2-year follow-up study. *Lancet.* 2008;372(9639):631-638.
5. Banks ND, Hui-Chou HG, Tripathi S, et al. An anatomical study of external carotid artery vascular territories in face and midface flaps for transplantation. *Plast Reconstr Surg.* 2009;123(6):1677-1687.
6. Yazici I, Carnevale K, Klimczak A, Siemionow M. A new rat model of maxilla allotransplantation. *Ann Plast Surg.* 2007;58(3):338-344.
7. Yazici I, Cavusoglu T, Comert A, et al. Maxilla allograft for transplantation: an anatomical study. *Ann Plast Surg.* 2008;61(1):105-113.
8. Siemionow M, Papay F, Kulahci Y, et al. Coronal-posterior approach for face/scalp flap harvesting in preparation for face transplantation. *J Reconstr Microsurg.* 2006;22(6):399-405.
9. Banks ND, Hui-Chou HG, Tripathi S, et al. An anatomical study of external carotid artery vascular territories in face and midface flaps for transplantation. *Plast Reconstr Surg.* 2009;123(6):1677-1687.
10. Baccarani A, Follmar KE, Baumeister SP, Marcus JR, Erdmann D, Levin LS. Technical and anatomical considerations of face harvest in face transplantation. *Ann Plast Surg.* 2006;57(5):483-488.