
A Convenient and Efficient Moldable Dressing for Skin Grafts

Yadranko Ducic, MD, FRCS(C); Peter A. Hilger, MD, FACS; Frederick S. Fish, MD, FACP;
Andrew J. Bartlett, MD, FRCS(C)

In this paper we present our positive experience with use of Aquaplast thermoplastic as a tie-down dressing for securing and maintaining skin grafts in good position against their nutrient recipient beds. This unique polymer is safe to use, simple to apply, and maintains uniform pressure across the entire surface of the skin graft, no matter how contoured the shape of the anatomical region.

Laryngoscope, 107:954-956, 1997

INTRODUCTION

Skin grafts, whether split thickness or full thickness, form an integral part of the reconstructive armamentarium available to surgeons. They provide coverage of defects when use of local flaps would pose significant deleterious effects on tissue surrounding the donor site, and are important in prevention of adverse wound contracture. Graft survival depends on numerous factors. The most important factor affecting outcome is the ability of the host defect to neovascularize the applied skin graft through the process of vessel ingrowth.¹ Strict immobilization of the graft during this period of revascularization is critical in determining whether the graft will survive or fail, as the newly formed nourishing vasculature consists of fragile tangles of blood vessels that find it difficult to anastomose with a moving target.^{1,2} Furthermore, it is critical to note that newly applied skin grafts have a relatively narrow range of tolerance to the moisture content of their environment. They tolerate both maceration (from excess moisture) and desiccation (from inadequate moisture) poorly.

A variety of different dressing materials have been used to provide coverage of skin grafts in the immediate postoperative period until neovascularization was well underway.^{3,4} Gauze, cotton, and sponge are among the many materials that have been used for this purpose. These dressing materials were all secured in a bolster-type manner to firmly approximate the graft to the recipient site. All of these dressing materials suffer major drawbacks in certain surgical situations. The bolster-type dressings lack the ability to precisely contour to the curved and irregular surfaces found in areas such as the auricle and nose. This may result in uneven distribution of pressure over the skin graft, which may encourage micromotion and, consequently, contribute to partial graft failure. The graft may also become malaligned because of the contour of the bolster. Moreover, placing a bulky dressing over a fresh graft inhibits drainage from the graft site that may occasionally lead to maceration of the transferred tissue with subsequent deleterious effects. Traditional bolster dressings may further result in elevation of the margins of the recipient site, resulting in the formation of a noticeable, unattractive mound at the junction of the graft and the surrounding wound margin. This mound may resolve over weeks or may persist indefinitely. Finally, bolster-type dressings often appear esthetically displeasing, especially toward the end of their utilization period.

In this paper, we describe our positive experience using Aquaplast thermoplastic (Aquaplast Corp., Wyckoff, NJ) as a bolster-type dressing for maintaining excellent approximation of skin grafts to their recipient beds. Aquaplast thermoplastic is a unique plastic polymer that softens and becomes transparent when warmed in excess of 140°F, thus allowing for an increase in its inherent malleability. This facilitates precise in situ molding. As the temperature of the polymer approaches that of ambient room temperature, it becomes progressively less flexible. As it

From the Division of Facial Plastic and Reconstructive Surgery in the Departments of Otolaryngology (Y.D., P.A.H., A.J.B.) and Dermatology (F.S.F.), University of Minnesota, St. Paul, Minnesota.

Editor's Note: This Manuscript was accepted for publication February 5, 1997.

Send Correspondence to Dr. Y. Ducic, 2285 Stewart Avenue #2209, St. Paul, MN 55116, U.S.A.

loses its malleability, it maintains the integrity of the shape to which it was molded when warmed. This property enables Aquaplast thermoplastic to accurately conform to almost any surgical defect, no matter how convoluted it may be. Such complete duplication of defect morphology allows for exquisitely precise apposition of skin grafts against even the irregularly contoured surgical defects found in the nose and ear. If required, this plastic polymer may be reheated and reshaped several times with little difficulty. It is available in sizes from $\frac{1}{16}$ to $\frac{3}{16}$ of an inch and is marketed in many different colors, including a flesh-toned variety. We routinely use the ivory-colored variety. Gas sterilization is not recommended as gas molecules may become adherent to the material, altering its characteristics. Instead, it may be sterilized by soaking it in an antibacterial solution, such as Cidex (Surgilcos, Johnson and Johnson, New Brunswick, NJ). Aquaplast thermoplastic is also relatively inexpensive, and is widely available, being primarily used in the creation of contoured splints following rhinoplasty.

We have used Aquaplast thermoplastic in more than 100 cases since our first report on the possible use of this material as a dressing for skin grafts.⁵ We have used it to help secure both partial and full thickness skin grafts in reconstruction of various head and neck defects. The majority of surgical defects represented the sequelae of Moh's micrographic excision of cutaneous carcinomas. The most frequently noted defect site was the nose (70% of total cases). Previously, with the use of bolster dressings, we often noted partial loss of the skin graft at one or more edges. This is infrequently noted with the use of our moldable dressing technique. Graft sizes have varied from less than 1 cm for nasal tip reconstruction, to more than 15 cm in length for forehead resurfacing. Both split thickness and thinned full thickness skin grafts have been secured in this manner. We have noted no complications from its use and have found it appropriate to use throughout the head and neck. Patients with an allergic sensitivity to Aquaplast or plastic should, of course, have alternate means of fixation of their skin grafts. We have yet to encounter this situation.

TECHNIQUE

After careful and thoughtful analysis of a surgical defect, one may conclude that the area is best rehabilitated by application of a skin graft. Full thickness skin grafts are harvested from an area with similar color, texture, and sebaceous features as the defect skin. Full thickness skin grafts should be thinned and precisely trimmed to size to accurately cover the defect.⁶ When areas of significant size need to be skin grafted, full thickness grafts are no longer an option. In this instance, one must consider resurfacing the surgical bed with a split thickness graft. In either case, the edges of the graft are su-

tured in place with 5-0 or 6-0 interrupted absorbable suture, such as chromic or plain gut. Additional basting sutures may be required in instances where larger grafts are being used. After completing the graft inset, one may proceed with the dressing. We routinely apply a thin film of antibiotic ointment to the graft surface. This is then covered with a thin layer of a nonadherent material, such as vaseline gauze, telfa, adaptic, etc. At this point, a sterile piece of Aquaplast thermoplastic, slightly larger in size than the defect, is heated in water that has been brought to a boil. As noted, the polymer becomes transparent as it is heated, signifying an incremental increase in malleability. After allowing for excess water to run off and waiting a few seconds for the polymer to cool to a temperature allowing for easy handling by the surgeon and painless application onto the patient, the Aquaplast is accurately molded in situ over the graft. As it cools further, this molded shape is firmly maintained to mirror any defect contours. Next, the Aquaplast should be trimmed in such a way as to have a margin of at least $\frac{1}{8}$ to $\frac{1}{4}$

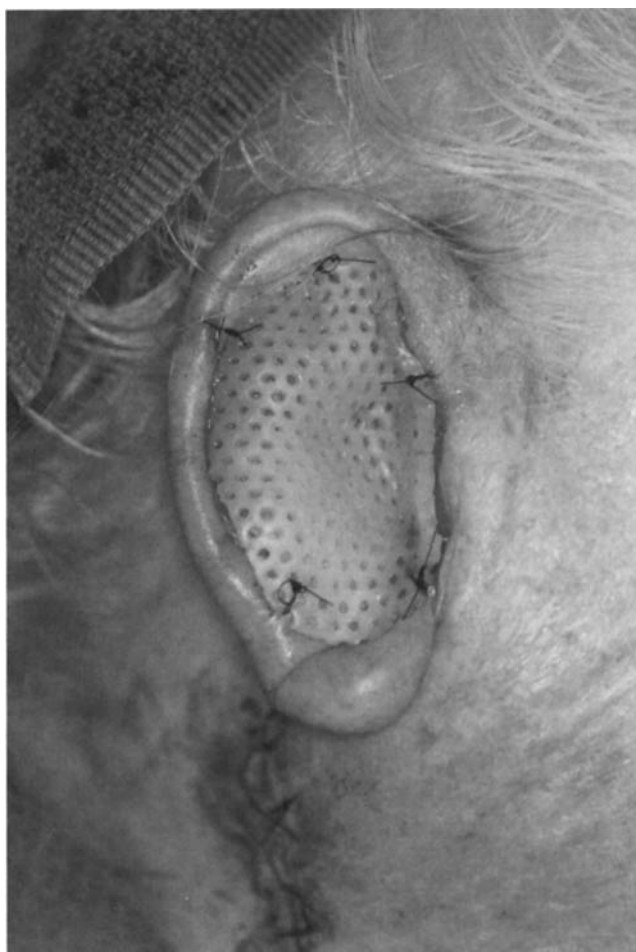


Fig. 1. Aquaplast thermoplastic dressing precisely molded and secured in position over conchal bowl area defect resulting from Moh's micrographic excision of a sclerosing basal cell carcinoma.

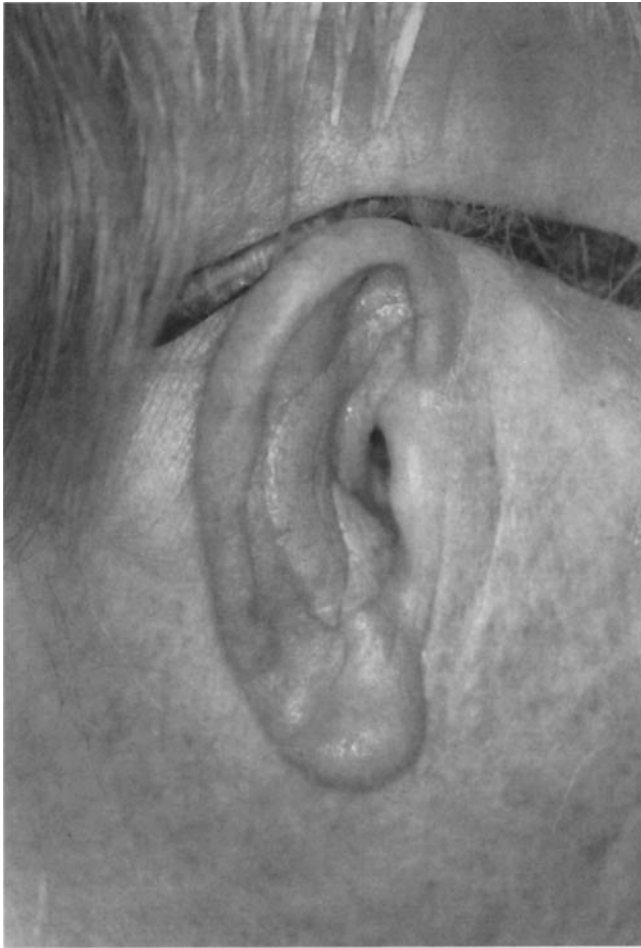

Fig. 2. Appearance of skin graft 3 months after application. Same patient as in Figure 1.

of an inch extending beyond the graft edge. This excess represents a safety factor, allowing one to secure the Aquaplast to the skin immediately surrounding the graft, without inadvertently placing sutures through the graft bed that might lead to vessel damage and possible hemorrhage beneath the graft. The Aquaplast is secured in position using either 4-0 or 5-0 nonabsorbable suture, such as nylon (Figs. 1 and 2). If Aquaplast is being used to cover a skin graft applied to a large area, such as the scalp, it may be secured in place quickly with the use of staples. The porous nature of the

Aquaplast allows for any excess drainage from the graft site to pass through it with little difficulty, yet the antibiotic ointment and thin layer of nonadherent dressing (telfa, etc.) prevent tissue desiccation. The extension of the Aquaplast beyond the graft margins avoids elevation of the graft margin.

The above-described dressing should be left in place for 5 to 7 days depending, of course, on the location and size of the graft. Removal of the dressing is simple and painless. Interestingly, at the time of dressing removal, one can appreciate the uniform pressure applied on the graft by the dressing. One can note the even distribution of the impression left by the dressing on both the graft and the surrounding wound edge.

CONCLUSION

In applications of the Aquaplast thermoplastic as a dressing for skin grafts in reconstruction of head and neck cutaneous defects, we have experienced no untoward effects in terms of graft survival or final graft appearance. This dressing material provides for an efficient and effective approximation of skin grafts to their recipient beds, no matter how contoured or irregular they may be. Graft survival may be enhanced by the more precise and consistent graft adhesion thus achieved. Application of the Aquaplast thermoplastic takes approximately one-half the time it would take to apply a standard bolster-type dressing. Patient acceptance of this dressing is high, both in terms of comfort and esthetic appeal.

BIBLIOGRAPHY

1. Converse JM, Smahol J, Ballentyne DL, Harper AD. Inosculation of vessels of skin graft and host bed: a fortuitous encounter. *Br J Plast Surg* 1975;28:282-6.
2. Hill TG. Enhancing the survival of full thickness grafts. *J Dermatol Surg Oncol* 1984;10:639-42.
3. Peled IJ, Wexler MR. Designing and dressing of skin grafts by means of patterns on sponges of polyurethane. *J Dermatol Surg Oncol* 1987;7:664-5.
4. Salasche SJ, Feldman BD. Skin grafting: the perioperative technique and management. *J Dermatol Surg Oncol* 1987; 13:863-9.
5. Fish FS, Hilger PA. Aquaplast thermoplastic. *J Dermatol Surg Oncol* 1994;20:239-44.
6. Hill TG. Contouring of donor full thickness skin grafting. *J Dermatol Surg Oncol* 1987;13:883-8.