
CASE REPORT

James I. Cohen, MD, PhD, *Section Editor*

A LOGICAL APPROACH TO THE THORACIC INLET: THE DARTEVELLE APPROACH REVISITED

Yadranko Ducic, MD, FRCS(C),¹ Andre Crepeau, MD, FRCS(C),²
Laura Ducic, BSc,³ Andre Lamothe, MD, FRCS(C),⁴
Martin Corsten, MD, FRCS(C)⁴

¹ Department of Otolaryngology-Head and Neck Surgery at the University of Texas SouthWestern Medical Center at Dallas and the Division of Otolaryngology and Facial Plastic Surgery at John Peter Smith Hospital in Fort Worth, Texas

² Department of Thoracic Surgery, Ottawa General Hospital, University of Ottawa, Ottawa, Canada

³ Department of Epidemiology, Ottawa General Hospital, University of Ottawa, Ottawa, Canada

⁴ Department of Otolaryngology, Ottawa General Hospital, University of Ottawa, Ottawa, Canada

Accepted 16 February 1999

Abstract: *Background.* Traditionally, Pancoast tumors have been associated with an extremely poor outlook. Recently, Darteville and colleagues have noted a significant survival advantage in patients treated by wide en bloc excision.

Methods. Utilizing an illustrative case example, step by step exposure of the lung apex and first rib is provided with the Darteville approach.

Results. Safe exposure was provided by this combined trans-cervical and transthoracic approach.

Conclusions. The Darteville approach appears to be the favored approach to anterior lung apex or first rib lesions. The combined efforts of an Otolaryngologist-Head and Neck Surgeon and a Thoracic Surgeon may allow for safe, wide en bloc excision of these otherwise difficult to access lesions. © 1999 John Wiley & Sons, Inc. *Head Neck* 21: 767-771, 1999.

Keywords: Pancoast syndrome; thoracic inlet; Darteville approach

Correspondence to: Y. Ducic, director, Division of Otolaryngology and Facial Plastic Surgery, John Peter Smith Hospital, 1500 South Main Street, Fort Worth, TX 76104.

CCC 1043-3074/99/080767-05
© 1999 John Wiley & Sons, Inc.

In 1932 Tobias outlined the clinical presentation of apical lung carcinomas and termed it apico-costo-vertebral syndrome.¹ Despite Tobias' initial identification, the currently accepted name of this syndrome is Pancoast syndrome, named for Henry K. Pancoast after his detailed presentation to the American Medical Association in the same year.²

Located within the narrow confines of the thoracic inlet, apical lung carcinomas have a significant tendency to directly involve the lower roots of the brachial plexus, intercostal nerves, stellate ganglion, sympathetic chain, adjacent ribs, and occasionally, vertebrae. Thus, these neoplasms often present with localized pain, Horner's syndrome, destruction of the first rib, and atrophy of hand muscles.² Histologically, squamous cell carcinomas are the most commonly found neoplasms in this location, with adenocarcinomas and small cell neoplasms occurring much less frequently.³

Prior to the 1960s, survival expectations for

those with Pancoast syndrome were dismal. For the most part, irradiation was considered to be the only effective treatment modality, until the early 1960s, when Shaw combined radiotherapy with extensive resection and found a dramatic improvement in survival rates.⁴

Currently, there are two major surgical techniques used for the resection of neoplasms specific to Pancoast syndrome: the Paulson operation and the more direct approach described by Darteville.⁵⁻⁷ The employment of these techniques, however, varies with the specific location of the neoplasm. Specifically, it is important to classify superior sulcus neoplasms as being either predominantly anterior, predominantly posterior, or spanning the entire thoracic inlet.

For predominantly posterior superior sulcus neoplasms, the classic Paulson operation (extended posterolateral thoracotomy) is most effective.^{5,6} However, a major limitation of the Paulson operation, and other posterior approaches, is the limited exposure and precarious control of vital anterior thoracic inlet neurovascular structures, when dissection is required more anteriorly.

Recently, Darteville and associates described a novel direct approach to anterior apical lung lesions.⁷ Their overall 2- and 5-year survivals of 50% and 31% are quite remarkable, given the otherwise poor outlook for these patients.⁷ This direct approach is also used to gain superior surgical exposure to first rib lesions. Moreover, one may combine the direct approach with the Paulson operation, for more extensive lesions spanning the thoracic inlet from anterior to posterior.

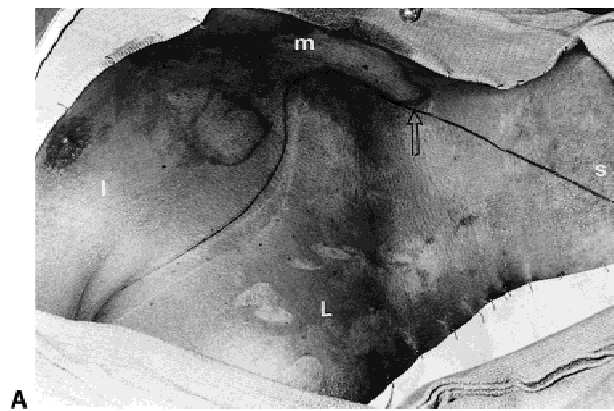
In this article, we present a review of the anterior cervicothoracic approach using an illustrative case report. Since the anterior approach involves extensive cervical and thoracic dissection, the traditional boundaries between head and neck surgery and thoracic surgery are traversed. Therefore, the surgery was conducted using a team approach.

CASE REPORT

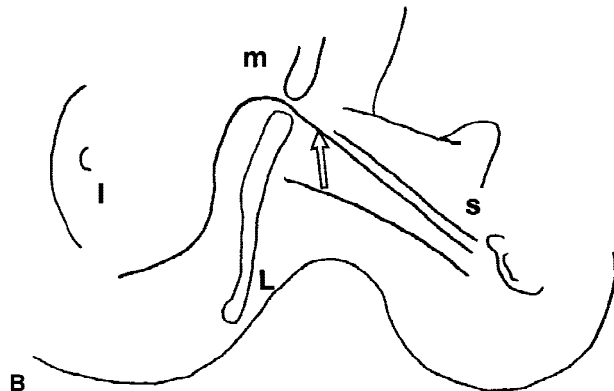
Clinical Presentation and Investigations. A 29-year-old auto mechanic with a significant history of poststreptococcal glomerulonephritis-induced renal failure necessitating regular hemodialysis, was first seen with a 4-month history of progressive left shoulder and anterior chest wall discomfort associated with fullness and tenderness below his left clavicle. No paresthesia or weakness

in his upper limbs was reported by the patient. Other than for a palpable fullness deep and inferior to the left clavicle, the physical examination was unremarkable. Investigations included a CT scan, which revealed the presence of a calcified 4-cm lesion arising from the posterior aspect of the first rib on the left side. MRI scan confirmed the CT findings. It also showed that the lesion was not invading the major vessels of the thoracic inlet or the brachial plexus. Aortogram and left subclavian arteriogram were reported to be normal. Somatosensory evoked potentials of the left upper limb were likewise normal, thus reducing the patient's risk of having subclinical involvement of the brachial plexus. Bone scan revealed that the first rib lesion was the only significant site of increased uptake in the body. Given the lesion's solitary nature, radiographic appearance and its progressive rapid increase in size and discomfort, the possibility of a low grade chondrosarcoma was entertained. The patient thus underwent a cervicothoracic approach to diagnose and extirpate the lesion.

Procedure. The patient was placed in the supine position with head turned to the right. Prepping included the neck and entire chest. Bronchoscopy was performed to facilitate the insertion of a left-sided bronchial blocker. No suspicious endobronchial lesions were noted. An L-shaped incision was designed to pass from the mastoid to the sternal notch, with the horizontal limb passing under the medial one half of the clavicle (Figure 1A and B). The sternocleidomastoid muscle was detached from its sternal and clavicular attachments and the posterior belly of the omohyoid muscle was transected (Figure 2A and B). Subcutaneous blunt dissection allowed the isolation and subsequent sharp detachment of the pectoralis major muscle from the clavicle. Internal and external jugular veins were ligated inferiorly. Posterior triangle dissection was required to define the brachial plexus, phrenic nerve and scalene muscles (Figure 3). At this point in the operation, the thoracic duct was ligated. The inner one half of the clavicle was removed after transecting it with a saw. A Lebsche knife was used to perform a partial left sternectomy, facilitating exposure. The subclavian vein, which had been dissected free, was preserved and retracted superiorly. Its minor tributaries were ligated. The subclavian vein may be resected safely without reconstruction to gain exposure or to provide an adequate margin of resection, if necessary. This was not required in our



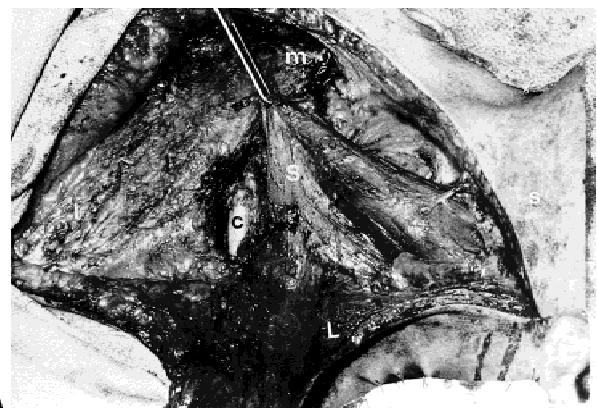
A



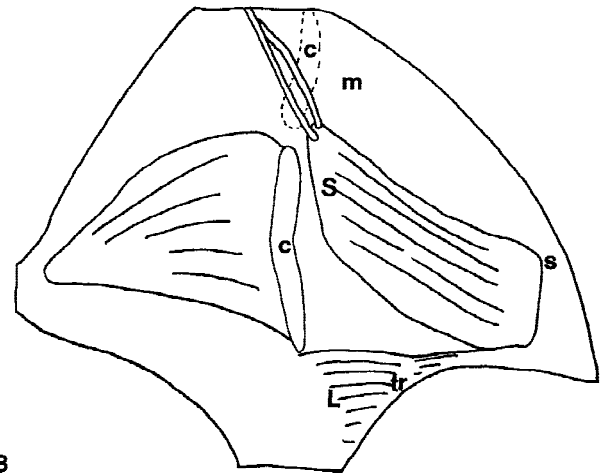
B

FIGURE 1. A and B. Incision for anterior cervicothoracic approach. Open arrow = incision; s = superior; I = inferior; M = medial; L = lateral.

situation. The subclavian or axillary artery may likewise be resected, but require immediate reconstruction with graft to preserve upper limb vascularity and viability.^{7,8} The anterior and middle scalene muscles were now detached from their first rib attachment, and the brachial plexus was gently dissected off of the relevant area. At this point the lesion's extent could be fully and safely gauged. It appeared to be arising from the posterior aspect of the first rib and was noted to be involving the subclavius and first intercostal muscles. The first two ribs, with the attached lesion, were transected and the pleural cavity entered to allow evaluation the lung apex (Figure 4A and B). The apex of the lung was noted to be adherent to the lesion, but did not appear to be otherwise abnormal. A wedge excision of the lung apex was performed in continuity with the main specimen, which was then removed en bloc. Intraoperative pathologic analysis of the specimen could not differentiate between benign calcinosis or a low-grade malignancy. Closure was completed by reattaching the sternocleidomastoid to the remaining sternum and reapproximating the



A



B

FIGURE 2. A and B. Detachment of the sternocleidomastoid muscle (S) from the clavicle (c); tr = trapezius muscle.

pectoralis major and platysma muscles. Chest tube drainage was required, of course, as the pleural cavity had been entered.

Postoperative Course. The patient's postoperative course was quite uneventful. He had excellent range of motion at his left shoulder and no neurologic deficits in his left arm. The patient was quite content with his surgical outcome. Final pathology was consistent with a diagnosis of benign tumoral calcinosis. This is a benign process related to the patient's renal failure and hemodialysis. It requires no further adjunctive therapy.

COMMENT

The anterior cervicothoracic approach, as first described by Darteville and colleagues,⁷ has gained wide acceptance in Europe. It appears ideally suited to providing safe surgical exposure of the first rib and anterior thoracic inlet, and allowing for en bloc excision of tumors of the first rib and lung apex. This area has traditionally been ac-

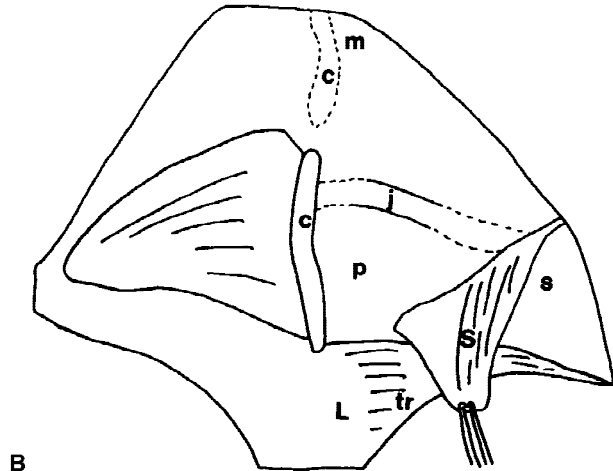
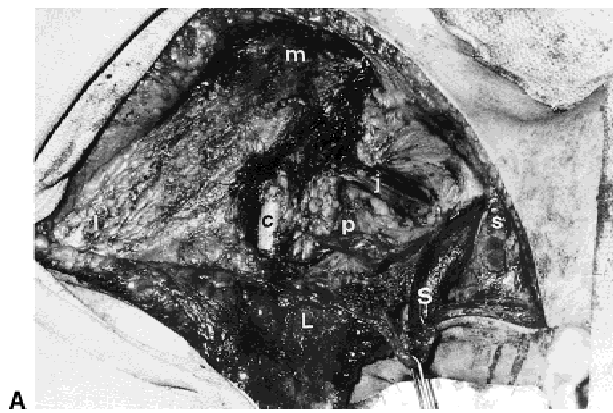


FIGURE 3. A and B. Exposure of the posterior triangle (p) after reflection of sternocleidomastoid muscle superiorly; j = internal jugular vein.

cessed from a more posterior approach, limiting the exposure of vital neurovascular structures and thus the safe and successful extirpation of tumors of the anterior thoracic inlet. As a result of the better exposure afforded by this technique (may combine with a traditional posterior approach for more extensive tumors), surgical outcomes have been quite good for what were previously considered poorly accessible tumors.^{7,9} As stated previously, the predominant tumor type in this location is squamous cell carcinoma.³ This tumor tends to recur locally and thus requires wide en bloc excision if there is to be any hope of cure.⁹ The anterior cervicothoracic approach provides the means for achieving the wide exposure required. Preoperative evidence of brachial plexus invasion is considered a contraindication to surgery, as the long-term prognosis is unlikely to be significantly altered in this circumstance.¹⁰

This approach also facilitates the resection of low jugular lymph nodes or superior mediastinal

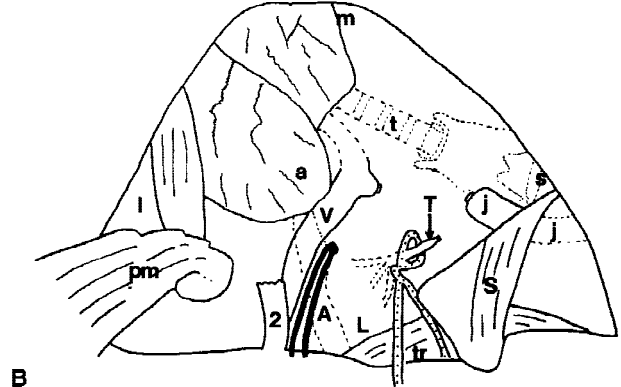
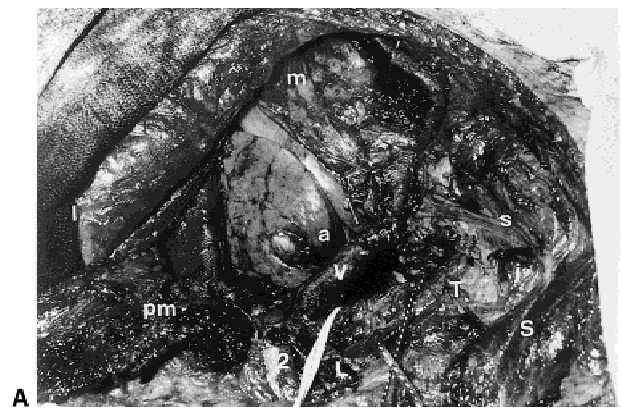


FIGURE 4. A and B. View after removal of the specimen including first rib; V = subclavian vein; a = lung apex; 2 = transected second rib; pm = inferiorly reflected pectoralis major muscle; T = ligated thoracic duct; A = subclavian artery; t = trachea.

lymphadenopathy as part of an extended radical neck dissection in upper aerodigestive tract squamous cell carcinomas with advanced locoregional adenopathy. However, further study is required to examine whether there are indeed any beneficial effects on locoregional recurrence in this patient population as experience with this procedure is gained.

This is not a technically difficult operation to perform. However, it does generally require the cooperative effort of experienced head and neck and thoracic surgeons. Given its growing European acceptance and its emerging North American awareness, the head and neck surgeon will undoubtedly be called on more frequently to assist thoracic surgery colleagues in the surgical approach to anterior thoracic inlet lesions. Likewise, use of this approach may be feasible in unusual instances where the head and neck surgeon needs to extend a posterior triangle dissection inferiorly into the thorax.

Our experience with this procedure was quite positive. We experienced no technical difficulties

and found the safety of the exposure excellent throughout. Cosmesis and postoperative functional status were likewise excellent.

REFERENCES

1. Tobias JW. Síndrome apico-vertebral dolorosa por tumor apical. *Rev Med Lat Am* 1932;14:1522-1606.
2. Pancoast HK. Superior sulcus tumor. *J Am Med Assoc* 1932;99:1391-1395.
3. Paulson DL. Superior sulcus carcinomas. In: *Gibbons surgery of the chest*, 3rd ed. Philadelphia: W.B. Saunders; 1976. p 462-472.
4. Shaw RR, Paulson DL, Kee JL. Treatment of superior sulcus tumors by irradiation followed by resection. *Ann Surg* 1961;154:29.
5. Devirie JW, Meridenhall WM, Million R, Carmichael MT. Carcinoma of the superior pulmonary sulcus treated with surgery and radiation therapy. *Cancer* 1986;57:941.
6. Paulson DL. Carcinoma in the superior pulmonary sulcus. *Ann Thorac Surg* 1979;28:3.
7. Darteville PG, Chapelier AR, Macchiarini P, Lenot B, Cerrine J, Ladurie FLR, Parquin FJF, Lafont D. Anterior transcervical thoracic approach for radical resection of lung tumors invading the thoracic inlet. *J Thorac Cardiovasc Surg* 1993;2:1025-1034.
8. Darteville P, Chapelier AR, Pastorino U. Long-term follow-up after prosthetic replacement of the SVC combined with resection of mediastinal-pulmonary malignant tumors. *J Thorac Cardiovasc Surg* 1991;102:259-265.
9. Macchiarini P, Darteville PG, Chapelier AR, Lenot B, Cerrine J, Ladurie FLR, Parquin FJF. Technique for resecting primary and metastatic nonbronchogenic tumors of the thoracic outlet. *Ann Thorac Surg* 1993;55:611-618.
10. Paulson, DL. Carcinomas in the superior pulmonary sulcus. *J Thorac Cardiovasc Surg* 1975;70:1095-1104.