

## A New Flap for Reliable Nasal Reconstruction

Yadranko Ducic, MD, FRCSC, Peter A. Hilger, MD, FACS,  
and Kurtis Waters, MD

### Abstract

**Objective:** In this article, we describe a new flap for use in lower nasal reconstruction.

**Method:** This technique consists of a planned heminasal transposition rotation flap, with both laterally based and glabellar components. Esthetically favourable incisions are made to follow at the junction between the esthetic subunits.

**Results:** Gratifying early results are achievable, resulting in little postoperative edema due to maintenance of laterally based lymphatic and venous outflow. Likewise, pleasing long-term outcomes have been noted in each of the ten patients in whom we have utilized this flap for nasal reconstruction. Complete flap survival has been noted in every patient.

**Conclusions:** Our experience with the use of this flap technique suggests that it provides consistently rewarding, esthetically pleasing results in patients with cutaneous defects of the lower half of the nose.

### Sommaire

**Objectif:** Dans cet article, nous décrivons un nouveau lambeau pour usage dans la reconstruction nasale basse.

**Méthode:** Il s'agit d'un lambeau planifié héminasal de transposition rotation, avec des composantes basées en latéral mais aussi glabellaires. Des incisions esthétiquement favorables sont faites pour se suivre aux jonctions entre les sous-unités esthétiques.

**Résultats:** Des résultats esthétiques précoces gratifiants peuvent être obtenus, avec un oedème postopératoire subséquent minime secondaire au maintien de l'écoulement veineux et lymphatique qui se fait latéralement. De la même façon, des résultats finaux à long terme satisfaisants ont été notés chez chacun des dix patients chez qui nous avons employé ce lambeau pour la reconstruction nasale. La survie complète du lambeau a été notée chez chaque patient.

**Conclusions:** Nos résultats avec l'usage de cette technique de lambeau atteste sa viabilité dans la reconstruction nasale basse.

**Key words:** heminasal transposition rotation flap, Mohs' surgery, nasal reconstruction

Occupying the central one third of the face, the nose is bordered by the major esthetic subunits. A well-proportioned, esthetically balanced nasal structure should not be incongruous with the rest of the face and become the focus of attention from a casual observer's eye. Instead, ideal nasal form should represent an important part of the facial skeletal framework that provides a harmonious background to the major esthetic highlights of the face, the periorbital and perio-

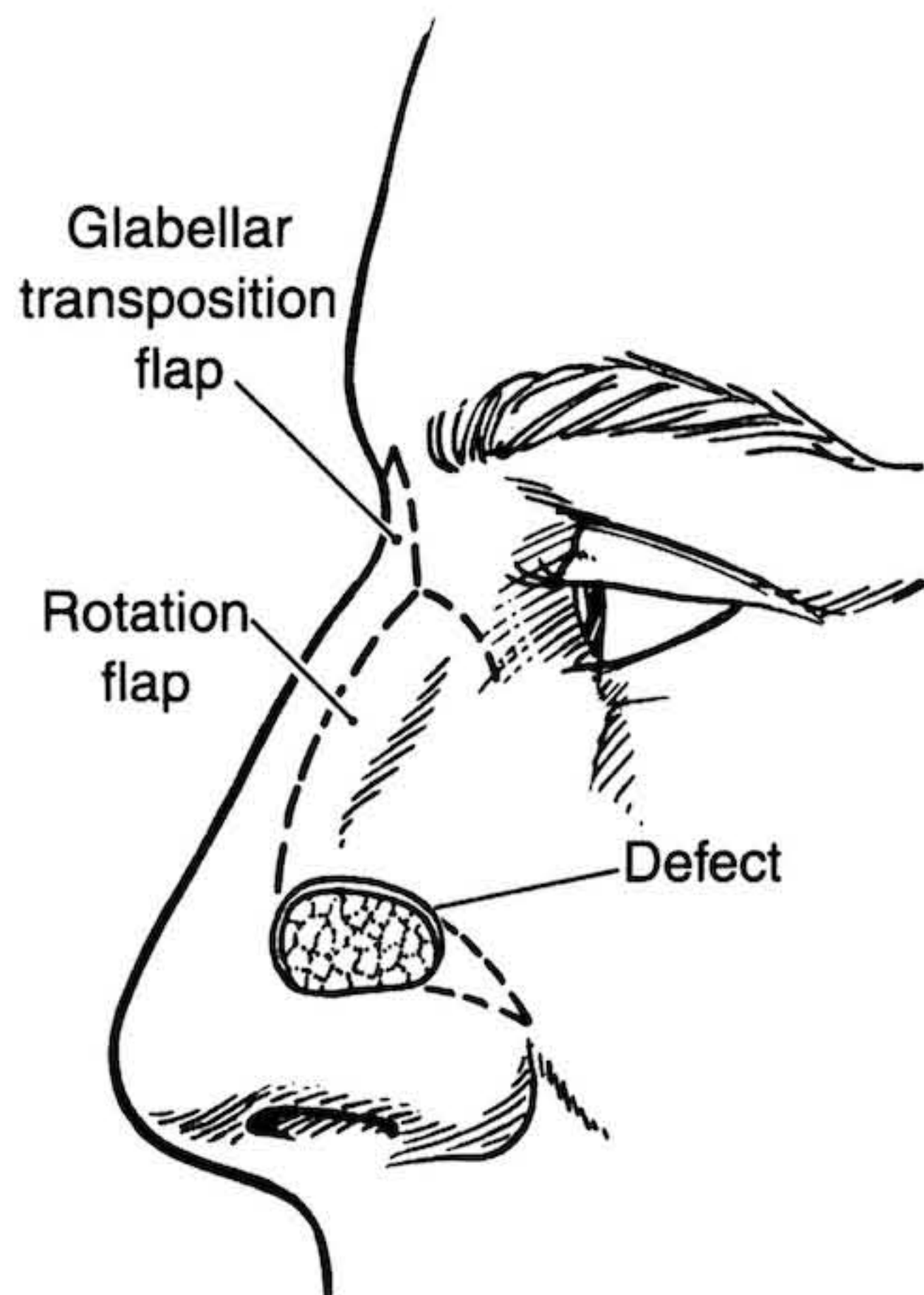
ral areas. Nasal defects, whether due to surgical extirpation of a malignancy or traumatic tissue loss, represent a major divergence from this ideal. Restoration of nasal form and maintenance of nasal function often pose significant challenges to the surgeon faced with reconstruction of such defects.

Application of a single flap for reconstruction of all defects of the nose is obviously not possible. Given the relatively small surface area occupied by the nose, the plethora of local and regional flaps described for its reconstruction reflects its complex structure.<sup>1-12</sup> The nasal skin is noted to differ in colour, elasticity, and texture as one moves through the esthetic subunits of the nose. The skin overlying the bony dorsum is usually thin and pliable, and of a somewhat paler shade than that of the nasal tip area. Here, especially in males, the skin is more sebaceous, tends to be slightly pinker in colour, and is less malleable in many patients. As significant as the differences are between the different areas of the nose, much greater differences are apparent when comparing the nose to the surrounding areas (cheek, upper lip, glabella, eyelids). This would explain why, if

Received 9/1/98. Received revised 7/6/98. Accepted for publication 7/9/98.

*Yadranko Ducic:* Department of Otolaryngology-Head and Neck Surgery, the University of Texas SouthWestern Medical Center, Dallas, Texas, and the Division of Otolaryngology and Facial Plastic and Reconstructive Surgery, John Peter Smith Hospital, Fort Worth, Texas; *Peter A. Hilger and Kurtis Waters:* Department of Otolaryngology-Head and Neck Surgery, the University of Minnesota, Minneapolis, Minnesota.

Address reprint requests to: Dr. Yadranko Ducic, Division of Otolaryngology and Facial Plastic Surgery, John Peter Smith Hospital, 1500 South Main Street, Fort Worth, TX 76104.



**Figure 1** Outline of heminasal transposition rotation flap.

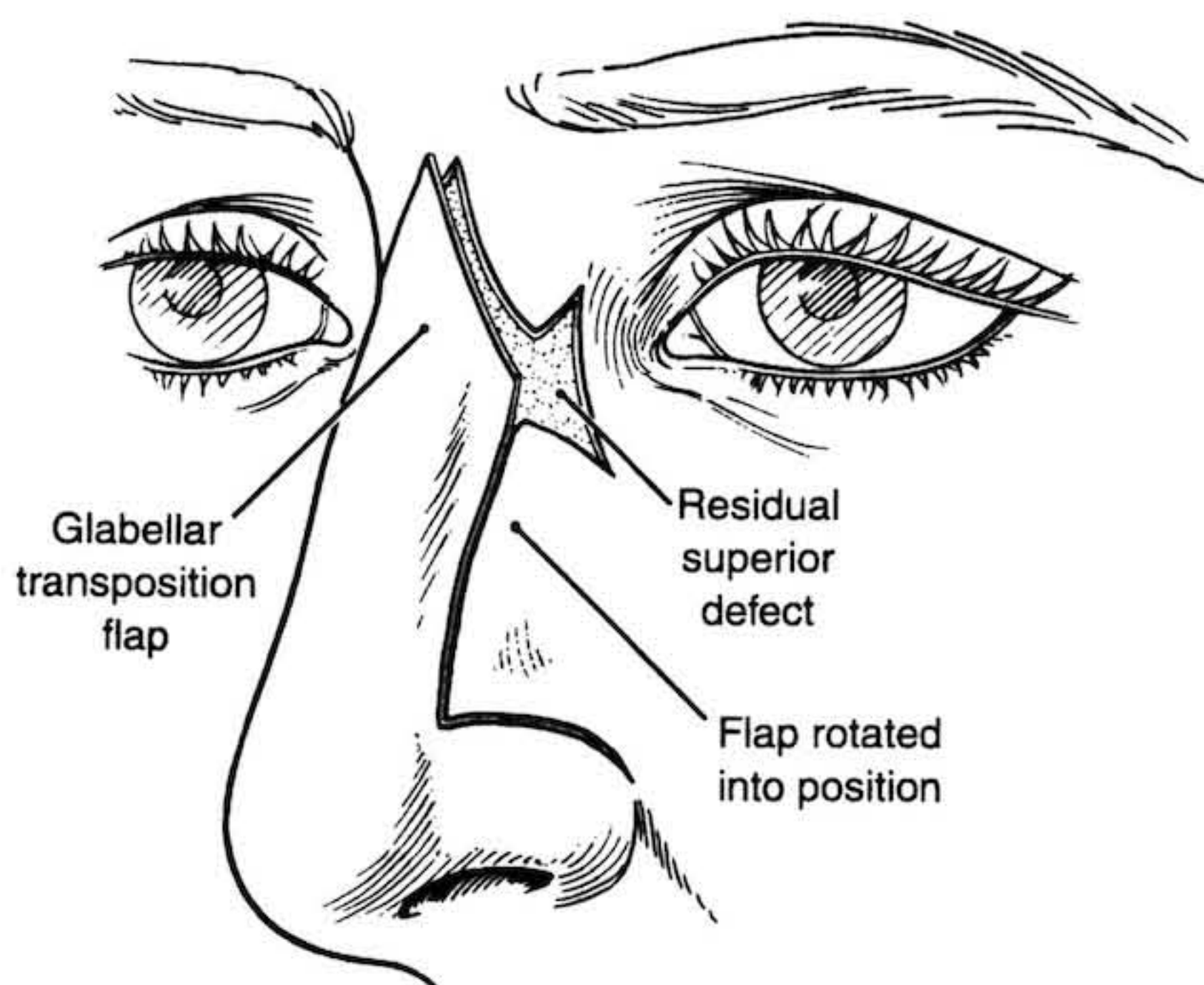
they can be used, adjacent flaps are usually preferable in nasal reconstruction. Healing by secondary intention or skin grafting after surgical excision can result in superior functional and esthetic outcomes in some areas of the nose. However, acceptable outcomes are uncommonly achieved when such techniques are utilized in alar and sidewall reconstruction. They may lead to unacceptable soft-tissue distortion, resulting in esthetic and functional (valvular collapse or stenosis) compromise. Single-stage repair with favourable skin colour, thickness, and texture match is often best achieved by borrowing tissue from one area of the nose to help

reconstitute an adjoining area. In mobilizing tissue, the surgeon should ideally be able to do so without deforming the donor area. The areas of the glabella and nasal dorsum have a relatively greater elasticity to the skin that may be mobilized for lower nasal reconstruction.

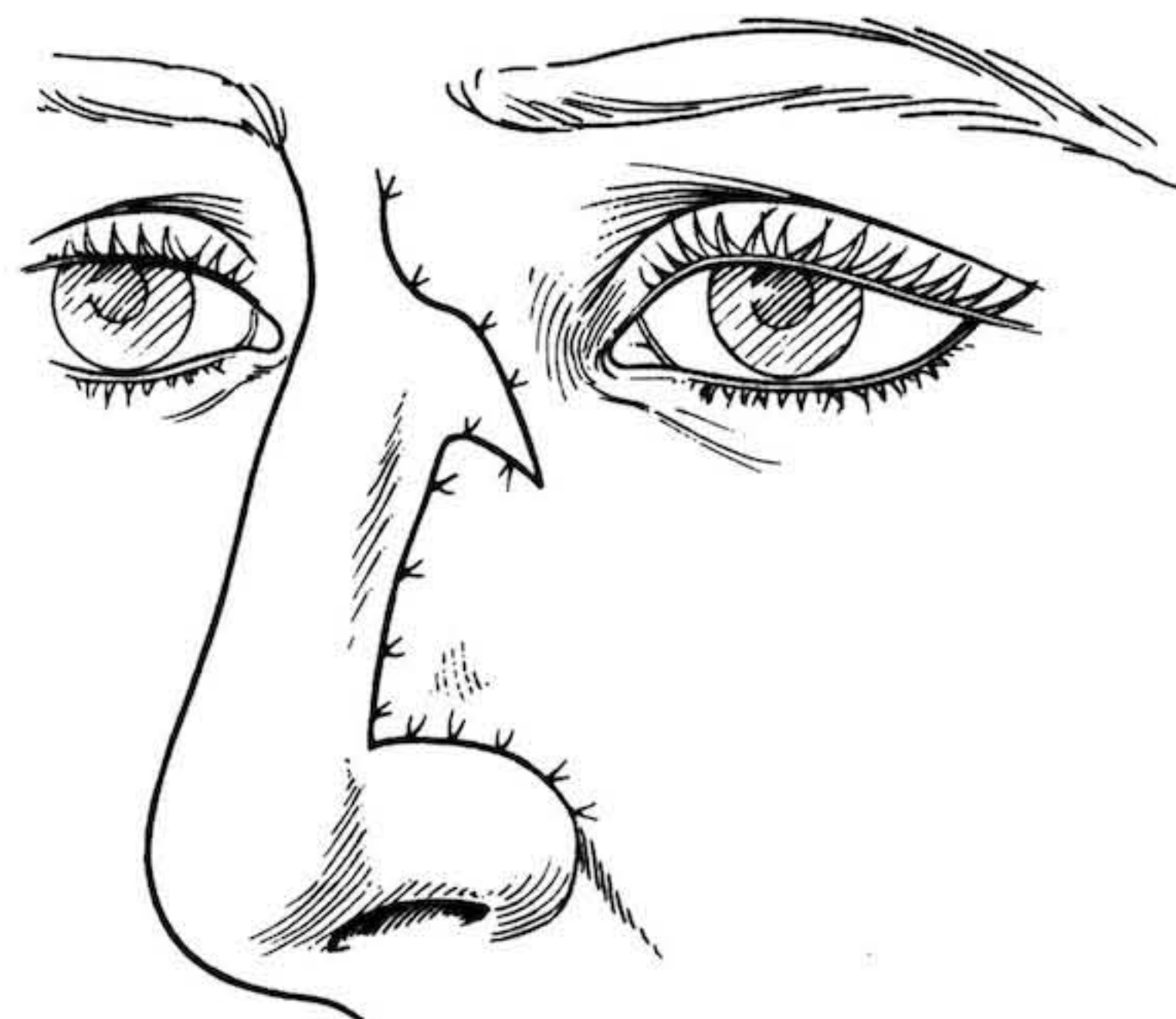In this article, we describe a heminasal transposition rotation flap that we have utilized with good success in the reconstruction of a variety of nasal defects.

### Surgical Technique

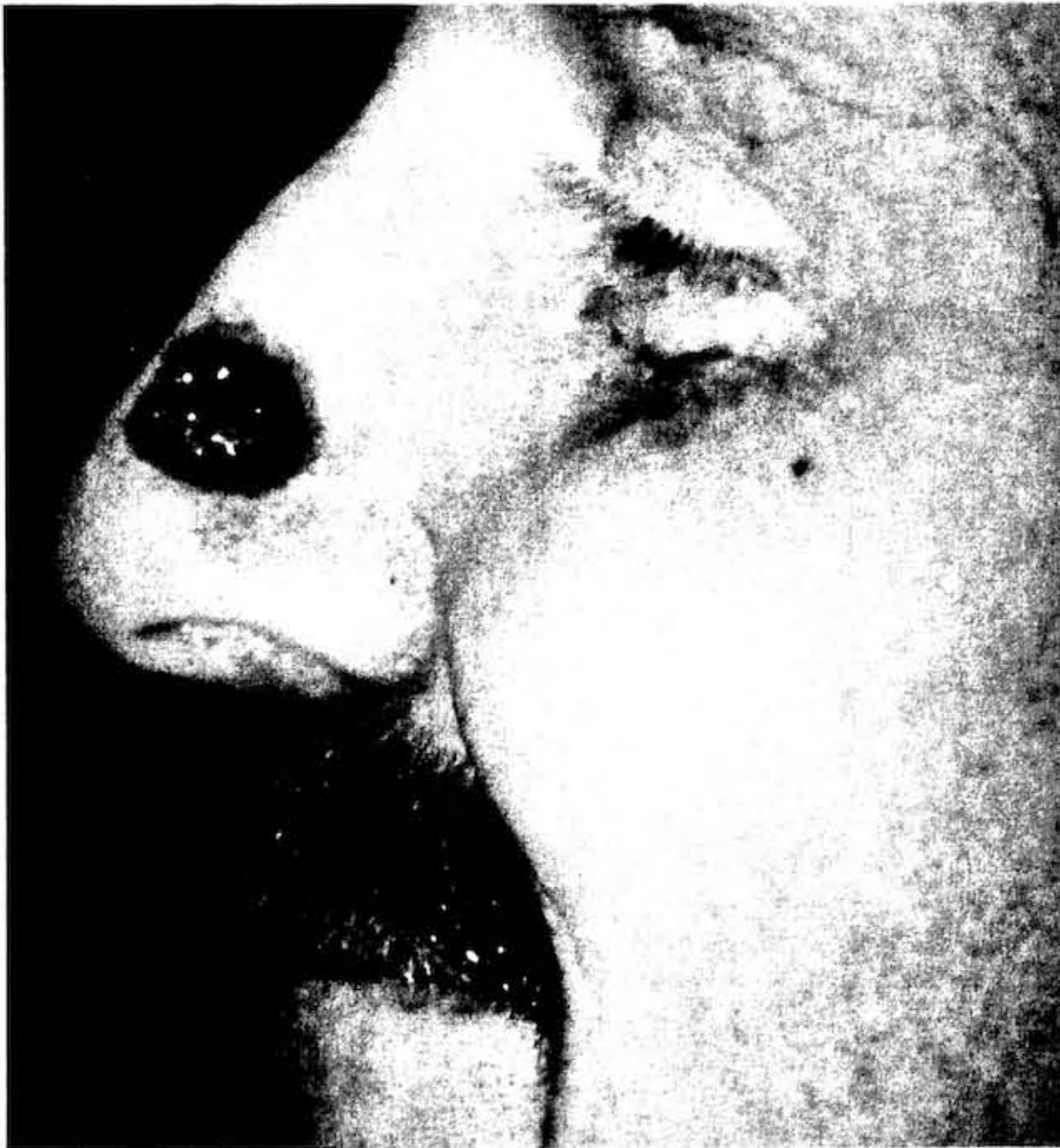The nasal defect is measured and incorporated into the heminasal transposition rotation flap (Fig. 1). A laterally based rotation flap is designed. If possible, the dorsal incision is placed at the junction of the dorsal and lateral nasal sidewall esthetic subunits. Movement of this flap will result in the formation of a standing cutaneous-cone deformity at the inferolateral margin of the defect. This is remedied by a planned excision of this skin redundancy with an incision placed again at the junction of esthetic subunits (alar lobule and lateral nasal sidewall regions) (Fig. 1). The dorsal nasal skin, subcutaneous tissue, and muscle are elevated in a plane just superficial to the perichondrium and periosteum. Minimal, if any, undermining is required in the medial cheek area. A back cut just inferior to the medial canthus is often required, since soft-tissue adherence at the medial canthal tendon area otherwise inhibits flap rotation. Advancement of this now mobilized flap will allow closure of the nasal tip region defect, while creating a residual superior defect. This residual defect may be closed with a planned glabellar transposition flap. Precise technique is required in the formation of this transposition flap to avoid unfavourable tissue retraction that may result in nasal asymmetry or epicanthal fold formation. After transposition of the second flap from the glabella, the glabellar defect is closed as a vertical linear scar (Fig. 2). We uti-



**Figure 2** Elevation of flap to close defect.

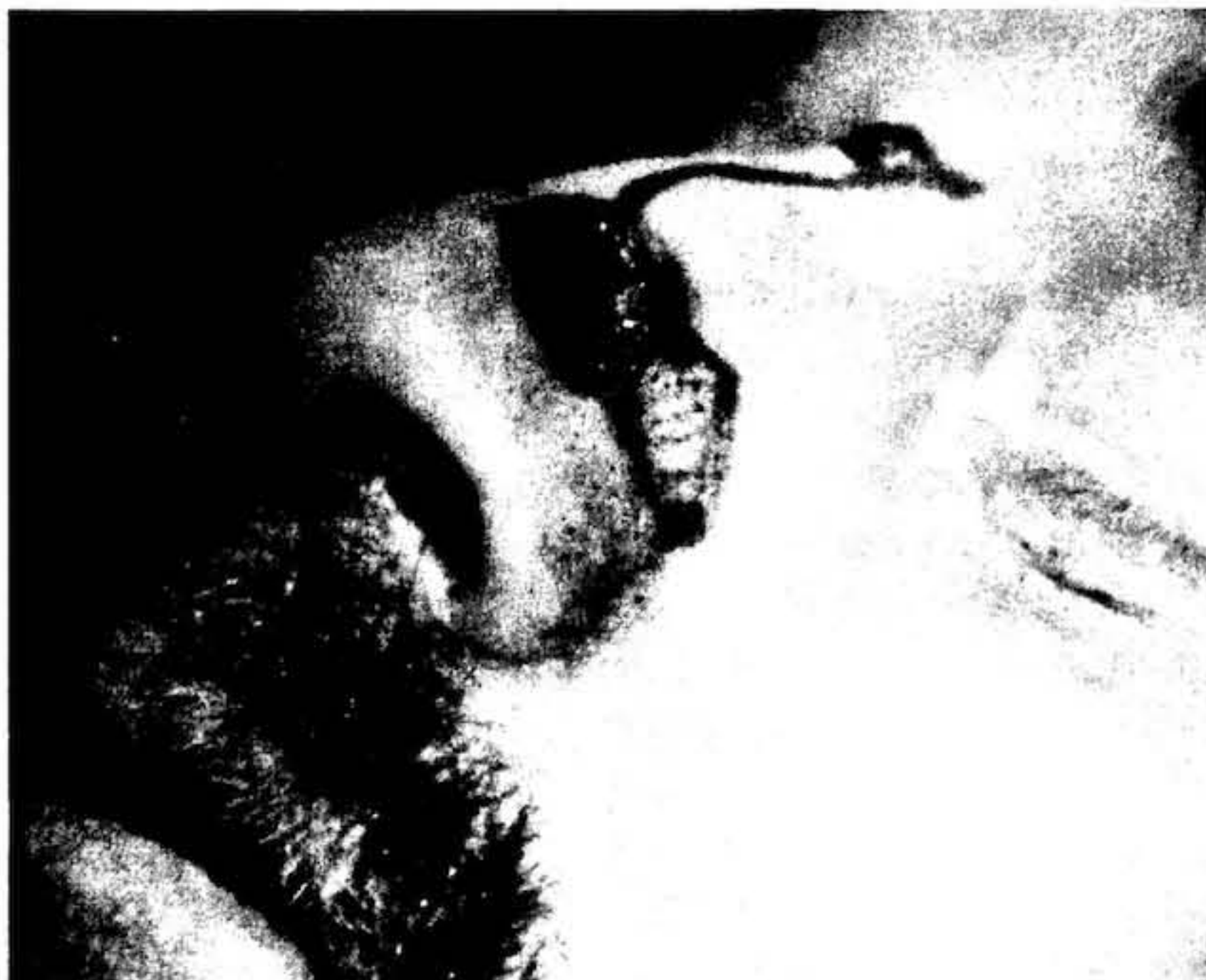

**Figure 3** Defect closure. Note incisions along junctions of esthetic subunits.



**Figure 4** Nasal defect after excision of basal cell carcinoma.

lize a few subcutaneous resorbable sutures to decrease any tension across the incisions, and nonresorbable sutures for skin reapproximation (Fig. 3). These are removed at 5 to 7 days after the procedure. Typically, as for most of our patients requiring flap reconstruction of external nasal defects, we perform early dermabrasion at 6 to 8 weeks following the initial repair. We have found that this provides the patient with a consistently more superior result long term. Carbon dioxide laser resurfacing of these reconstructions may be considered in place of dermabrasion but, in our hands, does not seem to provide as favourable an esthetic outcome in this patient population.

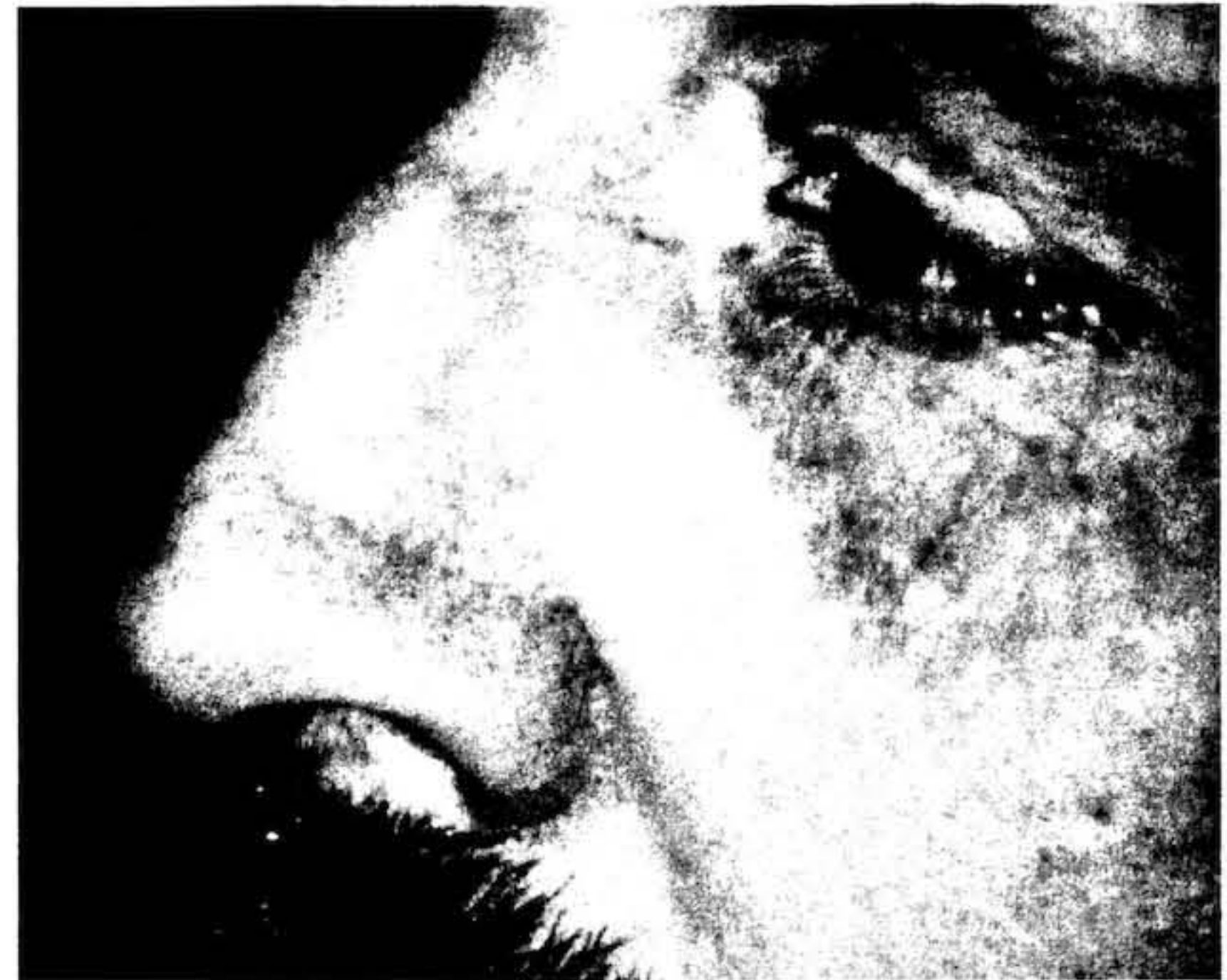

**Figure 5** Intraoperative flap closure.

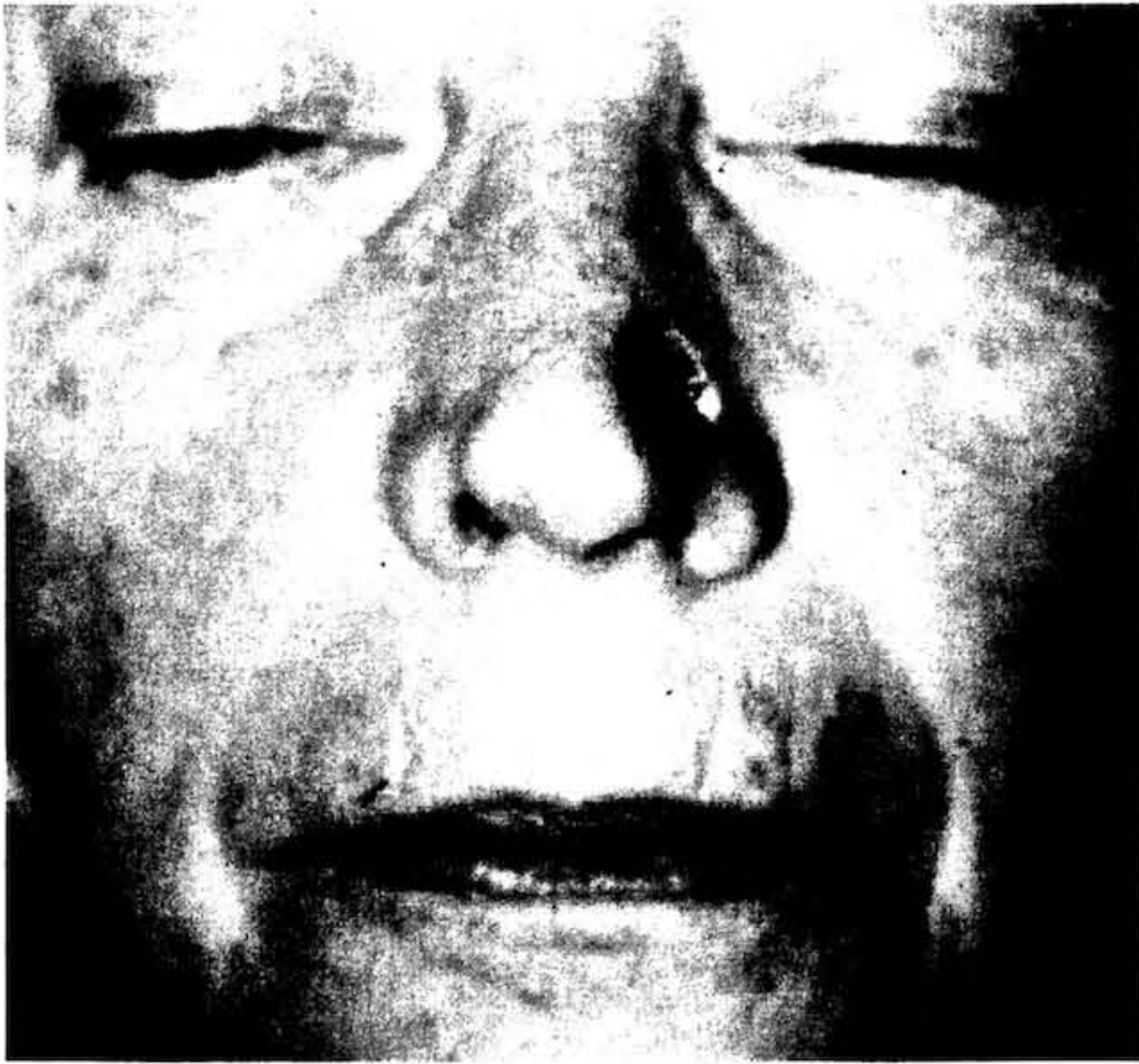## Discussion

In the past, we have occasionally utilized the Reiger dorsal nasal flap for reconstruction of selected nasal tip defects.<sup>7,8</sup> The Reiger flap is a medially based rotation advancement flap that is united with a V-Y advancement glabellar flap.<sup>7</sup> This is a durable and reliable flap that is simple to apply. However, it often results in unacceptable esthetic outcomes that can be quite significant. The flap margins do not traverse favourable junctions between esthetic subunits. The resultant scars are often quite visible as they traverse the entire supratip area. As the Reiger flap is rotated into position, it also results in the formation of a standing cutaneous cone. This deformity is difficult to address, because full correction will result in compromise of the vascularity of a portion of this flap.<sup>13</sup> Moreover, correction of the standing cutaneous cone will cause unfavourable scar orientation in the immediate supratip area. The significant superiorly oriented tension generated by this flap will, on occasion, also lead to some distortion of the alar margin. Finally, persistent long-term edema at the distal and inferior portion of the flap is often evident. Thus, the esthetic limitations encountered with the traditional Reiger nasal flap prompted us to develop a new flap. Our flap incorporates the durability and ease of use of the Reiger flap but, in addition, addresses the significant esthetic concerns seen with its surgical application. Bilobed and nasolabial flaps may also be useful for closure of nasal-tip defects. However, significant drawbacks of long-term pincushioning commonly noted with bilobed flaps, and the need for 2 or 3 stages for nasolabial flaps all suggest that no ideal flap for nasal-tip defect reconstruction exists.

Our laterally based heminasal transposition rotation flap results in confinement of all incisions to one side of the nose, with the majority of the incisions fol-

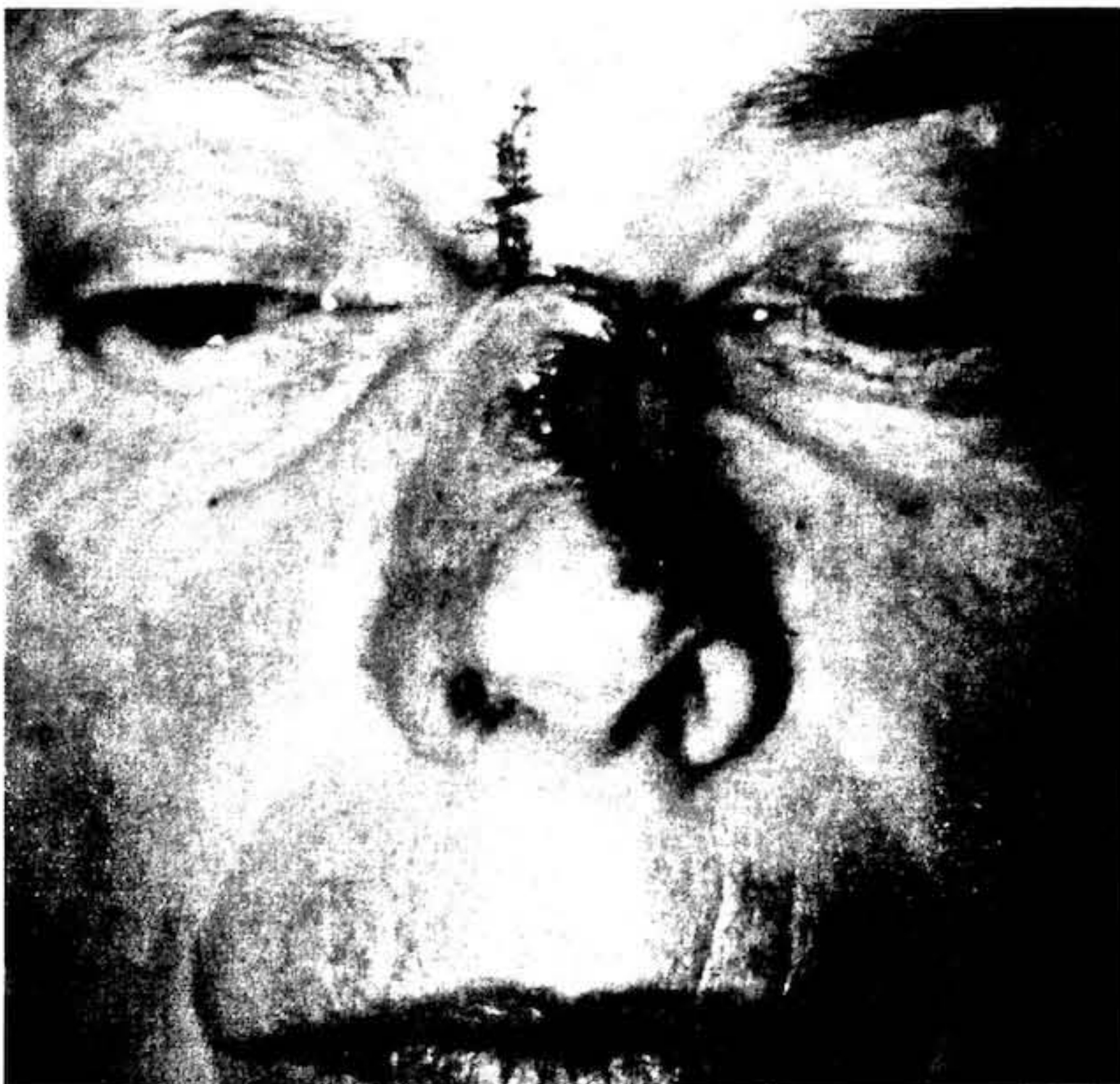

**Figure 6** 1-month postoperative result.

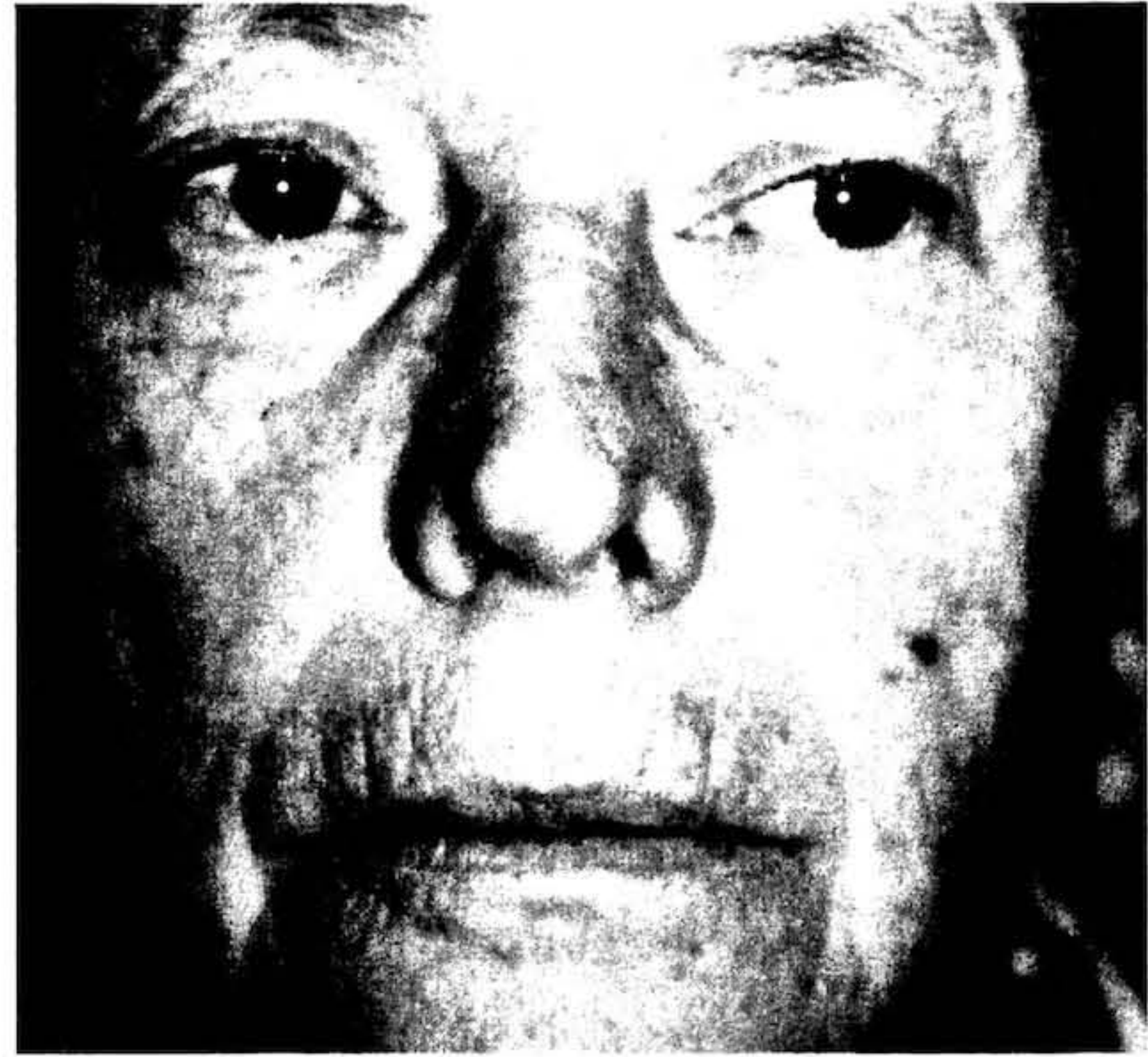

**Figure 7** Nasal defect after excision of basal cell carcinoma.

lowing the junctions between the esthetic subunits of the nose. Planned excision of the standing cutaneous cone noted after flap rotation leaves a scar at the junction between the alar and sidewall subunits. Moreover, full cone excision is possible without risking devascularization of any portion of the flap. The external nose lymph drains to the facial lymph nodes primarily via lymphatic channels traversing the cheek-nose junction. This area is left intact with our flap, resulting in minimal flap lymphedema compared to the distal portion of the Reiger flap. Preservation of laterally oriented vascular channels and a favourable length-to-width ratio contributes to the venous and lymphatic drainage of our



**Figure 8** Intraoperative flap closure.



**Figure 9** 6-month postoperative result.

flap. Furthermore, less superiorly oriented pull is exerted by the configuration of our flap design. Thus, we have encountered no significant problems with alar retraction in our patients. Also, the use of a separate glabellar transposition flap has resulted in much less dorsal-nasal deformity than we had encountered with Reiger flaps.

The heminasal transposition rotation flap is limited to closing defects that are up to 2 centimeters in size. It is also not the ideal method for closure of defects in the infratip lobule and soft-tissue triangle areas of the nose. Otherwise, we have found it to be a reliable, efficient, and easy-to-use flap design that predictably results in favourable esthetic outcomes when used to reconstruct defects of the lower one half of the nose (Figs. 4 through 9). We have seen no untoward effects from the use of this flap. Finally, we have had no partial or complete flap loss in any of the 10 patients in whom we have utilized this flap for nasal reconstruction.

### **Conclusion**

We have described a new flap for lower nasal reconstruction. Our heminasal transposition rotation flap results in tension-free closure of defects of the lower half of the nose. Esthetically favourable incisions are generally possible at the junction between esthetic subunits, resulting in nice scar camouflage, and efficient venous and lymphatic outflow. All of these factors result in excellent defect closure and pleasing long-term outcomes.

### **References**

1. Marchac D, Toth JC. The axial frontonasal flap revisited. *Plast Reconstr Surg* 1985; 76:686-688.

2. Bennet JE. Reconstruction of the nose: reconstruction of lateral nasal defects. *Clin Plast Surg* 1981; 8:587-589.
3. Zimany A. The bilobed flap. *Plast Reconstr Surg* 1953; 11:424-427.
4. Lipshutz H, Penrod DS. Use of complete transverse nasal flap in repair of small defects of the nose. *Plast Reconstr Surg* 1972; 49:629-631.
5. Walkinshaw MD, Caffee HH. The nasolabial flap: a problem and its correction. *Plast Reconstr Surg* 1982; 69:30-31.
6. Andrews EB. Island flaps in facial reconstruction. *Plast Reconstr Surg* 1969; 44:49-52.
7. Rieger RA. A local flap for repair of the nasal tip. *Br J Plast Surg* 1967; 40:147-148.
8. Rigg BM. The dorsal nasal flap. *Plast Reconstr Surg* 1973; 52:361-364.
9. Strauch B, Fox M. V-Y bipedicle flap for resurfacing the nasal supratip region. *Plast Reconstr Surg* 1989; 83:899-902.
10. Meyer R, Kesslering UK. Reconstructive surgery of the nose. *Clin Plast Surg* 1981; 8:435-438.
11. Millard DR Jr. Reconstructive rhinoplasty of the nose tip. *Clin Plast Surg* 1981; 8:507-508.
12. Juri J, Juri C, Cerisola J. Contribution to Converse's flap for nasal reconstruction. *Plast Reconstr Surg* 1982; 69:697-699.
13. Burget GC, Menick FJ. *Aesthetic reconstruction of the nose*. St. Louis: Mosby, 1994:117-119.