

How I Do It

A New Technique of Sural Nerve Harvest

Yadranko Ducic, MD, FRCSC

The sural nerve continues to represent one of the most frequently used donor sites for both peripheral and cranial nerve grafting.¹⁻³ It provides for a readily accessible, easily harvested nerve graft that measures up to 40 cm in length. A number of sural nerve harvesting techniques have been described and used with success. Open techniques with either a single vertical incision placed over the course of the sural nerve in the lateral leg or a number of stairstep horizontal incisions placed across its course continue to represent the time-honoured standard. Recent experience with both the use of a tendon stripper to effect harvest or the adjunctive use of endoscopes has shown some promise.^{4,5} Transfer of the sural nerve as a vascularized graft has also been performed. However, experimental evidence seems to suggest that this is most appropriate only for nerve grafts exceeding 6 cm in length that are, in addition, associated with large overlying cutaneous defects.⁶ The routine use of vascularized sural nerve grafts does not, at this time, appear to be warranted in the majority of nerve grafting needs facing the reconstructive surgeon.

Despite the widespread use of sural nerve grafts, there has been little attention devoted in the published literature regarding associated donor site morbidity. Sural nerve harvest will generally leave the patient with cutaneous sensory loss over the lateral aspect of the foot and ankle. Although representing a seemingly minor morbidity, Staniforth and Fisher reported that greater than 40% of their patients undergoing sural nerve harvest regarded their sensory deficit as being uncomfortable, and that 16% complained of significant tenderness characteristic of neuromas.¹ Other authors have reported similar findings.⁷

This article will outline a new technique of sural nerve harvest that appears to leave the patient with little short-term and no significant long-term sensory deficit.

Methods and Materials

A total of 30 consecutive patients requiring interposition nerve grafting were prospectively evaluated in this case series. Four patients underwent reconstruction of the marginal mandibular branch of cranial nerve VII following sacrifice secondary to gross invasion by tumour. All required nerve grafts of at least 5 cm in length. Twenty-six patients underwent reconstruction of the spinal accessory nerve following sacrifice during radical neck dissections performed for advanced nodal neck disease. The nerve graft lengths in this group varied between 6 and 9 cm with a mean of 6.7 cm. All patients underwent evaluation of donor site morbidity, including sensory deficits, pain, and dysesthesias, and recipient site nerve graft success. All patients were followed for a minimum of 12 months.

Surgical Technique

A vertical incision is made approximately 1 cm posterior and 1 cm superior to the lateral malleolus. This incision is extended vertically for a variable distance depending on the desired length of nerve graft that will be required. The sural nerve is consistently identified immediately deep to the lesser saphenous vein coursing within the subcutaneous tissue (Fig. 1). Care is taken during isolation of the sural nerve to avoid excessive stretching or blunt trauma to the nerve proper. Once the required length of nerve graft is measured, microdissection scissors under loupe or microscope magnification are used to incompletely transect the nerve inferiorly, just superior to the level of the malleolus. Individual nerve fascicles are readily identifiable at this point. Generally, up to two-thirds of the thickness of the sural nerve is harvested at this point by precisely dissecting along the easily discernible interfascicular dissection plane from inferior to superior (Fig. 2). Once the desired length of graft has been obtained, the nerve is incompletely transected superiorly. Thus, an intact segment of at least one-third of the diameter of the sural nerve is left intact at the donor site. This intact nerve

Received 21/6/99. Received revised 10/1/00. Accepted for publication 6/4/00.

Yadranko Ducic: Department of Otolaryngology, University of Texas SouthWestern Medical Center, Dallas, Texas, and the Division of Otolaryngology and Facial Plastic and Reconstructive Surgery, John Peter Smith Hospital, Fort Worth, Texas.

Address reprint requests to: *Dr. Yadranko Ducic*, Director, Otolaryngology and Facial Plastic Surgery, John Peter Smith Hospital, 1500 South Main Street, Fort Worth, TX 76104.

segment represents clearly defined nonviolated nerve fascicles. The split sural nerve graft is then anastomosed to the recipient nerve sites within the head and neck using standard neural microanastomosis technique with interrupted epineural sutures of 7.0 nylon (Fig. 3). The donor site is closed in layers over a number 7 Jackson-Pratt drain and wrapped with a Kerlex gauze. The patient is ambulated immediately postoperatively.

Discussion

All patients were evaluated postoperatively with both two-point discrimination and light touch, using the normal leg as the patients' control. No patient complained of any significant pain or dysesthesia at the donor site, either short term or at any time during their follow-up. At 12 months, two-point discrimination and light touch testing (as compared to the nonoperated foot and ankle) failed to reveal any statistically significant difference. Recipient nerve functional recovery has been excellent with a recovery to House-Brackman grade 3 for the cranial nerve VII reconstructions and maintenance of muscle tone and bulk in the accessory nerve reconstruction patients. Sixteen of this latter group of patients have achieved excellent painless range of motion at the level of the shoulder.

The sural nerve is a consistent sensory nerve most commonly formed by the union of the peroneal communicating branch and the medial sural cutaneous nerve. Its sensory fibres supply the skin overlying the posterolateral lower leg, lateral aspect of the foot and heel, and the ankle, subtalar, and calcaneocuboid joints. The outlined technique attempts to maintain the integrity of this sensory distribution. The concept of splitting full-diameter sural nerve grafts for facial reanimation is well established. The ability of the sural nerve to be reliably and consistently split between its fascicles while maintaining its ability to act as a viable nerve graft at the recipient site prompted an extension

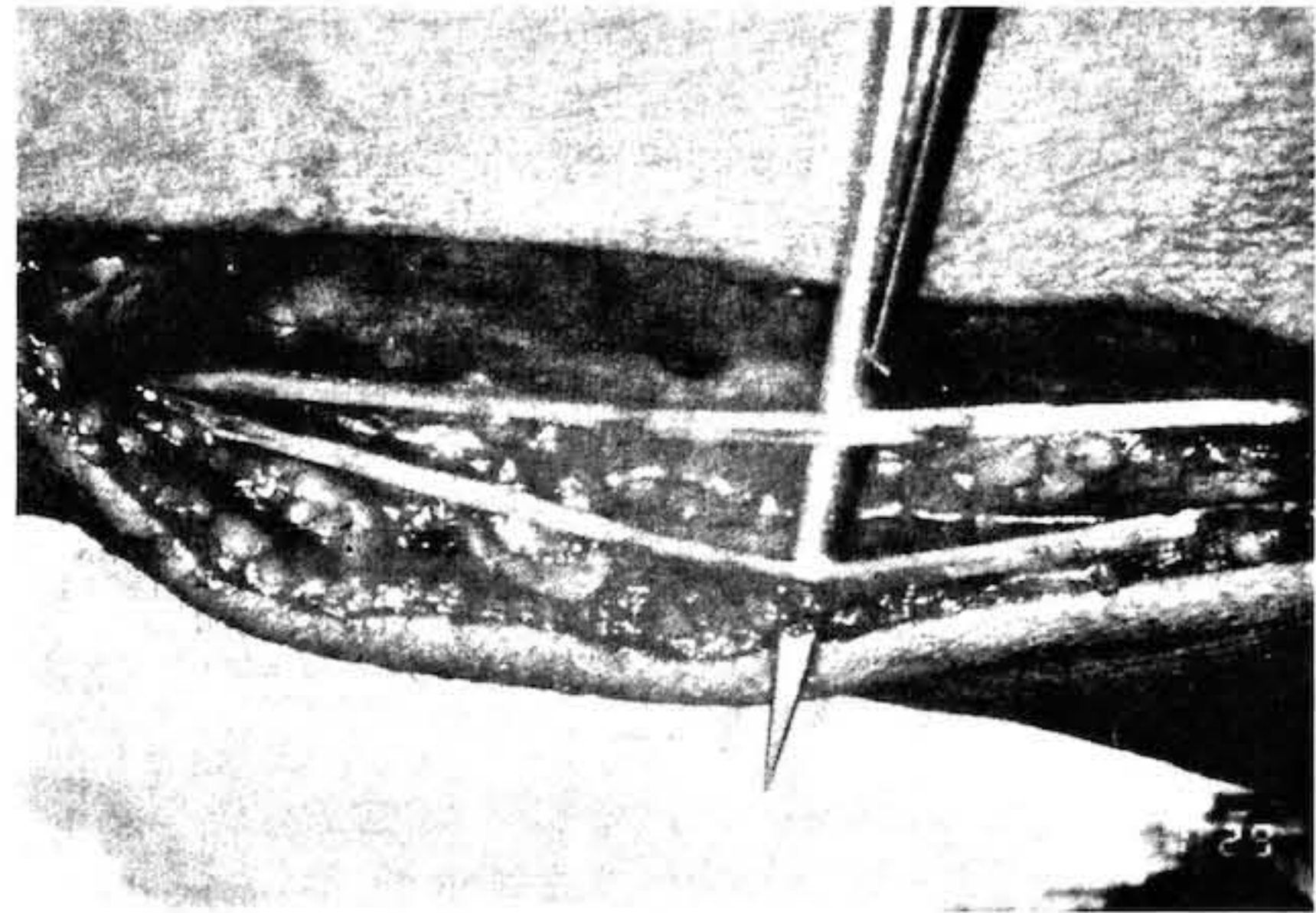


Figure 2 Sural nerve longitudinally split into two segments. One will serve as the nerve graft, whereas an intact fascicular portion of the nerve will remain at the donor site, preserving some sensation and acting as a guide for further nerve regeneration.

of this concept to the donor site. This has not been reported to date. The presence of intact sural nerve fascicles (at least one-third the diameter of the sural nerve) appears to be associated with two positive outcomes. First, the resulting hypoesthesia seen immediately postoperatively is not as clinically significant. In theory, over time the intact fascicles may act as a precise guiding framework that allows for optimal regrowth of the transected fascicles across the harvested "gap" in the sural nerve donor site. This would explain the lack of significant hypoesthesia noted on clinical testing at 12 months postoperatively. No adverse effects have been noted at the donor site, and all nerve grafts have led to acceptable levels of recovery consistent with the author's previous experience with full-thickness sural nerve grafting.

The major potential drawback of the split sural nerve graft harvesting technique outlined above is the need for a vertical incision. This scar heals favourably

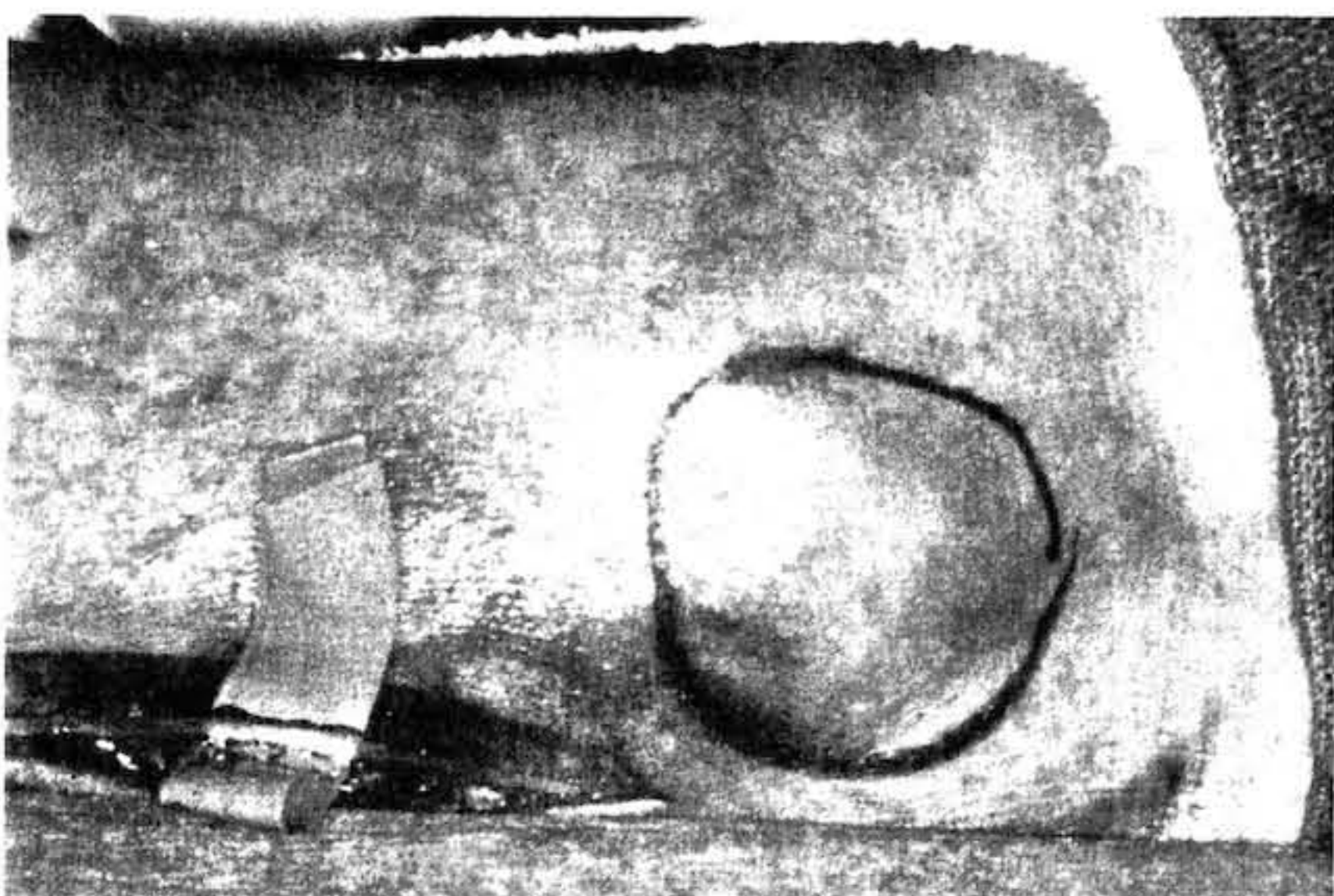


Figure 1 Sural nerve isolated along lateral aspect of lower leg posterosuperior to lateral malleolus.



Figure 3 Interposition split sural nerve graft provides for a good size match when used for cranial nerve XI reconstruction.

in most individuals. Stairstep multiple small horizontal incisions may be used as an alternative. Aesthetically, the resultant scarring is not significantly different unless nerve grafts greater than 15 cm in length are harvested. There are theoretical concerns associated with sural nerve harvest using a tendon stripper, in terms of an increased potential for neuroma formation and potential for disruption of neural tubules due to blunt blind dissection.

Conclusion

Split sural nerve graft harvesting appears to have a potentially useful role in head and neck reconstructive surgery. This technique has been associated with minimal donor site morbidity and excellent recipient nerve functional outcomes. The technique is simple, is easy to teach, and has been associated with high patient acceptance.

References

1. Staniforth P, Fisher TR. The effects of sural nerve excision in autogenous nerve grafting. *Hand* 1978; 10:187-190.
2. Hankin FM, Jaeger SH, Beddings A. Autogenous sural nerve grafts: a harvesting technique. *Orthopedics* 1985; 8:1160-1164.
3. Hill HL, Vasconez LO, Jurkiewicz MJ. Method for obtaining a sural nerve graft. *Plast Reconstr Surg* 1978; 61:177-179.
4. Capek L, Clarke HM, Zuker RM. Endoscopic sural nerve harvest in the pediatric patient. *Plast Reconstr Surg* 1996; 98:884-888.
5. Jaroszynski G, Johnson GH. Harvesting of the sural nerve with a tendon stripper. *Microsurgery* 1996; 17:217-220.
6. Doi K, Tamaru K, Sakai K, et al. A comparison of vascularized and conventional sural nerve grafts. *J Hand Surg* 1992; 17:670-676.
7. Ortiguera ME, Wood MB, Cahill DR. Anatomy of the sural nerve complex. *J Hand Surg* 1987; 12A:1119-1123.