

Aggressive Surgical Resection of Anaplastic Thyroid Carcinoma May Provide Long-term Survival in Selected Patients

Otolaryngology—
 Head and Neck Surgery
 148(4) 564–571
 © American Academy of
 Otolaryngology—Head and Neck
 Surgery Foundation 2013
 Reprints and permission:
sagepub.com/journalsPermissions.nav
 DOI: 10.1177/0194599813477364
<http://otojournal.org>


Ryan F. Brown, MD¹, and Yadranko Ducic, MD, FRCS^{2,3}

No sponsorships or competing interests have been disclosed for this article.

Received August 28, 2012; revised November 5, 2012; accepted January 15, 2013.

Abstract

Objective. In this study, we present our experience with aggressive surgical treatment in selected patients with anaplastic thyroid cancer with extrathyroidal extension.

Study Design. Case series with chart review.

Setting. Tertiary care referral center.

Subjects and Methods. Retrospective chart review of all patients with anaplastic thyroid cancer surgically treated by the senior author from January 1998 to July 2012.

Results. A total of 38 cases of anaplastic thyroid cancer were treated (21 male and 17 female). The mean age was 64.5 years. Twenty-two patients were considered surgically unresectable (18 had distant metastases and 4 had extrathyroidal extension of cancer lateral to carotid arteries) and underwent biopsy with or without tracheostomy. The remaining 16 patients underwent surgical resection with curative intent. Fourteen of these patients underwent postoperative radiation therapy. None of these 16 patients developed local recurrence. Six developed distant metastasis at an average follow-up of 3.2 months, 1 died of an unrelated myocardial infarction at 3 months, 2 were lost to follow-up, and 7 remain disease free with an average follow-up of 4.8 years (range, 9 months to 8 years). Of those patients who underwent complete surgical resection followed by postoperative radiation, 7 of 14 (50%) are still alive, with a mean follow-up of 4.8 years.

Conclusion. Selected patients with anaplastic thyroid cancer with extrathyroidal extension (stage IVB) who show no distant metastases by computed tomography or positron emission tomography scans and who do not have tumor extending lateral to the carotid arteries are candidates for complete surgical resection.

Keywords

anaplastic thyroid carcinoma/cancer, surgical, surgery, resection, survival

Anaplastic thyroid cancer (ATC) is a highly aggressive and lethal malignancy with median survival rates quoted between 2 and 12 months.¹⁻³ ATC represents 2% to 5% of all thyroid malignancies; however, it accounts for possibly >50% of thyroid cancer mortality.²⁻⁴ The annual incidence of ATC is 1 to 2 cases per million people. ATC incidence peaks at the sixth to seventh decade of life, with more than 90% of patients being older than 50 years.^{2,4,5} There have, however, been reports of children with ATC.² The female-to-male ratio is often between 1.2 and 2:1.²⁻⁵

Treatment options include external beam radiation therapy (EBRT), chemotherapy, surgery, tracheostomy, and investigational clinical trials.² Much of the current literature has focused on new combinations of EBRT and chemotherapeutic agents with or without surgery, with most results showing moderate improvements in survival rates.^{1,3,6-24} The role of surgery in the treatment of ATC has been controversial. Most studies that discuss surgery refer to thyroidectomy only for intrathyroidal ATC and report that extrathyroidal extension represents unresectable disease.^{16,17,25-28} This study presents our favorable experience with complete surgical resection of patients with ATC who have extrathyroidal extension but no evidence of metastatic disease.

Methods

This study was approved by the John Peter Smith Hospital Institutional Review Board. We performed a retrospective

¹Department of Head and Neck Surgery, Kaiser Permanente, Denver, Colorado, USA

²Department of Otolaryngology—Head and Neck Surgery, University of Texas Southwestern Medical Center, Dallas, Texas, USA

³Otolaryngology and Facial Plastic Surgery Associates, Fort Worth, Texas, USA

Corresponding Author:

Yadranko Ducic, MD, Otolaryngology and Facial Plastic Surgery Associates, 923 Pennsylvania Ave, Ste 100, Fort Worth, TX 76104, USA
 Email: yducic@sbcglobal.net

chart review of all consecutive patients with a diagnosis of anaplastic thyroid cancer operated on by the senior author from January 1998 to July 2012. All patients were evaluated preoperatively for extent of disease and possible metastases with either computed tomography (CT) scans of the head, neck, chest, and abdomen or positron emission tomography (PET) scans. During the initial time period of the study, PET scans were not available. When this technology did become available, it was incredibly variable depending on the patient's insurance status if their insurance would pay for a PET scan. Thus, a PET scan was performed when possible; but at the least, all patients had a CT of the neck, chest, and abdomen performed. All patients in this study had extrathyroidal extension of tumor (**Figure 1a-e**). All patients had an open biopsy (thyroid isthmusectomy) performed that was read by a board-certified pathologist confirming the diagnosis of anaplastic thyroid cancer (**Figure 2**). Patients with significant airway obstruction received a tracheostomy. Based on preoperative imaging, patients received supportive care, palliative radiation therapy, palliative chemotherapy, or complete surgical resection. All surgical resections were reviewed by 2 separate pathologists to confirm the diagnosis of anaplastic thyroid cancer. All patients treated with complete surgical resection underwent postoperative external beam radiation therapy varying from 50 to 70 Gy. The treatment regimen remained the same for all patients treated during the 14-year time period of this study.

All patients were followed for as long as possible with serial CT neck/chest and/or PET scan, head and neck surgery follow-up, oncology follow-up, and some with endocrinology follow-up. Follow-up was the same for all patients in this study, with each following up at least monthly during the first year and then gradually spacing out visits to every other month for the second year, and so on.

Results

A total of 38 patients were treated for ATC between January 1998 and July 2012. Twenty-one were male, and 17 were female. The mean age was 64.5 years, with a range of 32 to 87 years. Eighteen patients had metastases discovered on preoperative imaging (13 lung, 3 lung and bone, 1 lung and liver, and 1 lung, bone, liver, and spleen). Of these 18 patients with metastases, 11 underwent cervical tracheostomy with open biopsy, 3 underwent biopsy plus a mediastinal tracheostomy to get below the area of obvious gross involvement of the tracheal wall, and 4 patients underwent open biopsy alone. In these 18 patients with metastases, the average survival time from date of biopsy was 5.4 months (range, 1.5-8 months). Four of these patients received palliative radiation, 2 received palliative chemotherapy, and the rest received supportive care.

Twenty patients had no metastases at presentation on preoperative imaging. Four of these patients were found to have contiguous extension of cancer from the thyroid to encase the carotid artery and extend lateral to the carotid. All 4 of these patients underwent biopsy, and 2 received a cervical tracheostomy. These 4 patients were referred to hospice, and

the average survival was 3.8 months (range, 3.0-5.8 months). Interestingly, all 4 patients had evidence of metastases by 2.5 months of follow-up (3 lung, 1 lung and bone).

Sixteen total patients had no metastases, and their cancer did not extend lateral to the carotid arteries. All 16 of these patients underwent complete surgical resection with removal of all macroscopic disease. Twelve patients had a total laryngectomy performed, 4 patients had a tracheal resection, and 6 had a cervical esophagectomy (1 of these needed a gastric pull-up procedure). Twelve of the 16 surgically resected patients also had lymphadenopathy, and all underwent complete excision of adenopathy. Seven of these patients had paratracheal adenopathy, 3 had superior mediastinal adenopathy, and 2 had both cervical level 4 and superior mediastinal adenopathy. Of the 5 patients with superior mediastinal involvement, 3 underwent transcervical excision and 2 had a median sternotomy plus transcervical excision (**Figure 3a-c**).

Of the 16 surgically resected patients, 14 underwent postoperative EBRT varying from 50 to 70 Gy. None received chemotherapy. The treatment regimen was consistent throughout all 14 years of this study, and no changes were made. Two of the surgically resected patients were immediately lost to follow-up and did not receive EBRT. One patient died of an unrelated myocardial infarction at 3 months and had no evidence of disease. None of the 14 patients who received postoperative EBRT had local recurrence. Six developed distant metastases at an average follow-up of 3.2 months (range, 2-4.8 months). The remaining 7 patients are disease free, with an average follow-up of 4.8 years (range, 9 months to 8 years; **Table 1**).

Seven of the 14 patients (50%) who underwent complete surgical resection followed by EBRT are still alive, with an average follow-up of 4.8 years. Each of these 7 patients is being followed by serial CT neck/chest or PET scans and visits with head and neck surgery, oncology, and some with endocrinology. No patients developed metastases after a normal examination and normal radiographic imaging at the 6-month mark. Of the 5 patients who had mediastinal lymphadenopathy, 3 (60%) are still alive with no evidence of disease with an average follow-up of 6.5 years.

There were some complications seen from the 16 surgical resections. Two total laryngectomy patients developed postoperative pharyngocutaneous fistulas. One closed spontaneously and the other closed after a local flap procedure performed in the operating room. There were 9 cases of temporary hypocalcemia and 5 cases of permanent hypocalcemia requiring long-term calcium supplementation. There was one perioperative myocardial infarction managed conservatively by cardiology. There was one incidence of postoperative pneumonia, which was managed medically and resolved. There are no incidences of long-term gastric feeding tubes, and all survivors are currently eating and drinking.

Discussion

ATC remains an aggressive and lethal disease with a dismal prognosis despite numerous treatment regimens. Few risk

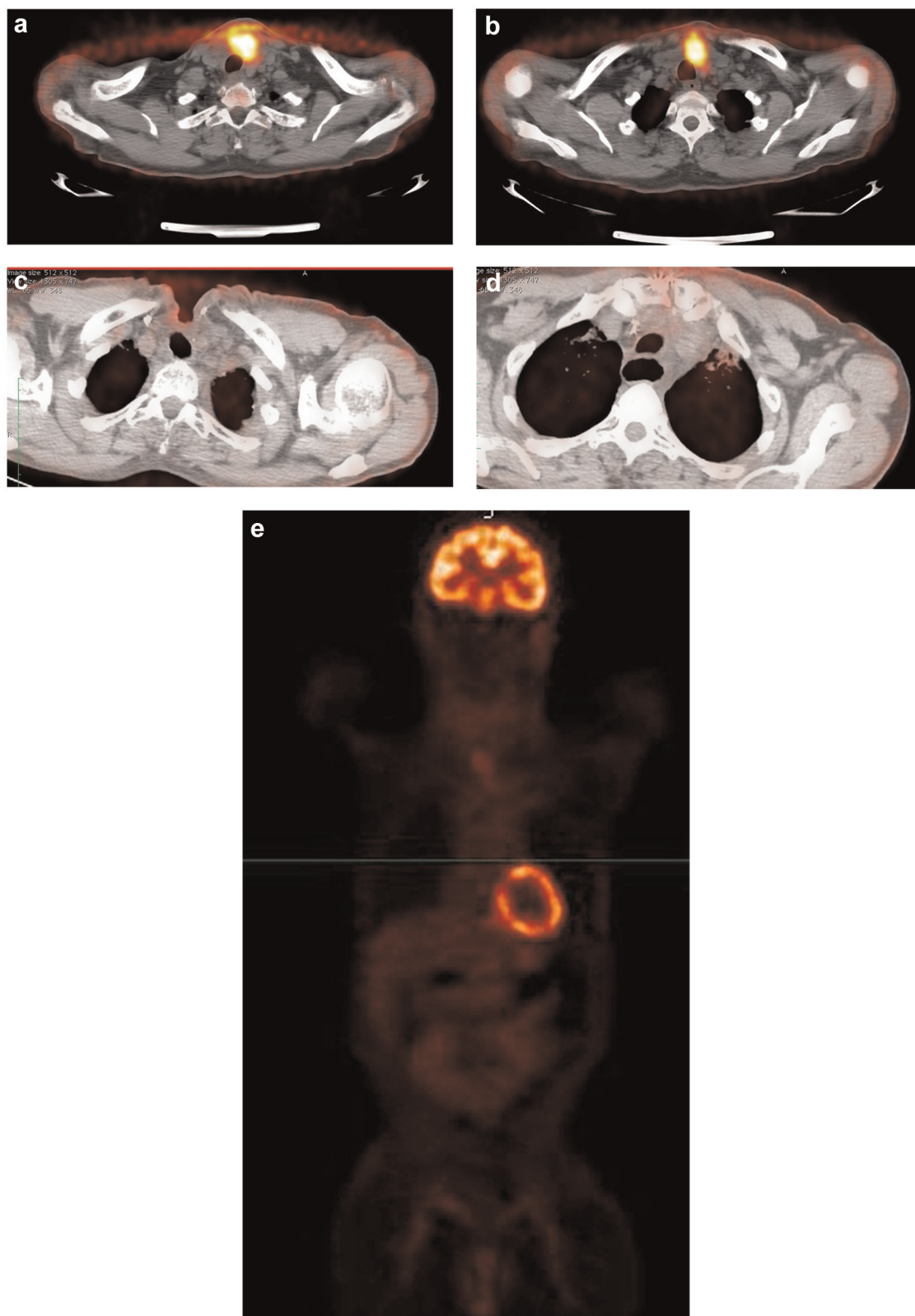


Figure 1. (a) Preoperative positron emission tomography (PET) scan in a patient with anaplastic thyroid cancer with intense uptake in the thyroid gland and left thyroid cartilage. (b) Preoperative PET scan in the same patient showing extension of disease into the superior mediastinum. (c) Nine-month postoperative PET scan showing no evidence of disease in the thyroid resection bed and postoperative changes of a total laryngectomy. (d) Nine-month postoperative PET scan in same patient showing no evidence of disease in the superior mediastinum. (e) Nine-month postoperative PET scan in same patient showing no evidence of distant metastases.

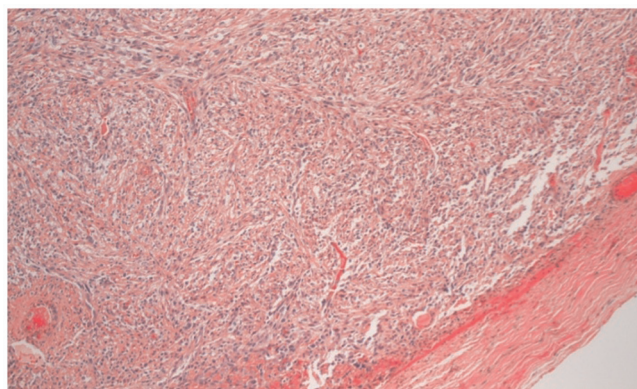


Figure 2. Pathology slide from above patient showing anaplastic thyroid cancer. Note that the normal thyroid architecture has been replaced with poorly differentiated anaplastic cells.

factors of developing this fatal disease are known. Numerous studies have reported a prior history of thyroid goiter or being from a geographic area with a high incidence of endemic goiter as a risk factor for ATC.^{3,29,30} About 25% to 50% of patients with ATC also have a previous or concurrent history of well-differentiated thyroid cancer (papillary or follicular thyroid cancer). This supports the belief that ATC arises from dedifferentiation of previous well-differentiated thyroid cancer, although it is not known if ATC can arise *de novo*. ATC cells do not retain any of the biological features of the original follicular cells, such as uptake of iodine and synthesis of thyroglobulin, and commonly have p53 mutations.^{1,2,5} Three histologic patterns are recognized but do not predict patients' outcomes: spindle, giant cell, and squamoid.^{1,2,4,5,30}

Most patients present with a rapidly enlarging neck mass. The mean size of the mass is 8 cm and ranges from 3 to 20 cm. Patients also often have local compressive symptoms including dysphagia, hoarseness, neck pain, dyspnea, and stridor. Cervical lymphadenopathy is seen in up to 40% of patients.^{1-4,30} Extrathyroidal extension into the surrounding muscles, trachea, larynx, and esophagus is seen in up to 70% of patients. Evidence of metastatic disease is seen in 50% of patients at presentation, and another 25% develop metastasis during the course of illness. The most common sites of metastases are lung (80%), bone (6%-15%), and brain (5%-13%).^{1,4,6,30}

A review of the literature from 1975 to the present shows various treatment combinations of radiation, chemotherapy, and surgery. The median survival in the vast majority of these studies ranges between 2 and 12 months. Studies using radiation therapy or hyperfractionated radiotherapy as a single modality have not been shown to alter the course of ATC in most patients. It is now used mostly in multimodality treatment. Chemotherapy treatments initially consisted of doxorubicin and have more recently included paclitaxel, docetaxel, fosbretubulin, sorafenib, and combretastatin.^{1,3,6,7-21} These are also used as part of multimodality treatments. Cisplatin, bleomycin, etoposide, and methotrexate have all been used in the past with poor response rates.³ There have been a lot of studies on the molecular pathogenesis of ATC that includes mutations in genes, RNAs, and proteins. Numerous proteins involving transcription factors, signaling, pathways, mitosis, proliferation, cell cycle, apoptosis, adhesion, migration, epigenetics, and protein degradation are affected. There is now a push to develop an individualized therapeutic regimen that inhibits the deregulation seen in

Table 1. Demographic and Survival Data for Patients Who Underwent Surgical Intervention

Patient	Age, y	Sex	Mediastinal Nodes Resected	Radiation	Survival
1	38	Male	No	No	Unknown, lost to follow-up
2	69	Male	No	No	Unknown, lost to follow-up
3	64	Female	Yes	Yes	NED 8.0 y
4	75	Male	No	Yes	DOD 5.5 y, metastatic disease to lungs at 2 mo
5	69	Female	No	Yes	NED 2.8 y
6	74	Male	Yes	Yes	NED 5.8 y
7	48	Female	No	Yes	DOD 6.2 mo, metastatic disease to lungs and liver at 3.8 mo
8	62	Male	No	Yes	NED 9 mo
9	71	Female	No	Yes	NED 3.9 y
10	73	Male	Yes	Yes	DOD 7.5 mo, metastatic disease to lungs at 2.5 mo
11	59	Female	Yes	Yes	NED 5.8 mo
12	47	Male	No	Yes	DUC 3 mo, from myocardial infarction
13	62	Female	Yes	Yes	DOD 6.8 mo, metastatic disease to lungs at 4.2 mo
14	74	Female	No	Yes	DOD 5.2 mo, metastatic disease to liver at 3.5 mo
15	58	Male	No	Yes	NED 6.6 y
16	63	Female	No	Yes	DOD 8.6 mo, metastatic disease to lungs and bone at 5.4 mo

Abbreviations: DOD, dead with evidence of disease; DUC, death from unrelated cause, no evidence of disease; NED, no evidence of disease.

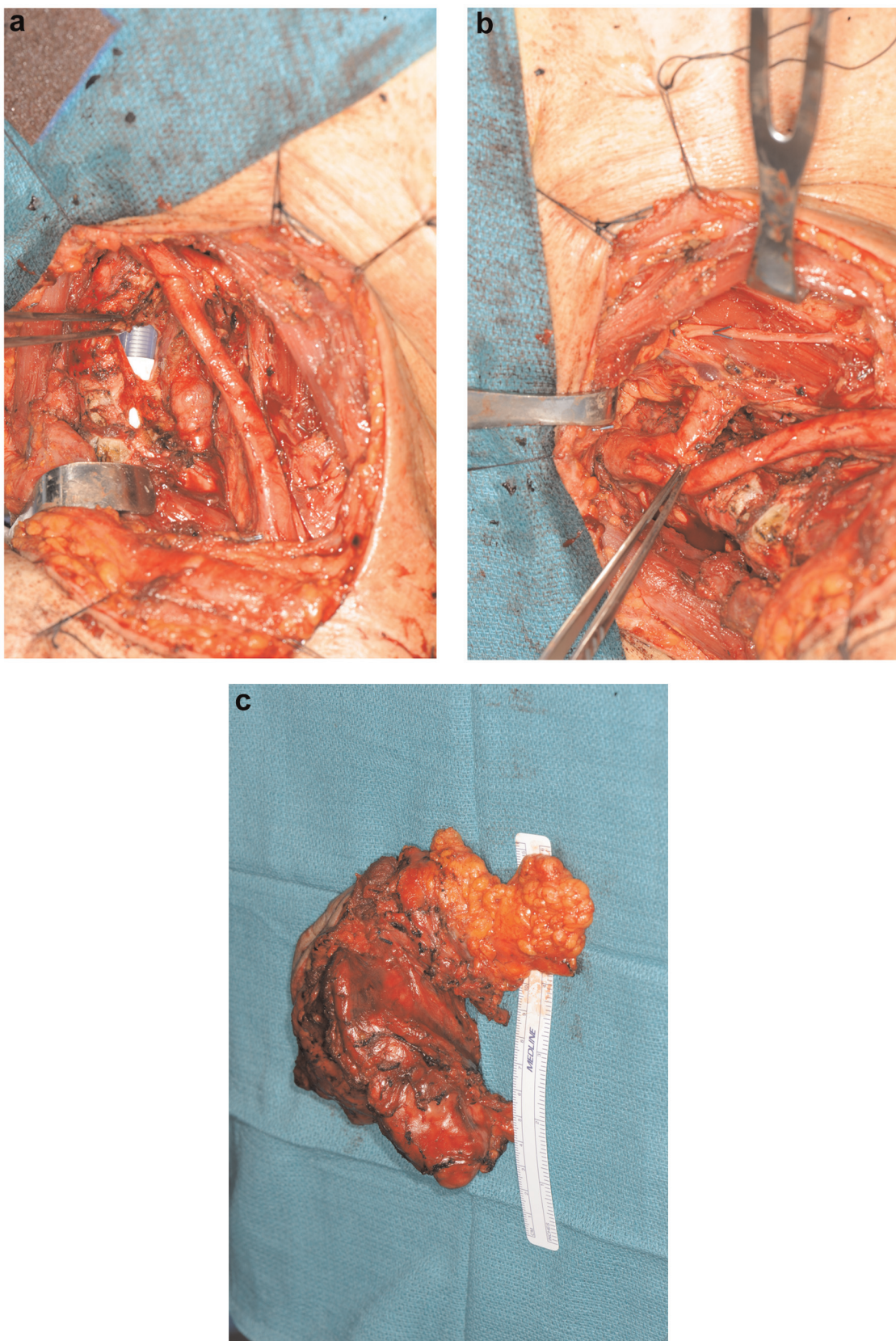


Figure 3. (a) Intraoperative dissection showing tracheal resection and complete thyroidectomy and mediastinal mass removal. Note that the endotracheal tube can be seen through the tracheal defect. (b) Intraoperative dissection showing the carotid artery and innominate artery have been dissected 360° in removing all macroscopic disease. (c) Final specimen consisting of total thyroid, anterior neck skin, trachea, and superior mediastinal nodes.

ATC on a molecular level, but these treatments are not currently available.^{22,23}

The role of surgery in treating ATC has been controversial. Historically, there were many reports that the role of surgery in ATC was limited to biopsy and securement of the airway. One of the most cited studies involved 134 cases from 50 years of experience (1949-1999) in treating ATC at the Mayo Clinic concluded that "neither the extent of operation nor the achieved completeness of resection had a significant impact on survival, with a median survival of 2.3 months for patients with gross residual disease after operation and 4 months for patients with complete tumor resection."¹⁶ Another study of 121 patients concluded that "radical surgery alone did not significantly increase survival duration over less radical surgery."¹⁷ Another study of 120 patients recommended that "ultraradical surgery to include segmental resection of the larynx, trachea or esophagus do not seem to be indicated, as prolonged survival is questionable and quality of life is certainly diminished." Many articles since have cited these findings and advocated a more minimal surgical approach given the high recurrence and death rates seen in ATC.²⁵⁻²⁸

Based on our findings in this study, we believe that aggressive, complete resection of ATC in selected patients is a reasonable treatment option that can potentially provide long-term survival and cure. The patients who are candidates for surgical resection are those without any evidence of distant metastases by preoperative CT or PET scans and whose local disease does not extend lateral to and encase the carotid arteries. All patients presenting with ATC should receive either CT scans of the head, neck, chest, and abdomen or a PET scan. The reason for such dismal survival results after surgical resection in the previous studies cited might be that radiologic technology has advanced and our ability to detect metastases has greatly improved. Many of the patients reported in those studies had only chest x-rays looking for metastases compared with the thin-cut CT scans and PET scans available today. Also, in a disease with median survival of only a few months, many patients would choose to undergo the morbidity of a total laryngectomy or esophagectomy if it meant a good chance at long-term survival. This is especially true given the good options for voice rehabilitation of tracheal esophageal prosthesis or using an electrolarynx. All 7 long-term survivors in our study also did not have prolonged use of a gastric feeding tube, and all are currently eating and drinking.

If patients meet the criteria on preoperative imaging of having no distant metastases and having no extension of local disease lateral to the carotids, we advocate complete excision of the local disease en bloc, including any necessary laryngectomy, tracheal resection, or esophagectomy. We do not attempt to dissect out the parathyroid glands to ensure complete oncologic resection. All enlarged cervical lymph nodes should be removed with a transcervical approach. For those patients with superior mediastinal lymphadenopathy that cannot be safely or completely removed through a transcervical approach, a median sternotomy can

provide good visualization and access to thoroughly remove all disease. In our experience, these superior mediastinal lymph nodes tend to be stuck to surrounding tissue and do not peel away easily.

It is also important to note that 5 patients in this study had superior mediastinal lymphadenopathy positive for ATC that was removed at the time of surgical resection. Three of the 5 patients (60%) are still alive today, with an average follow-up of 6.5 years. Two of these patients died from their disease at 7.5 months and at 6.8 months. These are small numbers of patients, but it would appear that having superior mediastinal spread of disease is not a contraindication to surgical resection and that such patients may also attain long-term survival.

We recommend postoperative external beam radiation treatment in surgically resected patients. Long-term disease-free survival was seen in 7 of 14 patients (50%) who underwent complete surgical resection followed by EBRT, with a mean survival of 4.8 years (range, 9 months to 8 years). None of the patients in this study who underwent surgical resection received chemotherapy. Although this is standardly given at most centers, the senior author has not felt it to be significantly beneficial, except in palliation. Since chemotherapy has not shown any significant survival benefit in most studies and can cause significant morbidity in some patients, it was decided to not offer this as part of the treatment regimen.

As all ATC does not carry the same prognosis, a staging system was developed by the Union for International Cancer Control that classified all ATC as stage IV. This was further divided into 3 subcategories: stage IVA, tumor limited to the thyroid; stage IVB, tumor beyond the thyroid capsule; and stage IVC, presence of distant metastasis.^{31,32} Our study would apply to stage IVB patients who have extrathyroidal extension without any distant metastases. Interestingly, there have been several recent studies regarding treatment of stage IVA and stage IVB ATC patients that report increased median survival combining complete surgical resection with EBRT.³³⁻³⁹ One study of 262 patients with ATC showed that radiotherapy added to surgery resulted in improved survival for patients with disease extending into adjacent tissue. However, those patients who had disease confined to the thyroid capsule or had distant metastatic disease did not benefit from radiotherapy after surgery.³³ Another study with 100 cases of ATC had 70 patients undergo surgery with or without adjuvant treatment. Nineteen patients had survival greater than 1 year, and the statistically significant factors that increased survival were complete surgical resection and postoperative radiation of doses >40 Gy. Age >70 years, white blood cell >10,000, extrathyroidal invasion, and distant metastasis worsened prognosis. Interestingly, chemotherapy was not associated with a significant longer survival.³⁸ In a couple of these studies, the addition of EBRT to surgery for stage IVB patients showed much greater survival benefit than for stage IVA patients.^{33,39}

One study that involved 40 patients with ATC showed that the 20 patients who underwent surgical resections of

ATC showed a mean survival of 8 months, compared with only 4 months for those who did not. They had 1 long-term survivor of 80 months. This study advocated total thyroidectomy and cervical lymphadenectomy and that 1 recurrent laryngeal nerve should be preserved.³⁵ We agree with the benefits of surgery and preserving vital structures in these patients but would recommend expanding the number of patients potentially treated by performing broader resections when oncologically necessary, even if it resulted in both recurrent laryngeal nerves being sacrificed and further extensive surgery.

Airway management remains a crucial part of treating ATC. Airway issues may be related to a large mass in the central compartment, tracheal compression, unilateral or bilateral vocal cord paralysis, or direct infiltration of the tumor into the tracheal lumen. Airway management should be addressed depending on the patient's and family's wishes, the extent of disease, and possibility of cure. It is also important to secure the airway until a diagnosis of lymphoma can be ruled out as these patients can expect complete improvement in their airway.⁴⁰ In the 38 patients treated in this study, 6 did not receive any sort of a tracheostomy and were referred for palliative treatment or hospice. Three patients underwent mediastinal tracheostomy in which a portion of the sternum was removed to access the trachea below where there was tracheal invasion with tumor. The tracheostomy was then made either above or below the innominate artery depending on its location. Although a mediastinal tracheostomy carries morbidity, it should remain in the airway management arsenal in treating ATC as bulky tumor is frequently covering the cervical trachea.

One of the weaknesses of this study is that it is a retrospective review and patients were not randomized to different treatment arms. This would be difficult to carry out in ATC, however, given survival rates are only months. Also, no patients received any sort of postoperative chemotherapy. Given recent advances in targeted agents that act at a disease-specific, molecular level, future studies might include adding some of these agents to see if they improved long-term survival.

Conclusion

Complete and aggressive surgical excision of all macroscopic disease followed by EBRT should be considered in all patients presenting with stage IVB ATC who do not have metastatic disease based on preoperative CT or PET scans and who do not have local extension of disease lateral to the carotid arteries. This can provide potentially long-term survival (7 of 14 patients with a mean survival of 4.8 years in this study) in an otherwise uniformly fatal diagnosis.

Author Contributions

Ryan F. Brown, data analysis, manuscript preparation; **Yadranko Ducic**, study design, patient population and concept, manuscript review.

Disclosures

Competing interests: None.

Sponsorships: None.

Funding source: None.

References

1. Are C, Shaha AR. Anaplastic thyroid carcinoma: biology, pathogenesis, prognostic factors, and treatment approaches. *Ann Surg Oncol*. 2006;13(4):453-464.
2. Neff RL, Farrar WB, Kloos RT. Anaplastic thyroid cancer. *Endocrinol Metab Clin North Am* 2008;37:525-538.
3. Nagaiah G, Hossain A, Mooney CJ, et al. Anaplastic thyroid cancer: a review of epidemiology, pathogenesis, and treatment. *J Oncol*. 2011;2011:542358.
4. Green LD, Mack L, Pasiaka JL. Anaplastic thyroid cancer and primary thyroid lymphoma: a review of these rare thyroid malignancies. *J Surg Oncol*. 2006;94:725-736.
5. Chiacchio S, Lorenzoni A, Boni G, et al. Anaplastic thyroid cancer: prevalence, diagnosis and treatment. *Minerva Endocrinol*. 2008;33(4):341-357.
6. Derbel O, Limem S, Segura-Ferlay C, et al. Results of combined treatment of anaplastic thyroid carcinoma (ATC). *BMC Cancer*. 2011;11:469.
7. Sosa JA, Elisei R, Jarzab B, et al. Randomized phase 2/3 trial of a tumor vascular disrupting agent, fosbretubulin (CA4P), with carboplatin and paclitaxel (P) in anaplastic thyroid cancer (ATC): interim safety and efficacy results of the FACT trial. *J Clin Oncol*. 2011;29(15S):5502.
8. Mooney CJ, Nagaiah G, Fu P, et al. A phase II trial of fosbretubulin in advanced anaplastic thyroid carcinoma and correlation of baseline serum-soluble intracellular adhesion molecule-1 with outcome. *Thyroid*. 2009;19(3):233-240.
9. Nagaiah G, Fu P, Wasman JK, et al. Phase II trial of sorafenib in patients with advanced anaplastic carcinoma of the thyroid. *J Clin Oncol*. 2009;15S:6058.
10. De Crevoisier R, Baudin E, Bachelot, et al. Combined treatment of anaplastic thyroid carcinoma with surgery, chemotherapy, and hyperfractionated accelerated external radiotherapy. *Int J Radiat Oncol Biol Phys*. 2004;60(4):1137-1143.
11. Mitchel FW, Suzanne LW, Andrew GH, et al. Hyperfractionated radiation therapy and adriamycin for anaplastic thyroid cancer. *Proc Am Soc Clin Oncol*. 2002;21:931.
12. Sugino K, Ito K, Mimura T, et al. The important role of operations in the management of anaplastic thyroid carcinoma. *Surgery*. 2002;131:245-248.
13. Tenvall J, Lundell G, Wahlberg P, et al. Anaplastic thyroid carcinoma: three protocols combining doxorubicin, hyperfractionated radiotherapy and surgery. *Br J Cancer*. 2002;86:1848-1853.
14. Sugitani I, Kasai N, Fujimoto Y, et al. Prognostic factors and therapeutic strategies for anaplastic carcinoma of the thyroid. *World J Surg*. 2001;25:617-622.
15. Besic N, Auersperg M, Us-Krasovec M, et al. Effects of primary treatment on survival in anaplastic thyroid carcinoma. *Eur J Surg Oncol*. 2001;27:260-264.
16. McIver B, Hay ID, Giuffrida D, et al. Anaplastic thyroid carcinoma: a 50 year experience at a single institution. *Surgery*. 2001;130:1028-1034.

17. Venkatesh YS, Ordonez NG, Schultz PN, et al. Anaplastic carcinoma of the thyroid: a clinicopathologic study of 121 cases. *Cancer*. 1990;66:321-330.
18. Kim JH, Leeper RD. Treatment of locally advanced thyroid carcinoma with combination doxorubicin and radiation therapy. *Cancer*. 1987;60:2372-2375.
19. Simpson WJ. Anaplastic thyroid carcinoma: a new approach. *Can J Surg*. 1980;23:25-27.
20. Aldinger KA, Samaan NA, Ibanez M, et al. Anaplastic carcinoma of the thyroid: a review of 84 cases of spindle and giant cell carcinoma of the thyroid. *Cancer*. 1978;41:2267-2275.
21. Jereb B, Stjernsward J, Lowhagen T. Anaplastic giant cell carcinoma of the thyroid: a study of treatment and prognosis. *Cancer*. 1975;35:1293-1295.
22. Smallridge RC, Marlow LA, Copland JA. Anaplastic thyroid cancer: molecular pathogenesis and emerging therapies. *Endocr Relat Cancer*. 2009;16(1):17-44.
23. Woyach JA, Shah MH. New therapeutic advances in the management of progressive thyroid cancer. *Endocrin Relat Cancer*. 2009;16:715-731.
24. Troch M, Koperek O, Schjeuba C, et al. High efficacy of concomitant treatment of undifferentiated (anaplastic) thyroid cancer with radiation and docetaxel. *J Clin Endocrinol Metab*. 2010;95(9):E54-E547.
25. Haigh PL. Anaplastic thyroid carcinoma. *Curr Treat Options Oncol*. 2000;1(4):353-357.
26. Grant CS, Thompson G. Anaplastic thyroid carcinoma: hope on the horizon? *Surgery* 2011;150:1220-1221.
27. Passler C, Scheuba C, Prager G, et al. Anaplastic (undifferentiated) thyroid carcinoma (ATC). *Langenbecks Arch Surg*. 1999;384:284-293.
28. Cobin RH, Gharib H, Bergman DA, et al. AACE/AAES medical/surgical guidelines for clinical practice: management of thyroid carcinoma. *Endocr Pract*. 2001;7:202-220.
29. Zivaljevic VR, Vlajinac HD, Marinkovic JM, et al. Case-control study of anaplastic thyroid cancer: goiter patients as controls. *Eur J Cancer Prev*. 2008;17:111-115.
30. Pasiaka JL. Anaplastic thyroid cancer. *Curr Opin Oncol*. 2003;15(1):78-83.
31. Ito Y, Hgashiyama T, Hirokawa M. Investigation of the validity of UICC stage grouping of anaplastic carcinoma of the thyroid. *Asian J Surg*. 2009;32(1):47-50.
32. Wein RO, Weber RS. Anaplastic thyroid carcinoma: palliation or treatment? *Curr Opin Otolaryngol Head Neck*. 2011;19:113-118.
33. Chen J, Tward JD, Shrieve DC, et al. Surgery and radiotherapy improves survival in patients with anaplastic thyroid carcinoma. *Am J Clin Oncol*. 2008;31:460-464.
34. Haigh PL, Ituarte PH, Wu HS, et al. Completely resected anaplastic thyroid carcinoma combined with adjuvant chemotherapy and irradiation is associated with prolonged survival. *Cancer*. 2001;91(12):2335-2342.
35. Palestini N, Brignardello E, Freddi M, et al. Surgical treatment of anaplastic thyroid carcinoma: our experience. *G Chir*. 2010;31:282-285.
36. Higashiyama T, Ito Y, Hirokawa M, et al. Optimal surgical procedure for locally curative surgery in patients with anaplastic thyroid carcinoma: importance of preoperative ultrasonography. *Endocr J*. 2010;57(9):763-769.
37. Falco CE, Grande AM, Nicolardi S, et al. Management of anaplastic thyroid carcinoma spread over the trachea with mediastinal extension. *G Chir*. 2010;31:390-393.
38. Akaishi J, Sugino K, Kitagawa W, et al. Prognostic factors and treatment outcomes of 100 cases of anaplastic thyroid carcinoma. *Thyroid*. 2011;21(11):1183-1189.
39. Sugitani I, Miyauchi A, Sugino K, et al. Prognostic factors and treatment outcomes for anaplastic thyroid carcinoma: ATC research consortium of Japan cohort study of 677 patients. *World J Surg*. 2012;36:1247-1254.
40. Shaha A. Airway management in anaplastic thyroid carcinoma. *Laryngoscope*. 2008;118:1195-1198.