



## Closed rhinoplasty

Yadranko Ducic, MD, MSc, FRCS(C), FACS, Robert DeFatta, MD, PhD

*From the Center for Aesthetic Surgery, Colleyville, Texas.*

### KEYWORDS

Rhinoplasty;  
 Delivery technique;  
 Endonasal technique;  
 Reconstruction

Open rhinoplasty has become a more common technique used to perform rhinoplasty over the past two decades. This has occurred because the open approach does not have the same limitations as the endonasal approach, such as poor diagnostic capability from the inability to identify small anatomic differences not observable from the surface, hidden anatomy, limited binocular vision, suturing and fixation techniques that may be difficult to impossible to perform endonasally, and restricted access to individual skeletal structures. However, the endonasal approach to rhinoplasty is very useful in certain circumstances. In that regard, this article discusses how the endonasal approach can be used to efficiently and effectively address many different cosmetic and functional deformities through the use of specific incisions and precise pockets. We feel that the endonasal technique remains a valuable procedure that every rhinoplasty surgeon should have in his or her surgical repertoire.

© 2007 Elsevier Inc. All rights reserved.

Nasal surgery can be traced back to ancient Egyptian hieroglyphics dating to 600 B.C.<sup>1</sup> Rhinectomy was a common form of punishment for adultery in ancient India, lending the first indication for forehead flap reconstruction of the nose. Roe, in 1887, was the first to describe alteration of the nasal tip and, in subsequent descriptions, reduction of the hump deformity.<sup>2</sup> However, Joseph, with detailed techniques for alteration of nasal form, is widely recognized as the father of modern corrective rhinoplasty.<sup>3</sup>

Occupying the central face, the nasal framework has a prominent role in the overall esthetic balance of the face. If it does not conform to the remainder of the facial form, it can detract from an otherwise well-balanced and symmetrical appearance. Integrating the nose into the surrounding structures after surgery can significantly affect overall perceptions of beauty. In addition, the nose has a vital functional role in respiration. Thankfully, form and function are closely linked in rhinoplasty. Thus, a symmetric, natural appearing nose with fundamentally sound structural support will generally serve the patient well in terms of breathing.

Rhinoplasty remains one of the more-challenging surgical procedures facing the facial plastic surgeon. There are significant patient factors that can affect outcomes, including skin quality and thickness, patient compliance with

follow-up care, quality of cartilage available for reconstruction and genetic factors such as nasal bone length, nostril size, etc. In addition, the prolonged healing period, unlike that seen in any other facial plastic procedure, makes it more difficult to determine ultimate effects of specific surgical maneuvers as they are so temporally distant from the “final” result. It is also important to realize that, in reality, the nose undergoes an evolution over time in terms of appearance. Postoperative changes, as in the case of tip grafts becoming excessively noticeable, may not be apparent for 3 to 5 years after initial surgery. It becomes a challenge for most surgeons to interest otherwise-happy patients in following up for this length of time.

Surgical approaches to the nose have undergone a dramatic paradigm shift during the past 2 decades. Closed rhinoplasty was the favored approach since the inception of nasal surgery. However, open rhinoplasty approaches have gained tremendous favor because of the ease of ability to completely and clearly diagnose structural problems via direct visualization, improved teaching capability and ease of use. It is felt to represent a technique that can result in a more predictable outcome resulting from the surgeon’s ability to directly and systematically address each part of the nasal framework. The drawbacks of the open technique include added length of procedure, nasal scars, prolonged edema, and the need for more structural grafts. Opening a nose will, in of itself, result in some loss of support that often needs to be addressed with extra grafting to maintain the status quo. Closed rhinoplasty will generally result in a

---

**Address reprint requests and correspondence:** Yadranko Ducic, MD, MSc, FRCS(C), FACS, Center for Aesthetic Surgery, 75 Main Street, Suite 150, Colleyville, TX 76034.

E-mail address: yducic@sbcglobal.net.

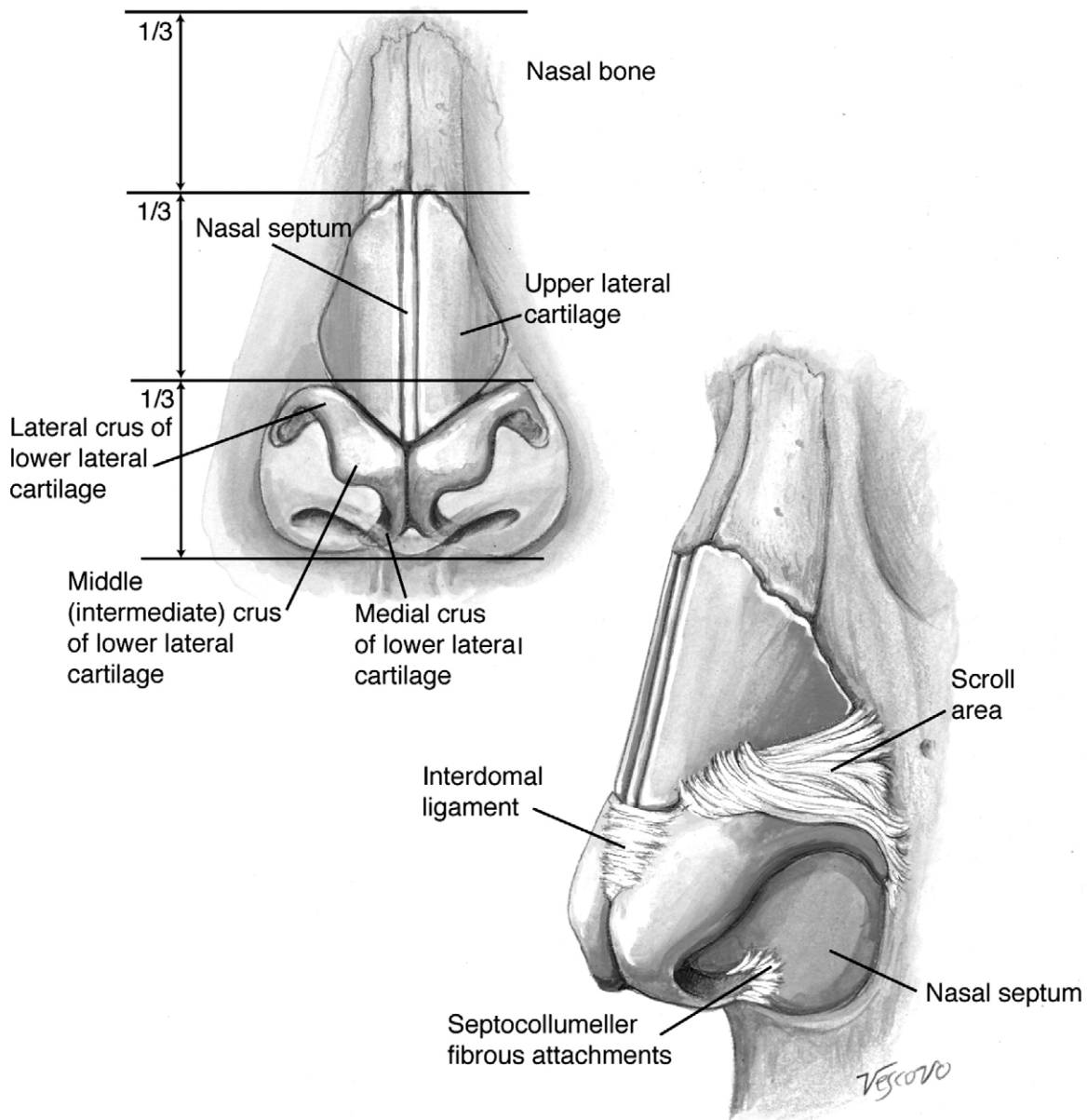
more expeditious postoperative recovery that will bring the patient their desired result as well as open techniques if executed properly in selected patients. Generally, patient with severe nasal tip deformities with prominent asymmetries will be better served with open techniques. All other patients will do well with either approach. Choice of technique in such a circumstance is dictated by surgeon and patient preference. In addition, if a patient has had an open approach previously and develops some relatively minor asymmetries during the follow-up period, they are generally better served with a closed rhinoplasty technique for secondary repair rather than a repeat open approach. It is also quite useful in the multiply operated on, graft depleted patient.

**Pertinent anatomy**

The skin overlying the lower one-third of the nose is generally thicker and more adherent to the underlying cartilages

than the skin covering the upper two-thirds of the osseocartilagenous framework. Skin thickness, related to genetic and racial backgrounds, can have profound effects on the ultimate result that may be achieved with cosmetic rhinoplasty as well as affecting the maneuvers that may be safely performed during surgery. The nasal muscles that have significant clinical relevance are the depressor septi nasi, which may decrease tip projection on smiling by shortening the upper lip, and the levator alaeque nasi, which has assists in maintaining the external nasal valve tone.

The nose has a rich blood supply that is quite forgiving in terms of surgical manipulation. There are extensive collaterals running between the ophthalmic artery branches (external nasal, dorsal nasal, and anterior ethmoidal) and the facial artery branches (angular and superior labial). The area with the most potentially tenuous blood supply is the nasal tip region which may be deleteriously affected by excessive defatting of the subcutaneous tissues in this region, especially in open approaches.<sup>4,5</sup> This is less of a concern in endonasal approaches in which case more aggressive defat-



**Figure 1** Structural support of the nose.

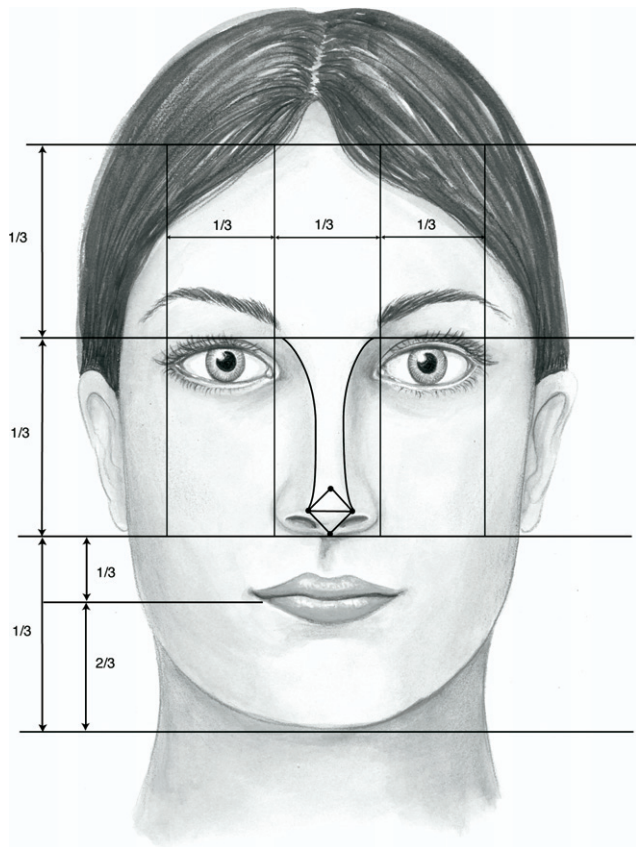


Figure 2 Preoperative analysis: frontal view.

ting in this region is more safely performed, but should be done judiciously.

The nasal septum consists of vomer, perpendicular plate of the ethmoid bone and the variably calcified quadrangular cartilage. There are turbinates per side that function to warm and humidify the air. Variable regular cycles of decongestion and congestion, alternating between the two sides of the nose, comprise the nasal cycle and are important in maintenance of adequate mucosal function. The antero-inferior aspect of the inferior turbinate is most prone to obstruction due to excessive submucosal engorgement and/or excessive conchal bone. It is best addressed with submucosal resection with avoidance of trauma to the overlying mucosa that may result in excessive long-term nasal crusting. Occasionally, a pneumatized middle turbinate (concha bullosa) may affect the ability to completely straighten a deviated septum and may need to be reduced with endoscopic sinus surgical techniques before septoplasty.<sup>6</sup>

The paired nasal bones and frontal process of the maxilla comprise the bony nasal root. The nasal bones are thicker superiorly and often times have asymmetrical overall length, which may have clinical relevance when performing osteotomies (Figure 1). The upper lateral cartilages are adherent to the undersurface of the nasal bones and extend for a distance of 3 to 5 mm along their undersurface. Similarly, they underlay the lower lateral cartilages in the less adherent scroll area. The keystone area is important both esthetically and functionally and represents the union between the dorsal septum, nasal bones and upper lateral cartilages. When it is disrupted, as in trauma or inadvertently during osteotomies, it needs to be reconstructed to

reestablish nasal support in the region and to maintain the natural appearing dorsal esthetic lines running from the medial brow to the nasal tip.

The internal nasal valve is the junction between the caudal border of the upper lateral cartilages and the septum and generally must be at least 15° to maintain adequate nasal function. The paired lower lateral cartilages comprise the medial, intermediate (middle), and lateral crura. The shape, size, and strength of the lower lateral cartilages have profound effects on the shape, rotation, projection, and function of the lower one-third of the nose. In addition, a number of fibrous attachments to surrounding structures can alter tip support and projection including: connections to the upper lateral cartilages, suspensory ligament of the dome, medial crural ligaments and attachments to the caudal septum.<sup>7,8</sup>

### Facial harmony

Almost every human face has significant asymmetry between the 2 sides. Patients tend to be quite aware of any such asymmetries postoperatively and, thus, should be appropriately counseled preoperatively. Asymmetrical faces may be appealing. However, certain facial proportions are felt to be inherently considered attractive across cultural and ethnic lines. In the vertical dimension, the face is divided into thirds, with the width of the mouth positioned centrally and equaling the distance between the medial limbi of the cornea. The distance from the base of the nose to the infraorbital rim is equal to the width of the nasal base and

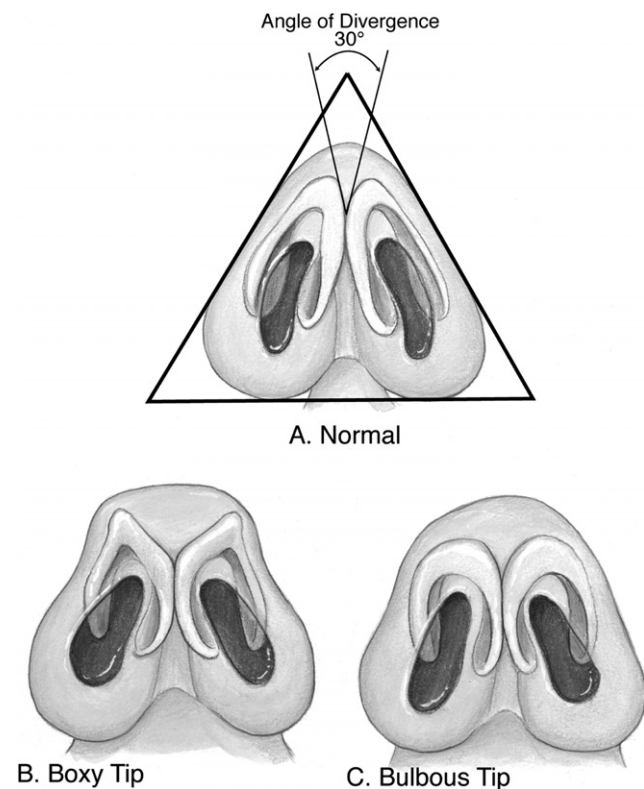


Figure 3 Tip types: (A) normal tip; (B) boxy tip; and (C) bulbous tip.

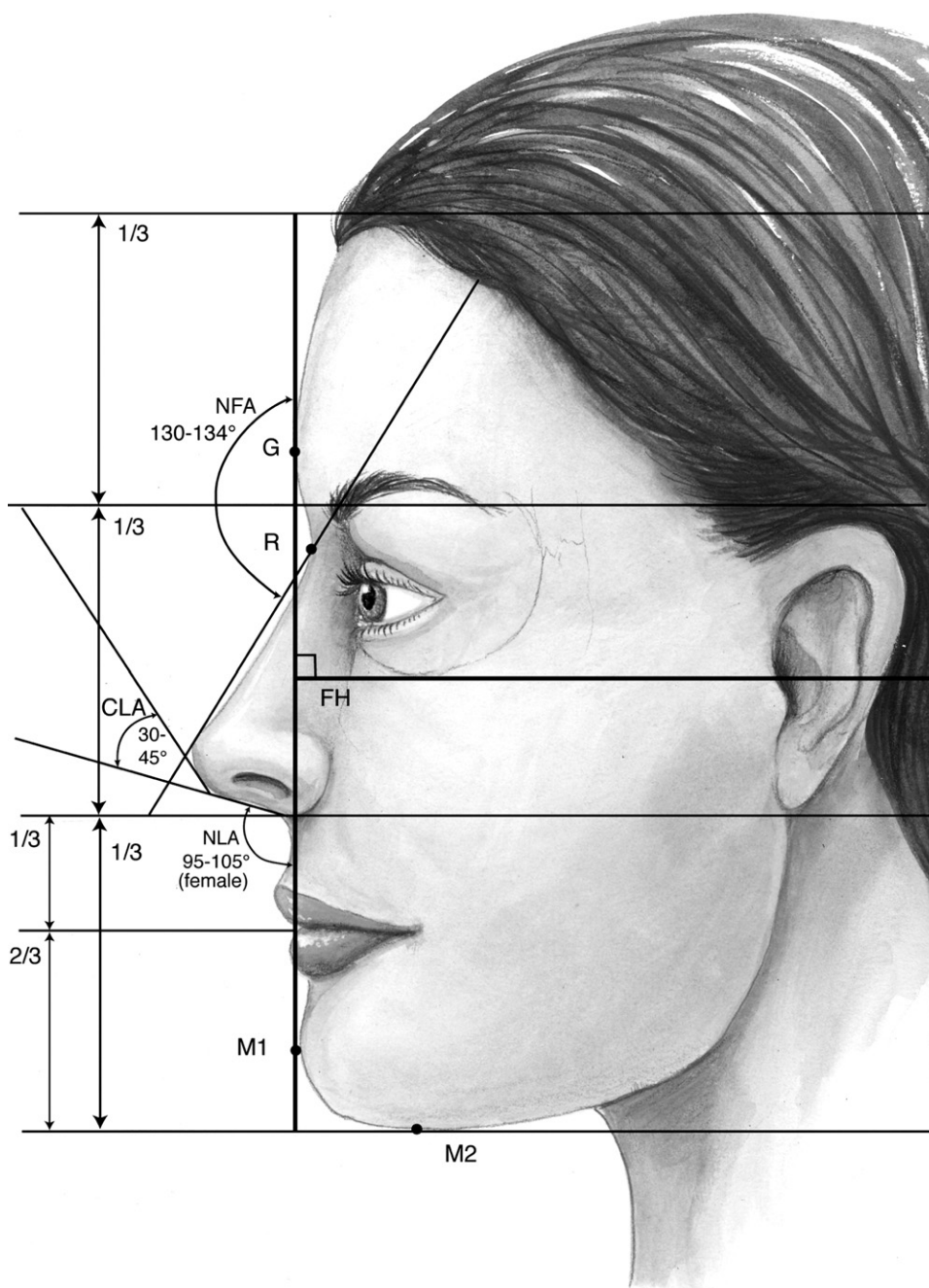
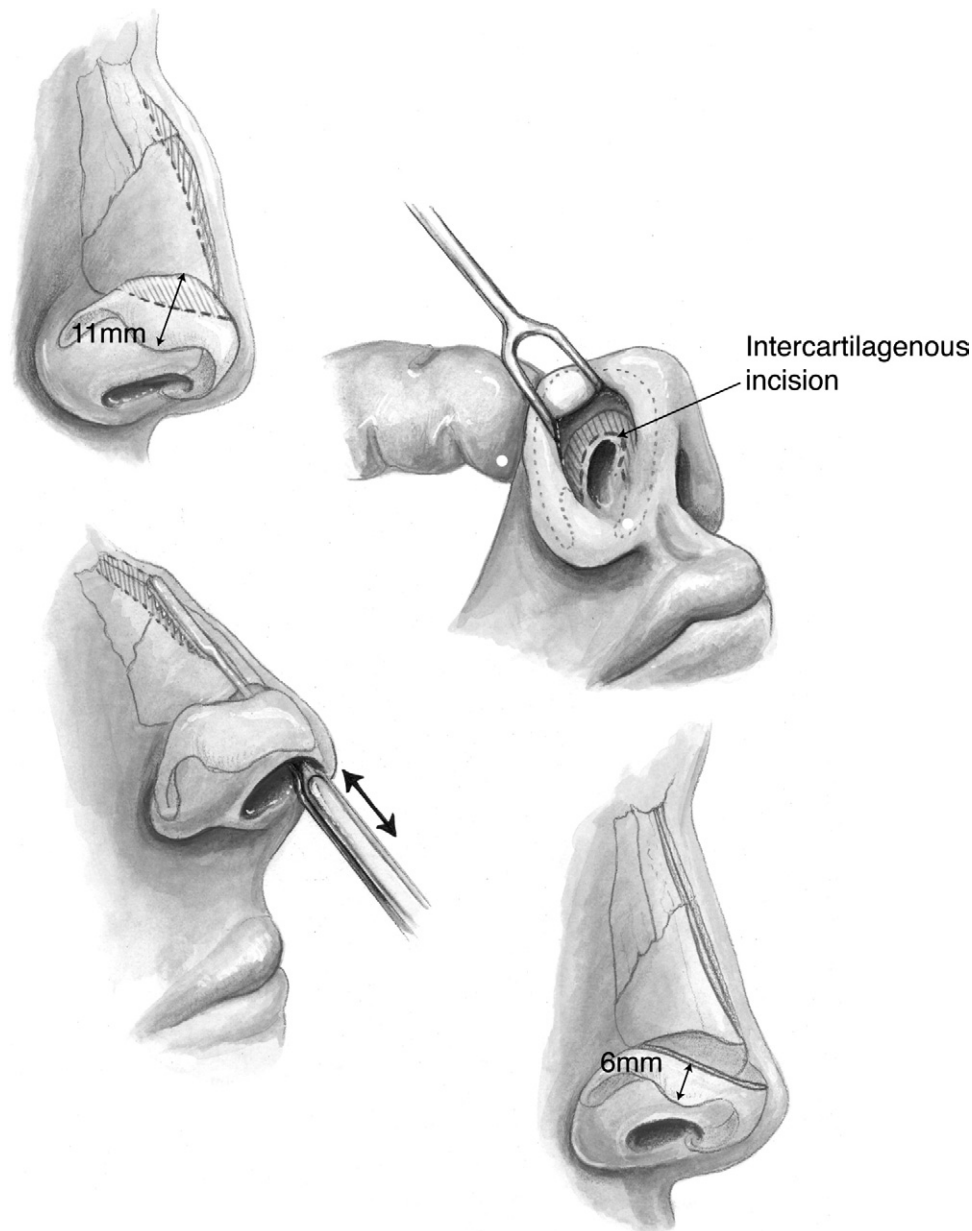


Figure 4 Preoperative analysis: lateral view.



**Figure 5** Intercartilagenous incision.

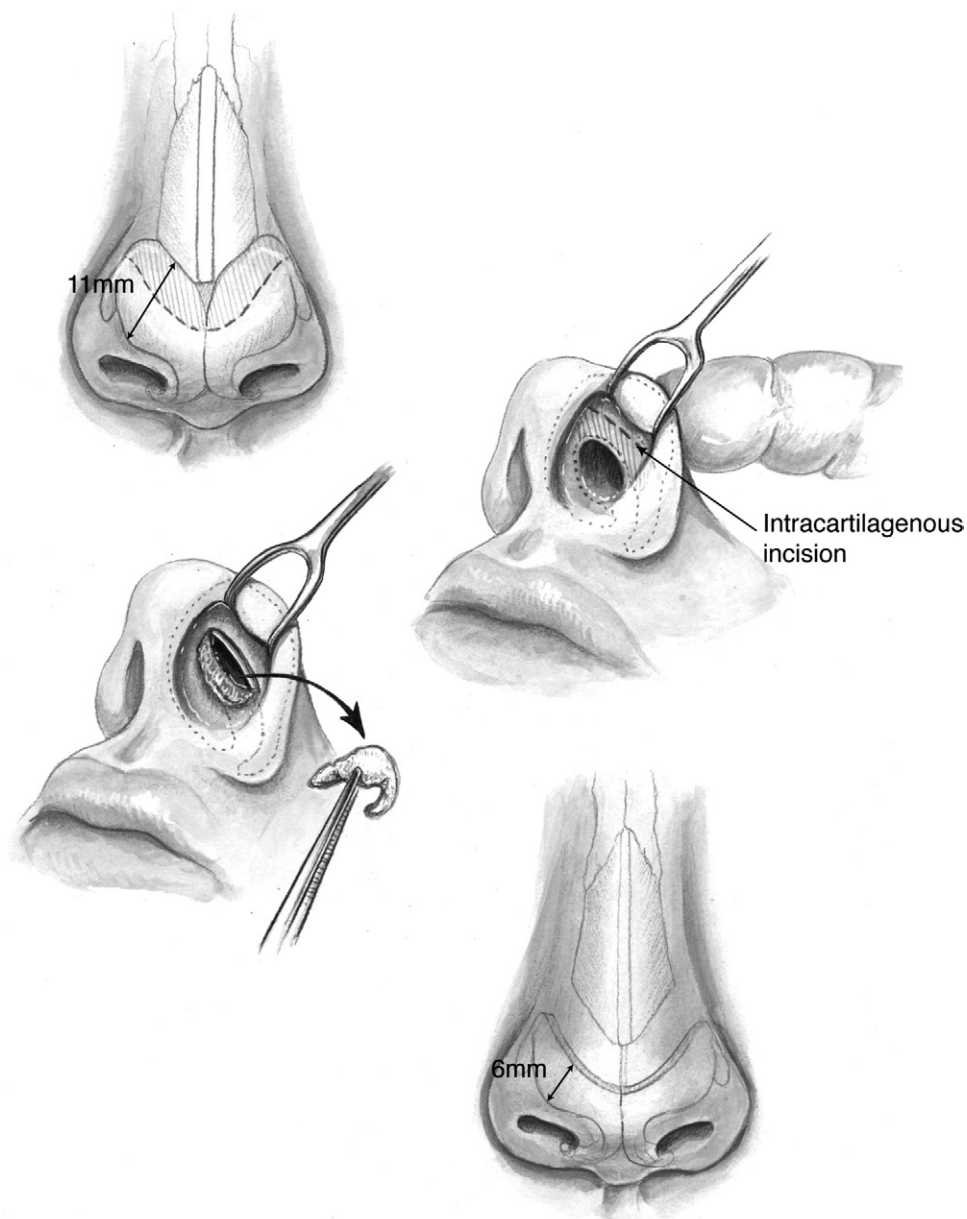
half the distance of the previously noted central third of the face. The width of the alar base should be equivalent to the intercanthal distance, which itself ideally approximates the width of the palpebral fissure.

In the horizontal plane, the face is divided into thirds by horizontal lines passing through the menton (most inferior aspect of the chin), the nasal base, the supraorbital rim and approximate position of non receded anterior hairline (Figure 2). The width of the mouth will approximate the distance from the stomion to the menton.

On the frontal view, the nasal tip region should have four visible landmarks: supratip break, columellar-lobular angle and two tip defining points. Connecting these points results in a symmetric baseball diamond configuration centered in the midline of the nasal tip. On basal view, the nose approximates an equilateral triangle with a 1:2 ratio between the lobular and columellar portions of the nose (Figure 3).

On profile view, the deepest portion of the nasofrontal angle should be at the upper lash line and supratarsal fold

(Figure 4). Assuming normal upper lip projection, a vertical line drawn through the most projecting portion of the upper lip will help define the adequacy of nasal tip projection. Adequate projection will be associated with 50 to 60% of the nasal tip lying anterior to this line. Nasal length may be correlated to nasal tip projection with a normal ration approximating 1:0.67. In females, the nasal dorsum should lie approximately 2 mm posterior and parallel to a line drawn from the nasofrontal angle to the most anterior point of tip projection. Males should generally approximate this line. The nasolabial angle is defined as the angle between a line drawn through the most anterior and posterior points of the nostrils (on lateral view) and a perpendicular line dropped from the natural horizontal facial plane. Rotation is determined by the degree of the nasolabial angle. It should generally be between 90 to 100°, with the higher end preferred for most females and the lower end of the spectrum preferred for most males. Patient height and surrounding facial features will determine ideals in this regard.



**Figure 6** Intracartilagenous incision.

## Technique description

### Technique of closed rhinoplasty

With closed rhinoplasty, there is generally not the same degree of disruption of soft-tissue support as is seen in open techniques. Although visualization is inferior as compared with these latter techniques, one can achieve tremendous beneficial changes in appearance with improvement of the airway by applying and maintaining a strict adherence to certain principles. The goal of modern rhinoplasty is conservative natural appearing rhinoplasty.

In closed techniques, I generally prefer to address any bony vault and septal deformities before addressing the cartilaginous lower half of the nose. Hump reduction is performed first with rasping technique for smaller humps and with a Rubin osteotome and touch up rasping for larger hump reductions (Figure 5). Subsequently, anatomic nasal osteotomies are utilized to correct any nasal root deviation

and close an open roof deformity utilizing percutaneous medial, lateral and transverse osteotomies.<sup>9</sup> Next, septoplasty is performed to address any nasal airway obstruction arising from septal deviation as well as to harvest cartilage grafts that may be needed for later augmentation while maintaining dorsal and caudal struts of approximately 1 cm to preserve septal support. If the caudal septum is trimmed for caudal deflection and to alter the nasolabial angle, it is important to maintain as much membranous septum as possible to maintain normal mobility of the lower one third of the nose following rhinoplasty.

The basic technique for standard closed rhinoplasty remains the transcartilagenous (intracartilagenous) approach (Figure 6). Need for grafting of the lower lateral cartilages, excess projection, unusually angulated crura or severely deformed alar cartilages are an indication for a cartilage delivery technique where these deformities may be directly visualized and addressed. Eversion techniques represent a nice method of addressing the fatty tip deformity.

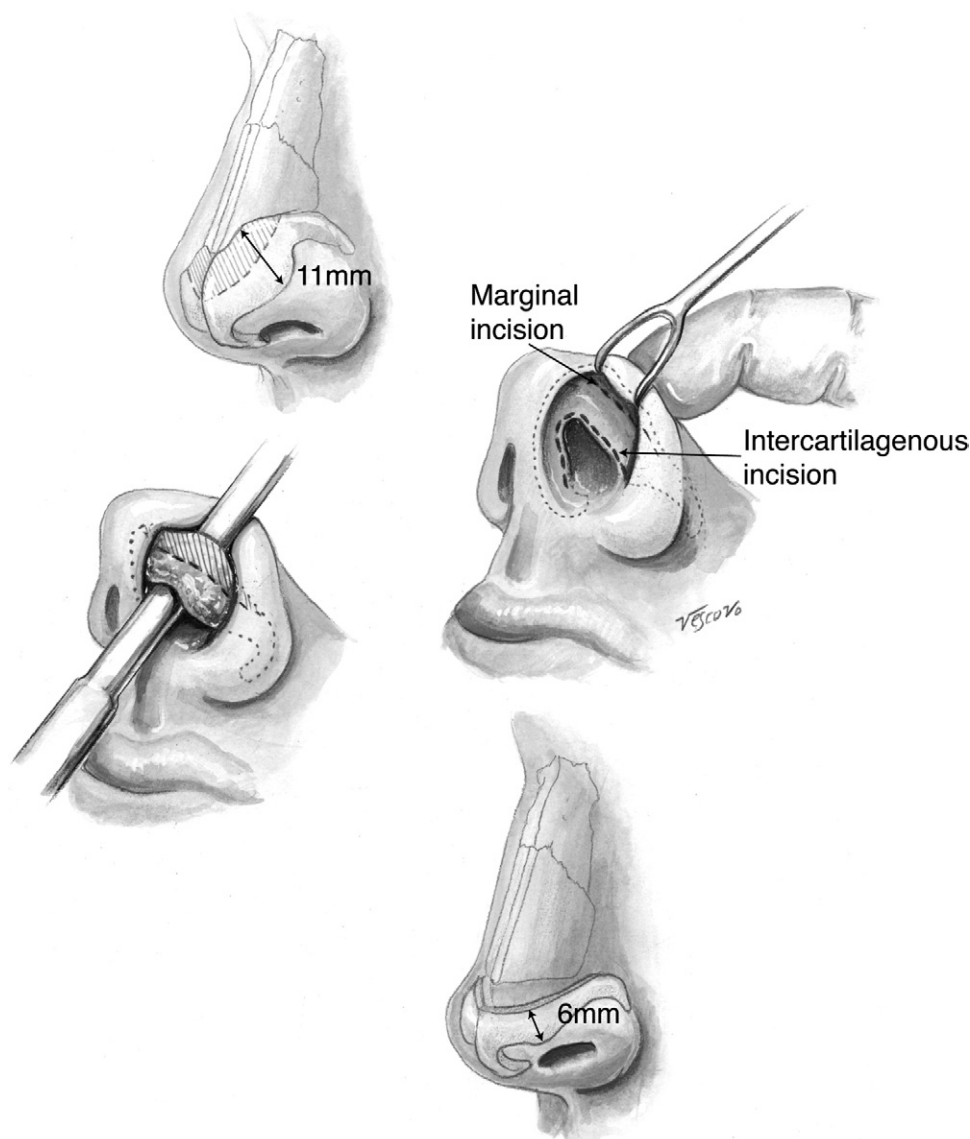


Figure 7 Delivery technique.

### The transcartilagenous technique

Generally, no more than one-third to one-half of the cephalic area of the lower laterals should be resected in most circumstances of widened lower lateral cartilages as there is some settling and further rotation that will happen naturally over time. This will result in esthetically pleasing refinement of the tip with rotation. Maintaining an intact strip of at least 5 mm is mandatory in most cases. Care should be taken to avoid any resection in the domal region as the cartilage narrows to 3 to 4 mm in many patients in this region. In a nose with a thickened nasal tip region, there is often a poorly defined crease present. A more pronounced crease may be created by extending the transcartilagenous incision laterally past the lateral aspect of the lower lateral cartilages toward the pyriform aperture in the direction and orientation of the desired crease.

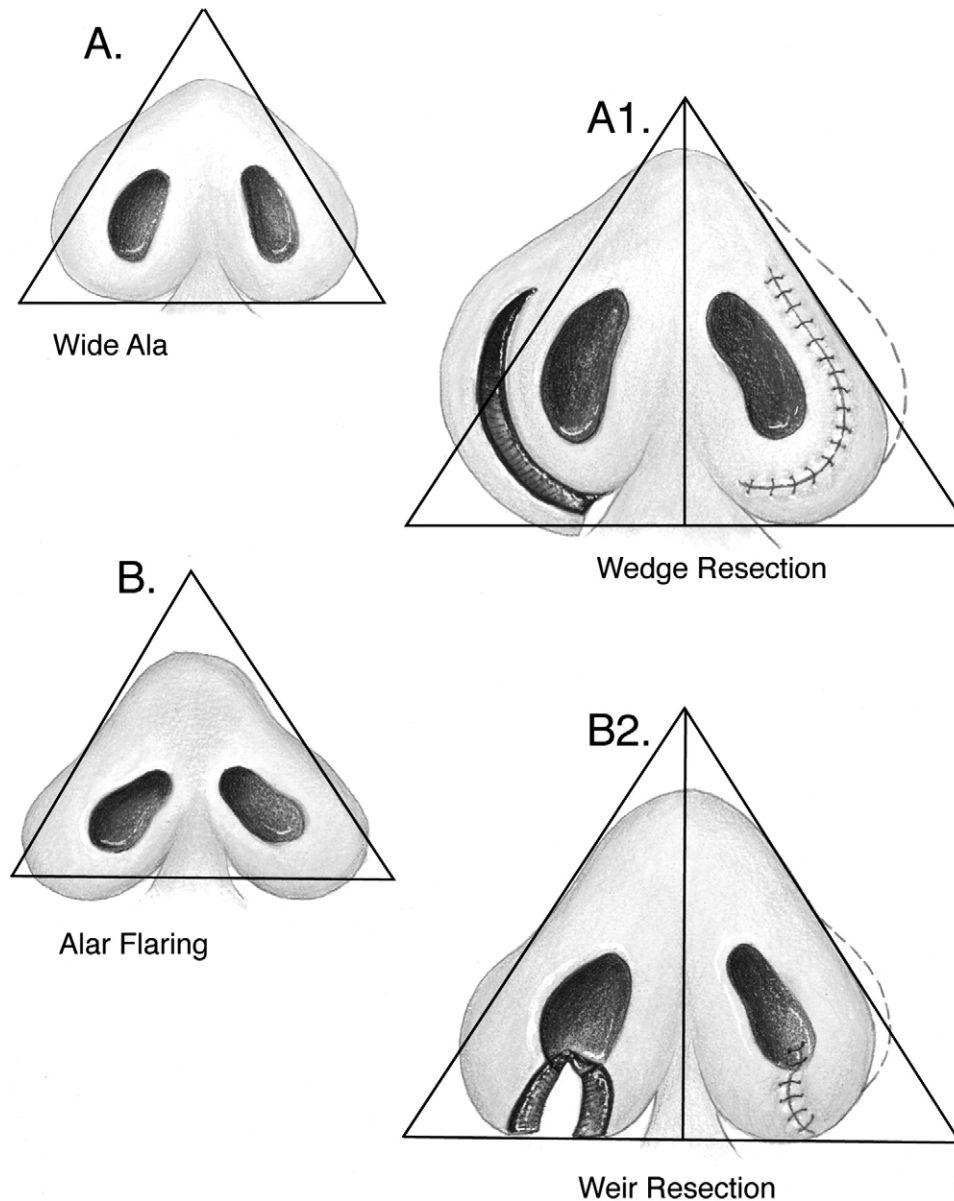
### The delivery technique

This allows for direct visualization of the lower lateral cartilages, equivalent to an open technique in most cases (Fig-

ure 7). Exposure is achieved with an incision along the caudal margin of the lower lateral crura continuing medially to the medial crus on each side. It may extend along the columella as required for exposure. It is important not to violate the soft triangle deep to the domes to prevent nostril notching postoperatively. An intercartilagenous incision is made allowing a bipediced flap to be delivered into the operative field to allow for necessary tip modification. The alar cartilages may now be refined with cephalic trim, intradomal, and interdomal sutures, and selectively weakened with cross hatching techniques.

### The eversion technique

Here, the caudal incision mirrors that seen in standard delivery techniques. However, rather than an intercartilagenous incision, a proximal cartilage splitting incision will allow eversion of the cephalic trim portion and access to the subcutaneous tissues of the overlying nasal skin for direct defatting in the unusual patient that requires this to be performed. There is some loss of projection with this technique and somewhat unpredictable scar deposition that may alter tip dynamics.



**Figure 8** Addressing the base: (A) Wedge resection; (B) Weir resection.

### Nostril modification

Alar rim grafts are nonanatomic grafts placed in a separate pocket along the caudal edge of the ala intranasally. They result in improved alar rim support, triangulation and are especially beneficial in correction of the boxy tip deformity and in alar rim asymmetries. Direct excision of elliptical wedges along the cutaneous inferior margin of the ala will decrease their bulk and thickness (Figure 8). Care must be taken in fair skinned individuals due to potential scar visibility. Alar wedge excisions may correct alar flaring and improve alar base width.

### Tip grafting

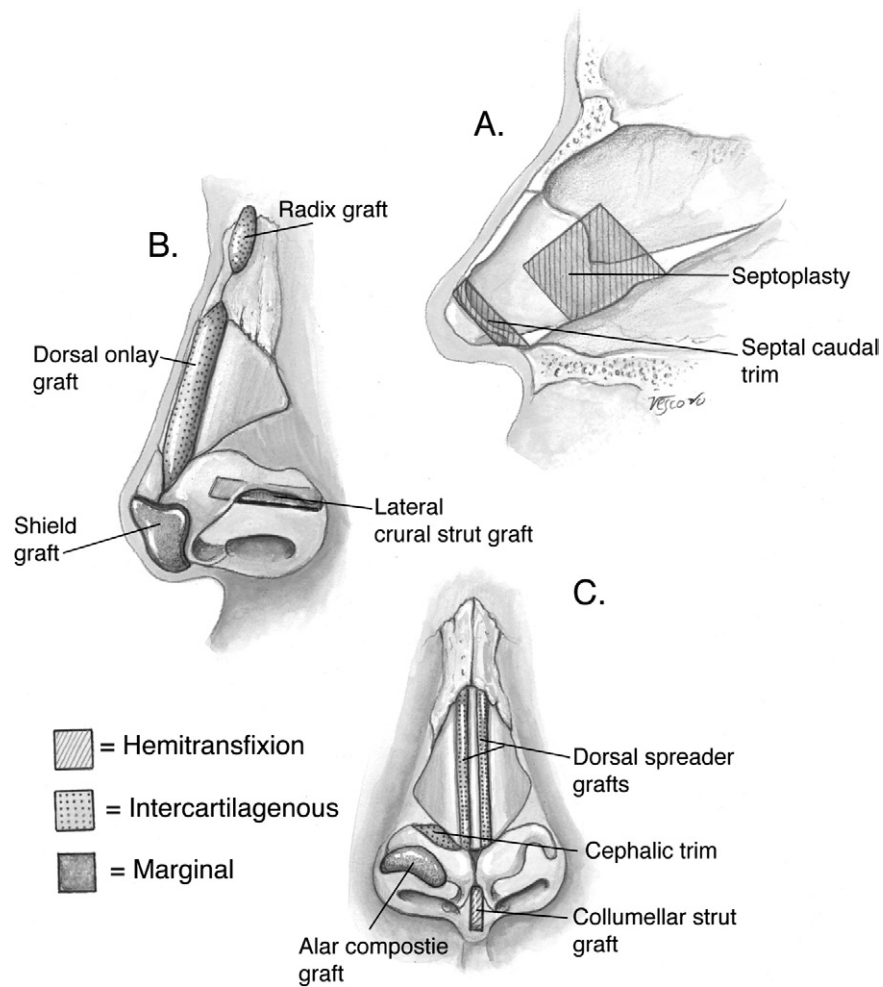
This should be used judiciously to increase tip projection and refinement in cases of thick skin, Polly-beak deformities, revision rhinoplasty in cases of overly resected primary surgeries, nasal tip hypoplasia, the plunging tip and the cleft nasal deformity (Figure 9). Use in thin skinned individuals should only be performed with great caution. These grafts

may be placed in precise pockets, secured under direct visualization in delivery patients or secured via a transcutaneous temporary suture in the appropriate position. In general terms, broader, thinner grafts or multiple smaller grafts will leave the patient with a more natural long term result than thicker smaller grafts. Onlay grafts are powerful tools that may be useful in camouflaging contour irregularities over the remainder of the osseocartilagenous framework. Crushed or diced cartilage grafts placed in precise pockets without overcorrection appears to be associated with a favorable long term outcome in most patients.

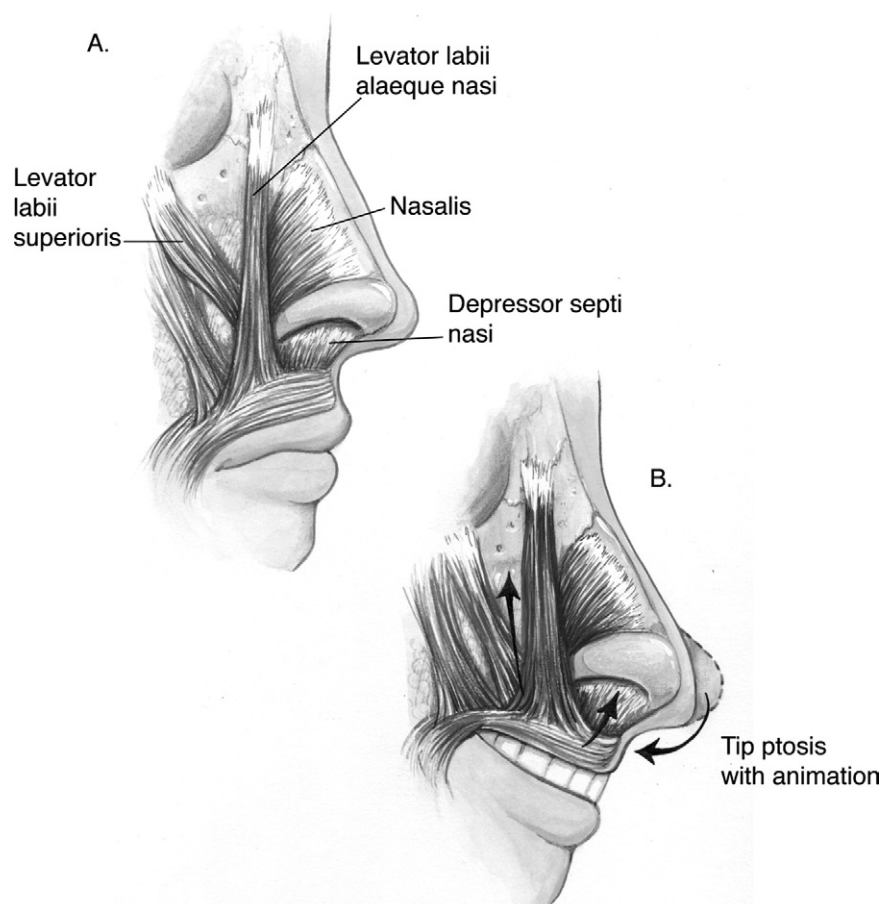
### The depressor septi muscle

This muscle may be released via an incision along the nasal floor or alternatively via an upper gingivobuccal incision in cases of excessive downward pull on the lower one third of the nose during smiling or animation (Figure 10). Excessive prominence or activity of this muscle is often





**Figure 9** Use of specific incisions to create discrete pockets for grafting: (A) lateral view; (B) three-quarter view; and (C) frontal view.



**Figure 10** Overactivity of the depressor septi will result in shortening of the upper lip and nasal tip ptosis.

seen in association with an abundant anterior nasal spine which may need to be reduced in this subset of patients.

## Conclusion

The closed rhinoplasty technique, if applied judiciously, continues to have an important role in modern corrective nasal surgery. Conservative reduction and appropriate patient selection is important as in any rhinoplasty patient.

## References

1. Denecke HJ, Meyer R: Plastic Surgery of the Head and Neck. New York, Springer Verlag, 1967
2. Roe JO: The deformity termed pug nose and its correction by a simple operation. *Med Rec* 31:621-625, 1887
3. Joseph J: Nasenplastik und sonstige gesichts plastic. Leipzig, Germany, Curt Kabitzsch, 1931
4. Rohrich RJ, Gunter JP, Friedman RM: Nasal tip blood supply: An anatomic study validating the safety of the transcolumellar incision in rhinoplasty. *Plast Reconstr Surg* 13:795-799, 1995
5. Anderson J, Rossing N, Drzewiecki KT: Preoperative cutaneous lymphoscintigraphy in malignant melanoma. *Cancer* 63:77-82, 1989
6. Ducic Y, Hilger PA: The role of ethmoid sinus surgery in the treatment of the twisted nose. *Rhinology* 36:20-23, 1998
7. Janeke JB, Wright WK: Studies on the support of the nasal tip. *Arch Otolaryngol* 93:458-461, 1971
8. Adams WP, Rohrich RJ, Hollier LH, et al: Anatomic basis and clinical implications for nasal tip support in open versus closed rhinoplasty. *Plast Reconstr Surg* 103:255-261, 1999
9. Cochran S, Ducic Y, Defatta R: Rethinking nasal osteotomies: An anatomic approach. *Laryngoscope* 117:662-667, 2007