

Effective Step-by-Step Technique for the Surgical Treatment of Protruding Ears

Yadranko Ducic, MD, FRCSC, and Peter A. Hilger, MD, FACS

Abstract

Objective: Techniques of otoplasty may be arbitrarily divided into cartilage-molding or cartilage-splitting categories. In this article, we describe our personal experience in over 100 otoplasties using a combination of these two methods. We highlight the step-by-step approach, as well as a number of previously unreported techniques, that have enabled us to consistently achieve permanent, esthetically pleasing results in both younger patients, as well as in older adults.

Sommaire

Objectif: Les techniques d'otoplastie peuvent être arbitrairement divisées en deux catégories: remodelage ou incision du cartilage. Cet article présente notre expérience personnelle de cent otoplasties en utilisant une combinaison des deux techniques. Nous décrivons notre approche par étape ainsi qu'un nombre de manoeuvres jamais rapportées auparavant, qui nous permettent d'obtenir des résultats reproductibles, permanents et esthétiques autant chez les enfants que les adultes.

Key words: lop ear, otoplasty, plastic surgery, protruding ears, technique

Unlike the periorbital and perioral areas, the auricle is normally not an esthetic highlight of the face. Thus, a basic goal of otoplasty is the return of the protruding ear into a more "normal," and consequently less noticeable anatomic position. Surgical correction of the protruding ear deformity is one of the most common reconstructive procedures performed in otolaryngology and facial plastic surgery. To avoid the inevitable teasing with the potential for subsequent adverse psychological consequences, most patients are brought to the attention of the surgeon when the child is 4 to 6 years of age. However, it is not unusual for an individual to reach adulthood before considering otoplasty. The essential deformity and its correction are similar across the age groups, except for the more malleable nature of a child's cartilage.

Although the precise anatomic configuration of the protruding ear will often vary among individuals, and indeed, often between the two sides of the same individual, there are certain common features present in most affected patients. The vertical axis of the protrud-

ing ear is inclined greater than 30 degrees posteriorly (normal is less than 30 degrees of posterior inclination), there is a relative excess of conchal cartilage present, and there is variably poor definition of various anterior landmarks, most notably, the antihelical fold and scapha.¹ Esthetically pleasing results may only be attained by addressing all of these elements. However, some patients will have isolated deformities of only one of these elements, thus requiring only relatively minor procedures to achieve natural-appearing results.

In 1845, Dieffenbach² described the correction of the protruding ear deformity using the techniques of postauricular skin excision and conchomastoid suture fixation. Subsequently, Ely³ was the first surgeon to define how surgical alteration of auricular cartilage would be beneficial in altering auricular prominence. In attempting to restore a natural-appearing antihelical fold, Lockett⁴ was the first to describe a cartilage-breaking technique, in which he excised medial skin and cartilage along the entire length of the new antihelical fold.⁴ Numerous modifications based on these foundational techniques of otoplasty have since been described.⁵⁻¹⁰

In this article, we describe the step-by-step technique that we have used extensively in 100 consecutive otoplasties to achieve permanent esthetically pleasing results in our patient population.

Technique

Prior to commencing correction, it is important to thoroughly analyze the precise anatomic variants that need to be specifically addressed (Table 1). Otoplasty

Received 1/9/98. Received revised 8/23/98. Accepted for publication 9/8/98.

Yadranko Ducic: Department of Otolaryngology, University of Texas SouthWestern Medical Center, Dallas, Texas; Division of Otolaryngology and Facial Plastic Surgery, John Peter Smith Hospital, in Fort Worth, Texas; *Peter A. Hilger:* Department of Otolaryngology, University of Minnesota, Minneapolis, Minnesota.

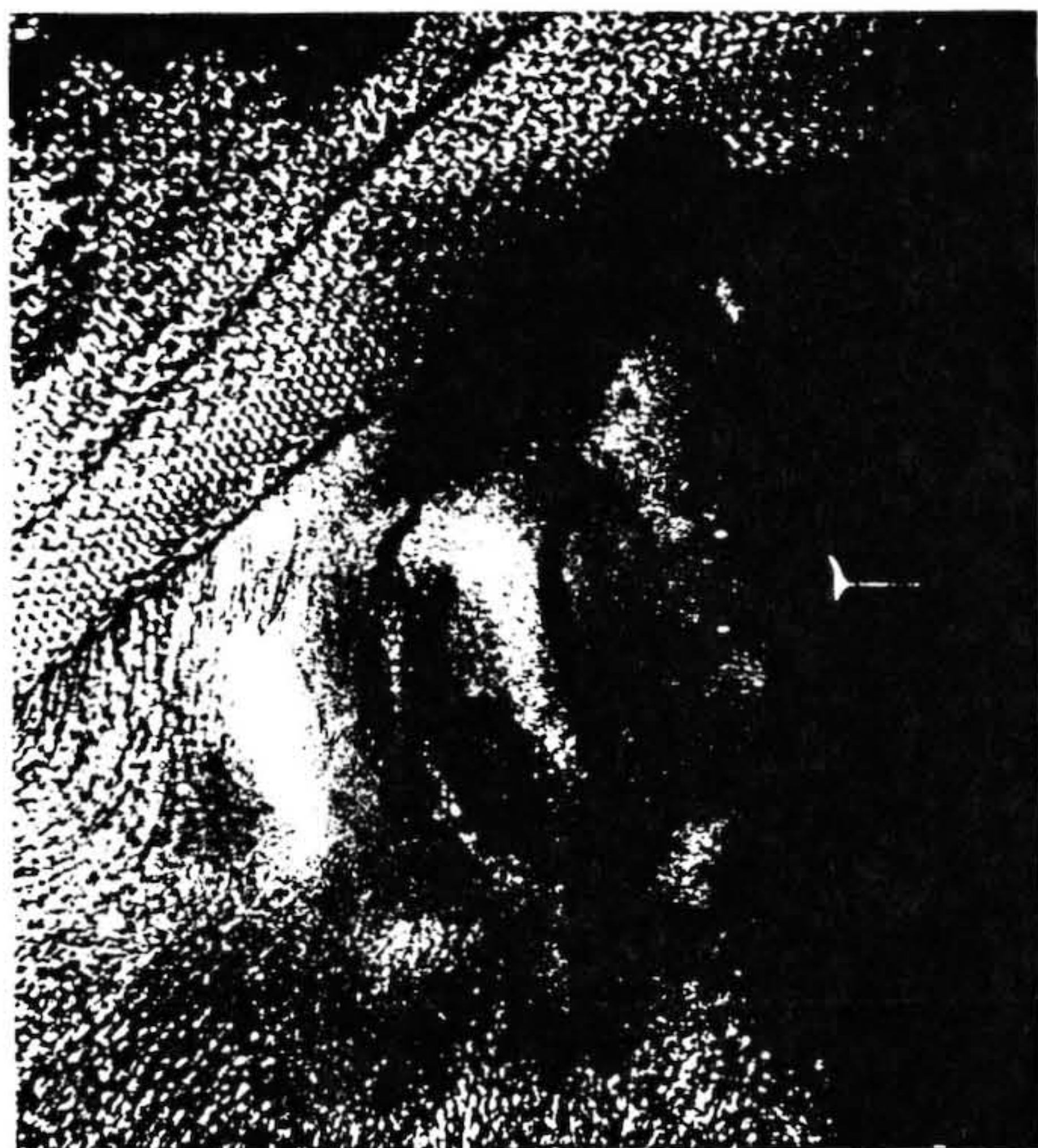Address reprint requests to: Dr. Yadranko Ducic, Director, Otolaryngology and Facial Plastic Surgery, 1500 South Main Street (JPS), Fortworth, TX 76104.

Table 1 Preoperative Checklist

1. If there is lobular prominence, the initial elliptical skin excision should be extended to include the lobule.
2. If there is a prominent upper third of the auricle, the initial elliptical skin excision should be extended well into this area.
3. When there is conchal bowl excess, cartilaginous disks should be shaved from this area until a positive "stick" test is noted.
4. In the case of a poorly defined antihelical fold, mattress sutures and cross-hatching will be required to create a neofold.
5. Always close the postauricular incision in two layers after conchomastoid suture fixation.
6. Dressing should include a Betadine ointment-cotton custom bolster and cotton head wrap for a period of 1 week.
7. A headband (both protective and supportive) should be used for 3 weeks after removal of the operative dressing.

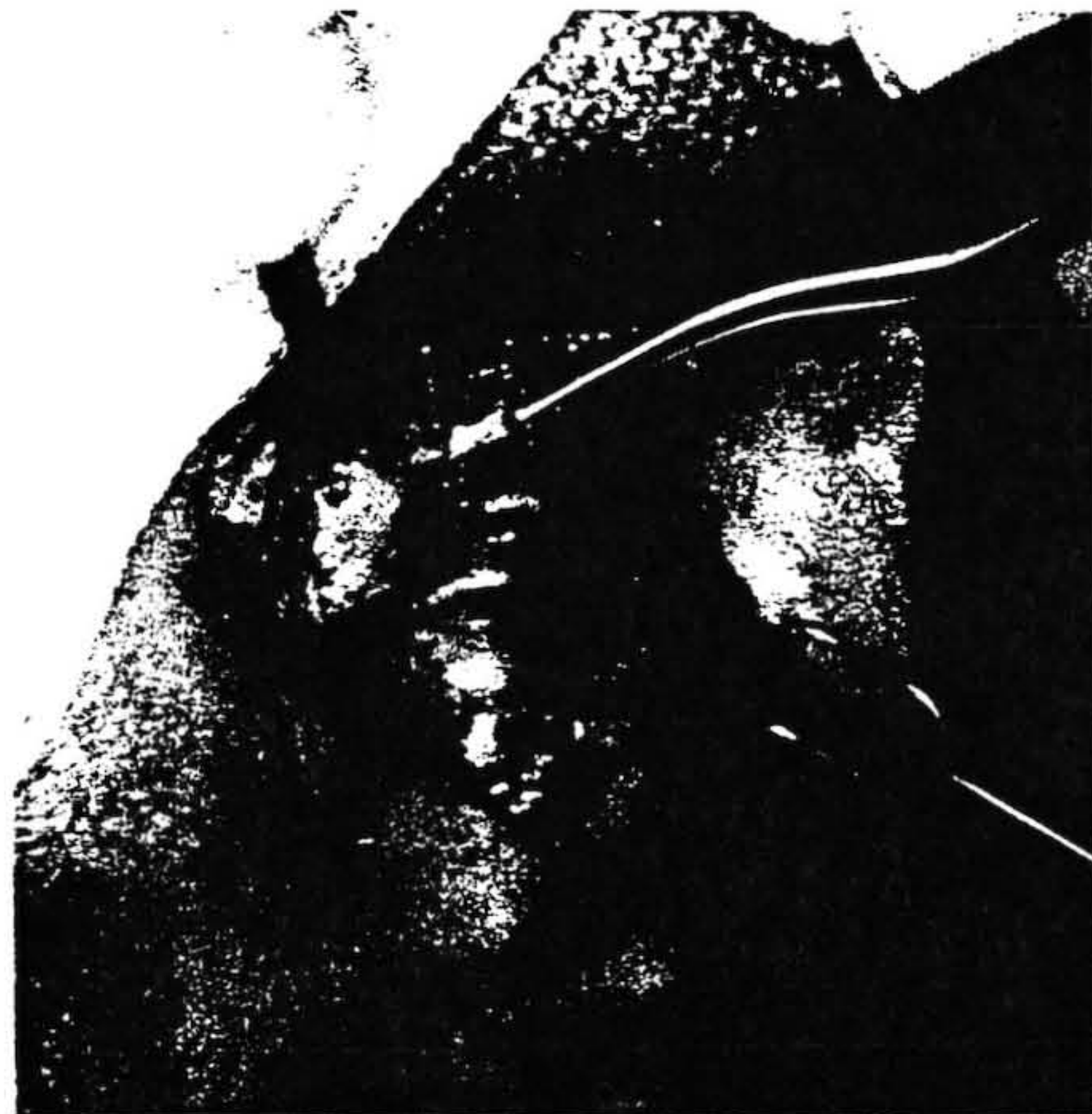may be performed equally well under general anaesthesia, local anaesthesia with sedation, or simply local anaesthesia. The former methods are most appropriate for younger patients, whereas the latter usually suffices for the majority of adults. In either case, the auricle is infiltrated with 1% lidocaine with 1:100,000 epinephrine solution.

First, the surgeon needs to determine the degree of prominence of the upper third and the lobule. Prominence in these areas needs to be addressed by extending the initial curvilinear elliptical skin excision into these specific areas (Fig. 1). The more significant the degree of prominence present, the greater should be the exten-

**Figure 1** Skin markings delineating an elliptical skin excision.

sion of the skin excision into them. Generally, a 1.0 to 1.5-cm-wide strip of skin is excised from the postauricular area using a number 15 scalpel blade. At this point, electrocautery is used to remove a 1.0-cm-wide strip of premastoid subcutaneous tissue (taking care to leave enough tissue overlying the mastoid for later suture fixation) to allow the auricle to settle back more naturally after fixation (Fig. 2). Now, the ear is folded back to allow the determination of the degree of conchal cartilage excess present. As this is done, it becomes readily apparent which areas of conchal cartilage are impeding the setting back of the auricle. These contact points are reduced by shaving small disks of cartilage from the posterior aspect (Fig. 3). Once enough disks have been shaved, the auricle will momentarily "stick" to the premastoid fascia when folded back, as the forward tension on the auricle exerted by excess conchal cartilage has now been removed. This is a positive "stick" test.

After marking the desired site of the future antihelical fold on the anterior aspect of the auricle (if required), 27-gauge needles are passed through the demarcated line from anterior to posterior (Fig. 4). Once the needle tip has emerged posteriorly, methylene blue is applied to the tip as it is withdrawn. This will translate the anterior fold design into a series of accurate posterior markings. Applying the methylene blue to the needle tip prior to passing it through the auricle results in unnecessary smudging of the markings. At this juncture, a number 15 scalpel blade is used to score the line of posterior markings to weaken the cartilage in this area (Fig. 5). This localized weakening of the cartilage will allow for easier

**Figure 2** Removal of a 1-cm strip of premastoid fascia to allow the auricle to settle more naturally after conchomastoid fixation-suture placement.

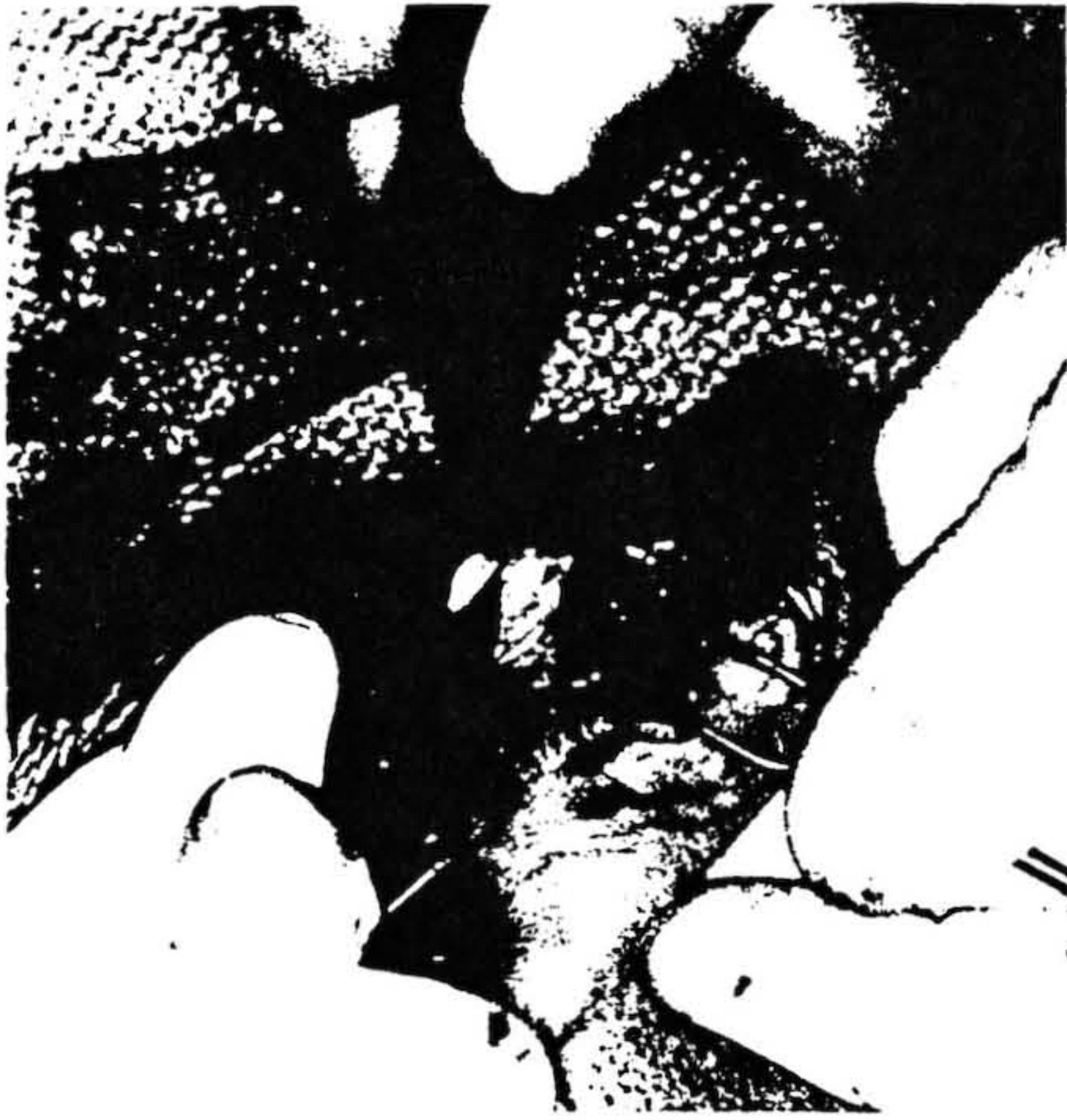

Figure 3 Excision of cartilaginous disks at "contact points." Contact points represent areas where the postauricular cartilage significantly abuts (or "contacts") the preauricular tissue when the auricle is pulled back. Removal of an adequate number of these disks is assured when the auricle momentarily "sticks" to the preauricular tissues when pulled back.

neo-antihelical-fold contour suture fixation. To facilitate placement of cartilage-molding postauricular sutures, one or two temporary 4.0 silk sutures are placed anteriorly

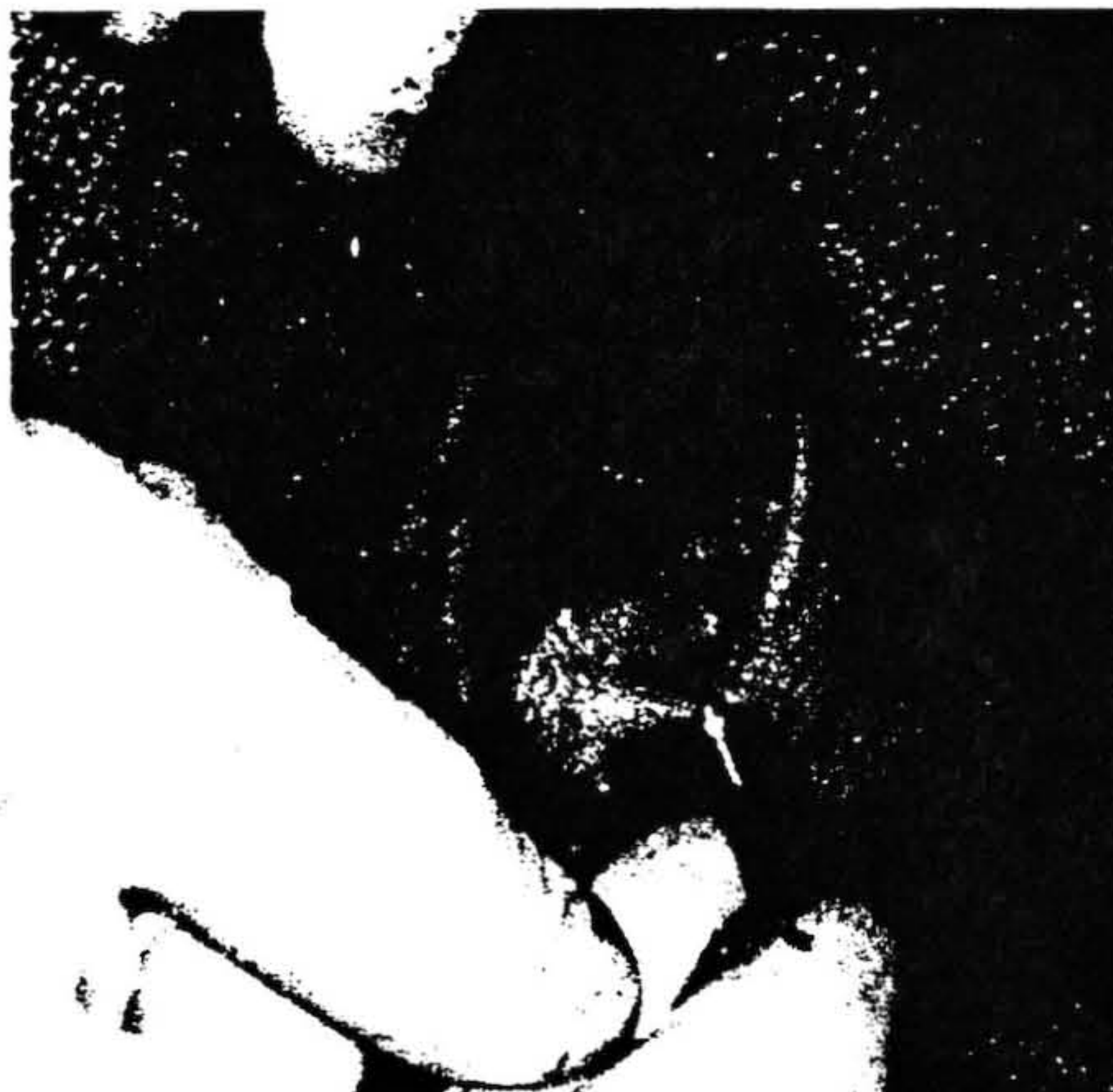

Figure 4 Passage of a 27-gauge needle from anterior to posterior along the planned site of the new antihelix. Methylene blue is applied to the needle tip prior to its removal. This effectively translates the anterior markings with a minimal of smudging.

only to give the desired antihelical fold definition (Fig. 6). Now, two to three 4.0 mersilene sutures are placed posteriorly in the neo-antihelical fold that is being held in position by the anterior silk sutures (Fig. 7). Once these posterior sutures are placed, the anterior silk sutures are removed. This technique very much facilitates and expedites the accurate creation of an antihelical fold.

At this point, a couple of 4.0 vicryl sutures are passed between the posterior aspect of the conchal bowl and the preauricular fascial remnant (Fig. 8). The skin incision may subsequently be closed with either a running 5.0 nylon or 5.0 mild chromic suture.

The key element of the dressing is the molded bolster, which effectively prevents hematoma formation and maintains the contours of the auricle in the immediate postoperative period. All that is required is a moderate quantity of Betadine ointment and cotton balls. These are then mixed together into a malleable mass, from which are derived three basic elements: a large conchal bowl piece, a linear scaphal piece, and an intermediate postauricular piece. These are then placed in situ without the need for suture fixation (Fig. 9). As the Betadine-cotton ball mold dries in the hours after the operative procedure (under the cotton dressing), it hardens and adheres to the underlying auricular skin, providing for reliable bolster-like effectiveness. The lack of suture fixation of this dressing allows for painless dressing removal, an obvious benefit for all patients, especially children. A standard cotton head wrap is then employed for 5 to 7 days postoperatively. It serves only a minor role in protection of the operated auricles.

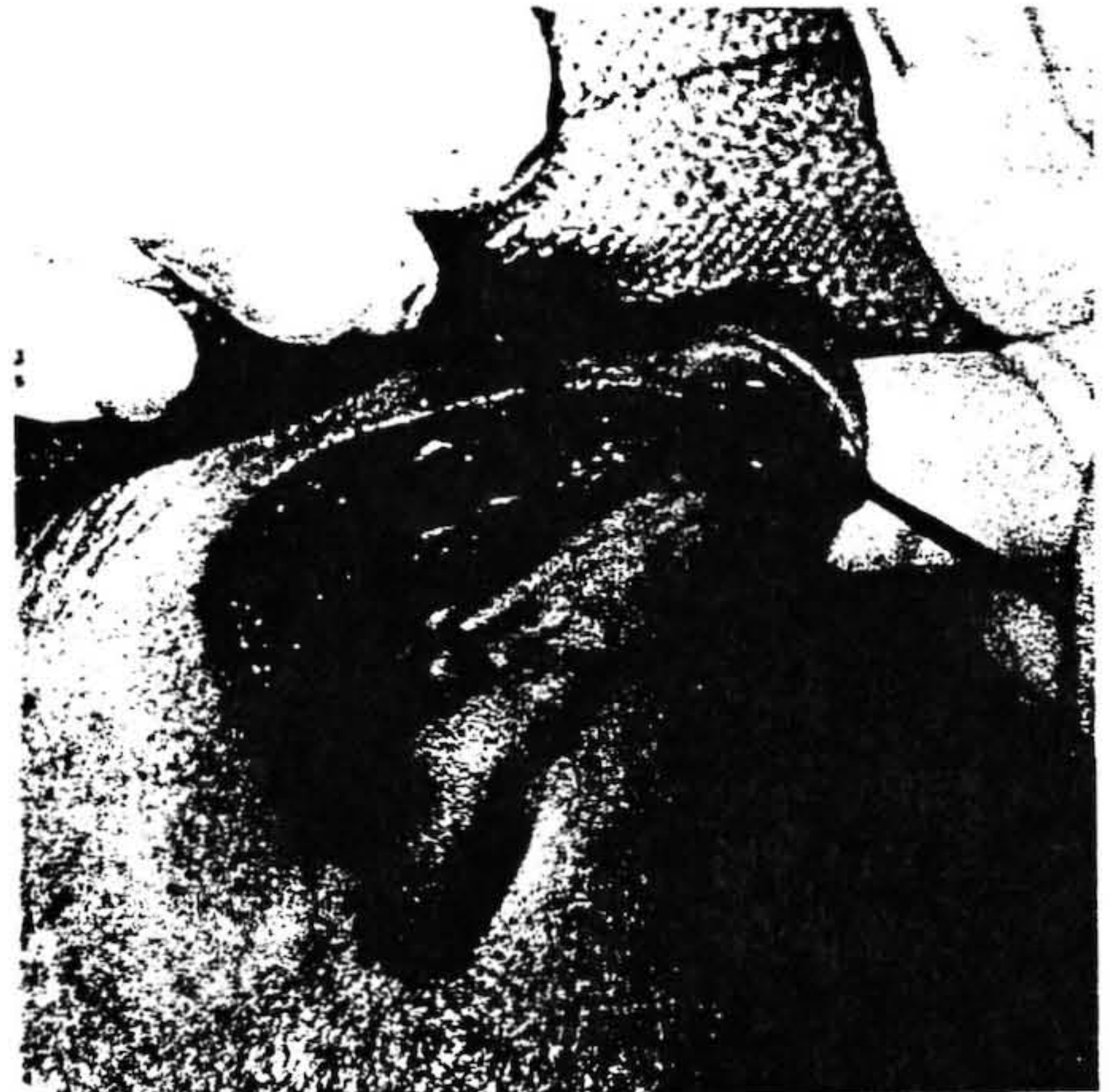

Figure 5 Cross-hatching along the posterior demarcations of the antihelical fold will facilitate curling of the antihelical fold with suture placement.



Figure 6 Placing temporary sutures along the anterior aspect of the antihelical fold allows for tension-free maintenance of desired fold position and contour while permanent sutures are placed posteriorly.

Its major purpose is to absorb any minor drainage in the immediate postoperative period and to serve as a not-so-subtle reminder to both the patient and anyone around him or her that he or she has had an operation, thus, hopefully, minimizing incidental contact. After dressing removal, we advise our patients to wear a sup-



Figure 7 Placement of permanent horizontal mattress sutures along the posterior aspect of the now-defined antihelical fold.

portive headband at least during the night for a period of 3 weeks.

Although the use of prophylactic oral antibiotics in otoplasty is unproven, all of our patients are given a 1-week prescription for a first-generation cephalosporin (cephalexin) as prophylaxis in the perioperative period. We have experienced no perichondritis or infections more serious than a stitch abscess in any of our patients. This may be due to either the oral antibiotics or the Betadine ointment dressing, or both. In either case, the combination appears to be effective in preventing infection.

With a minimum follow-up of 6 months, we have noted that none of our 100 consecutive patients has required major revision, and none has had complete relapse of their deformity. Only four of our patients have required revisional surgery. All such surgery was minor in nature, simply requiring fine tuning of one of the treatment methods detailed above. No significant relapse of prominent ears has occurred in our series. Using our moldable dressing technique, we have seen no hematoma formation or perichondritis. We have not seen the need to use drains in any of our patients.

Using the outlined technique, we have been able to achieve natural-appearing, esthetically pleasing results in our patient population (Figs. 10 and 11).

Discussion

Otoplasty is ideally a very rewarding procedure that significantly alters an affected patient's overall facial appearance. The most common complication following

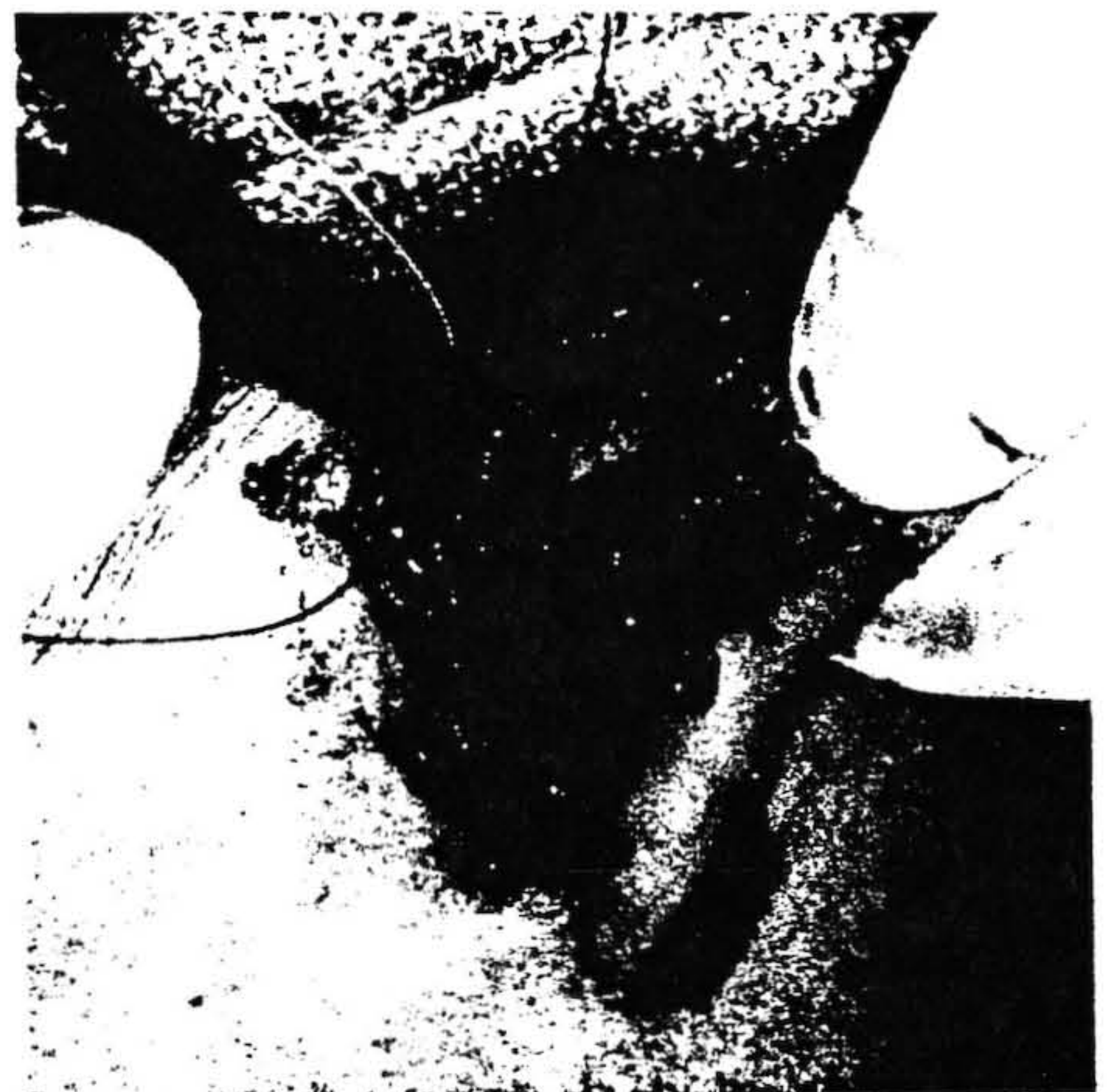

Figure 8 Conchomastoid suture fixation should be free of any tension, if the previous maneuvers were executed correctly.

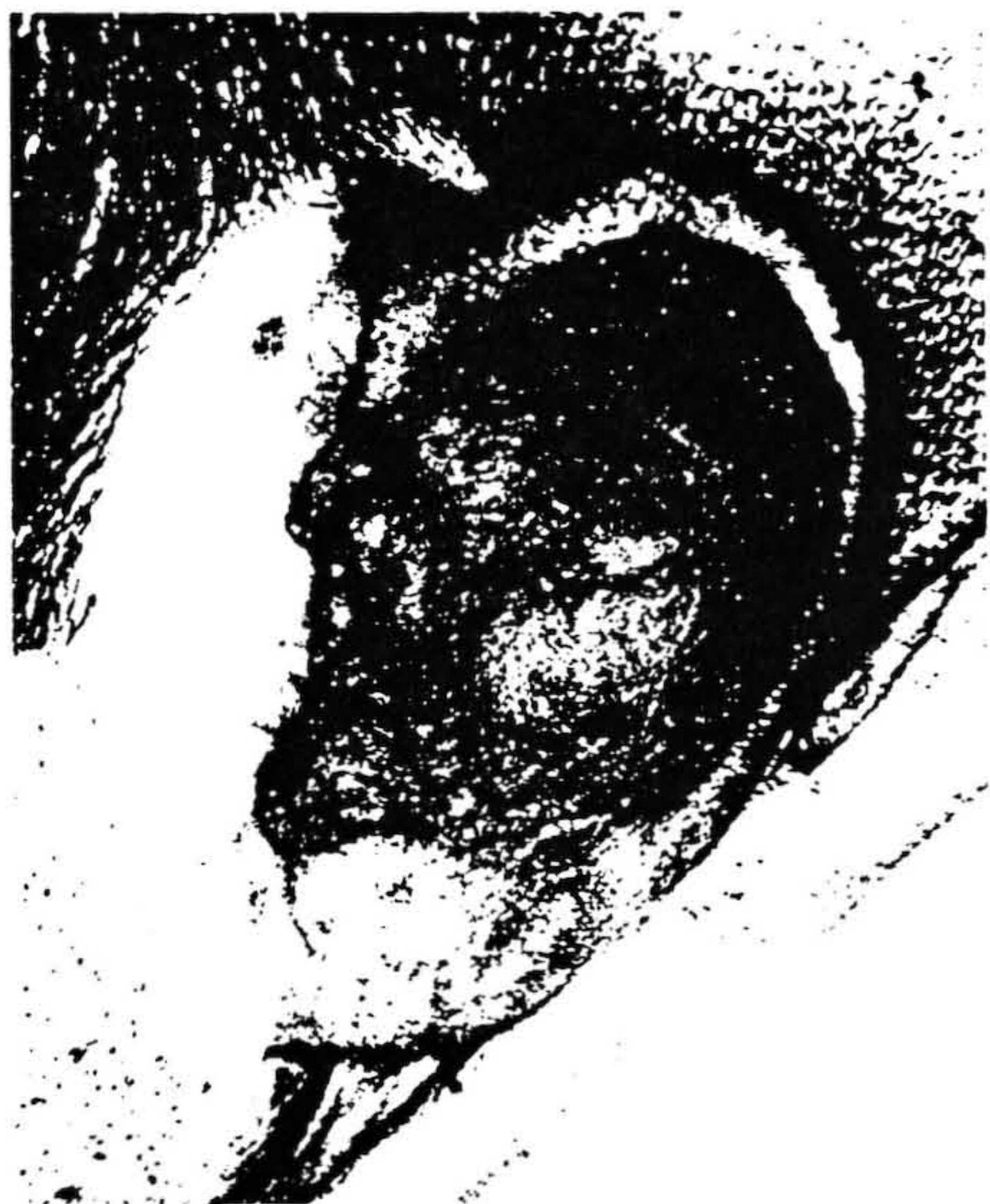

Figure 9 Moldable dressing in position.

surgical correction of prominent ears is a poor esthetic outcome resulting from either undercorrection or overcorrection. Often, inadequate correction follows incomplete assessment of the specific constellation of deformities that are present in the individual patient. Spira and

Stall have reported that some degree of retroprotrusion occurs in most ears corrected by a suture-only technique as a result of the phenomenon of cartilage memory. Indeed, fully one third of protruding ears have been noted to return to their original position.¹² We believe that most cases of retroprotrusion may be avoided by the judicious removal of an appropriate number of cartilaginous disks from the posterior aspect of the auricle. Removing enough of these contact points will allow the auricle to momentarily "stick" to the premastoid tissue bed. A positive "stick" test suggests that minimal amounts of tension will subsequently be exerted on the conchomastoid fixation sutures during the period of formation of the postauricular scar tissue that will provide for lasting correction. It is noteworthy that removal of the cartilaginous disks does not give rise to any obvious deformity visible on the anterior aspect of the auricle.

Rohrich et al.¹³ documented the effectiveness of horizontal suture placement for the creation of an antihelical fold in an animal model. We believe that scoring on the undersurface is a necessary requirement for the horizontal suture technique to achieve lasting results. The temporary anterior placement of sutures allows for simple and rapid maintenance of a tension-free antihelical fold, which can then be permanently secured in the desired position with the application of sutures along the posterior aspect of the antihelical fold.

In summary, we have found the outlined technique to be simple to teach and easy to apply. It has consistently resulted in favourable and lasting outcomes in our patient population.

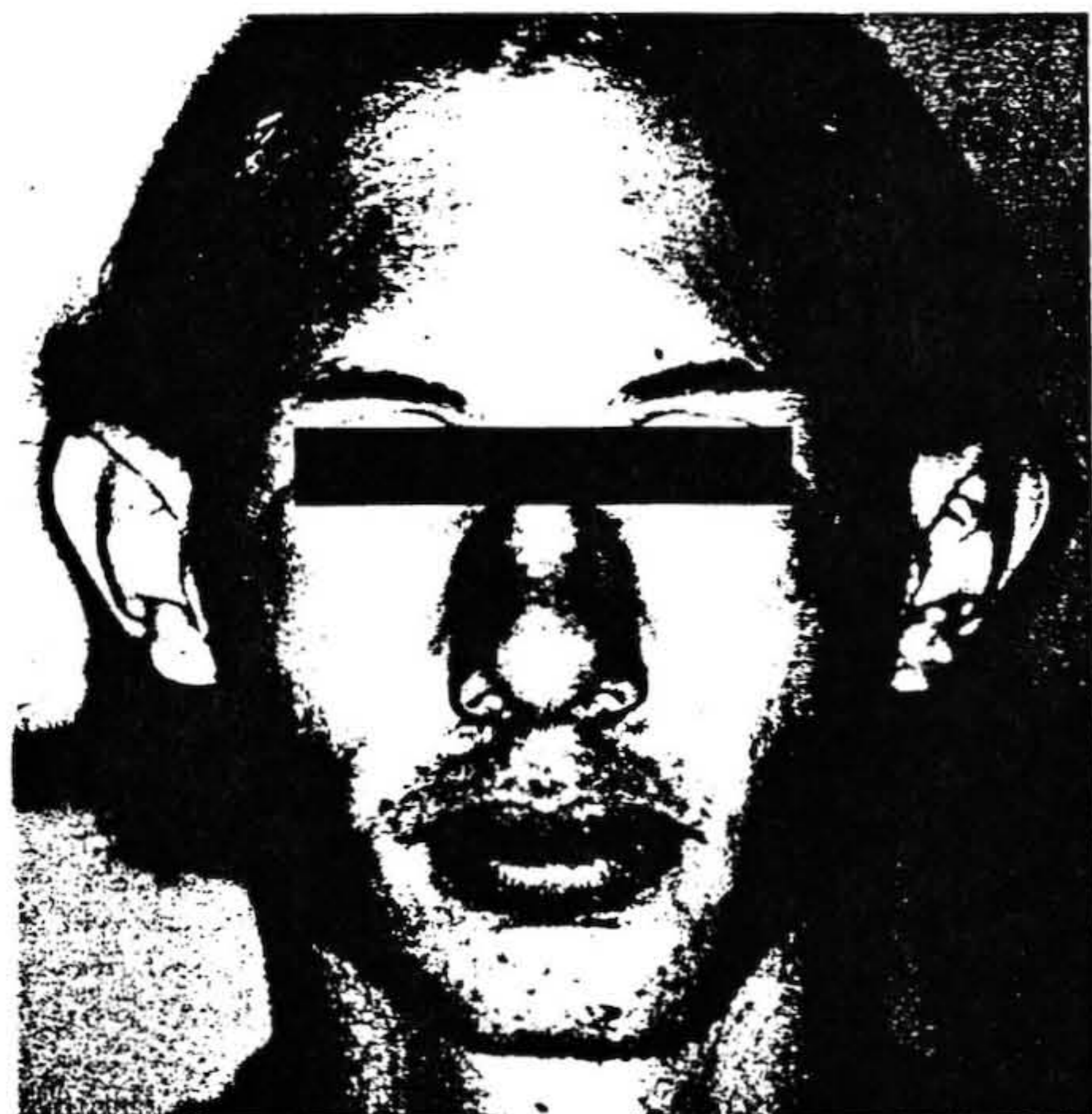

Figure 10 Frontal preoperative view of a 16-year-old patient with moderate prominence of both auricles.

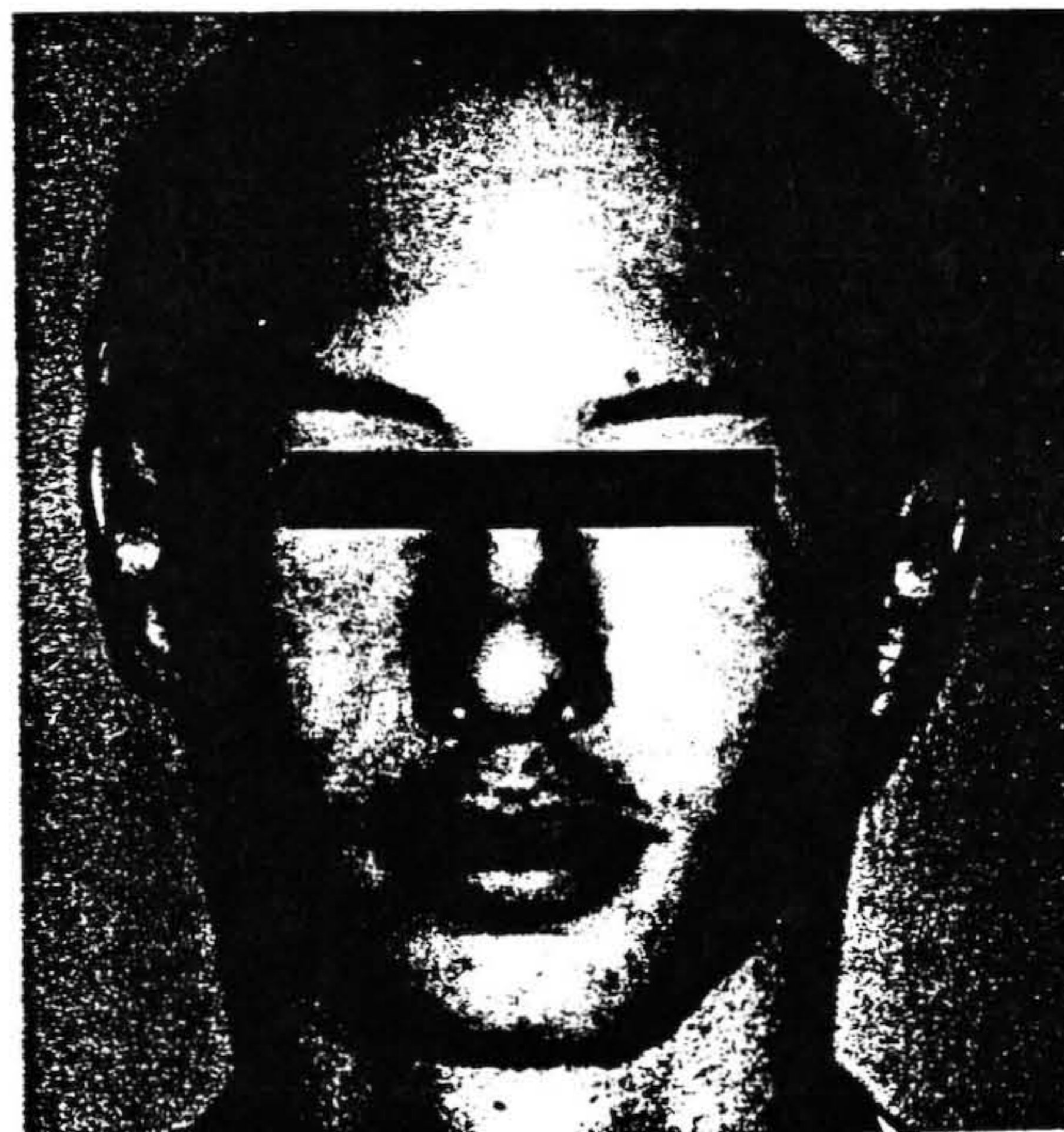


Figure 11 Postoperative frontal view of patient in Figure 10.

References

1. Farkas LG. Anthropometry of normal and anomalous ears. *Clin Plast Surg* 1978; 5:401-403.
2. Dieffenbach JE. *Die operative chirurgie*. Leipzig: FA Brockhause, 1845.
3. Ely E. An operation for prominence of the auricles. *Arch Otolaryngol* 1981; 10:97-99.
4. Lockett WH. A new operation for prominent ears based on the anatomy of the deformity. *Surg Gynecol Obstet* 1910; 10:635-638.
5. Farrior RT. Modified cartilage incisions in otoplasty. *Facial Plast Surg* 1985; 2:109-113.
6. Furnas D. Correction of prominent ears by conchomastoid sutures. *Plast Reconstr Surg* 1968; 42:189-191.
7. Nachlas NE, Duncan D, Trail M. Otoplasty. *Arch Otolaryngol* 1970; 91:44-47.
8. Tardy ME, Tenta L, Pastorek N. Mattress suture otoplasty: indications and limitations. *Laryngoscope* 1969; 79:961-963.
9. Bull TR, Mustarde JC. Mustarde technique in otoplasty. *Facial Plastic Surg* 1985; 2:101-104.
10. Becker O. Surgical correction of the abnormally protruding ear. *Arch Otolaryngol* 1949; 50:541-543.
11. Spira M, Stal S. The concha flap: an adjunct in otoplasty. *Ann Plast Surg* 1983; 11:291-294.
12. Messner AH, Crysdale WS. Otoplasty. Clinical protocol and long-term results. *Arch Otolaryngol Head Neck Surg* 1996; 122:773-777.
13. Rohrich RJ, Friedman RM, Liland DL. Comparison of otoplasty techniques in the rabbit model. *Ann Plast Surg* 1995; 34:43-47.

Endoscopic Sinus and Facial Plastic Surgery

Date: May 7-9, 1999

Location: Medical Sciences Building

University of Toronto

Toronto, ON

Study Credits: MOCOMP, AMA Category I

For further information please contact:

Continuing Education

Faculty of Medicine, University of Toronto

150 College Street, Room 121,

Toronto, ON M5S 3E2

Tel: (416)978-2719; Fax: (416)971-2200