

## Frontal sinus hamartomas

Raghu Athre, MD, Yadranko Ducic, MD, FRCS(C), FACS\*

*Department of Otolaryngology–Head and Neck Surgery at the University of Texas Southwestern Medical Center, Dallas, TX, USA  
Division of Otolaryngology and Facial Plastic Surgery at John Peter Smith Hospital, Fort Worth, TX, USA*

### Abstract

**Objective:** To review the entity of respiratory epithelial adenomatoid hamartoma of the paranasal sinuses using an illustrative case example of frontal sinus hamartoma.

**Methods:** Case report with review of the literature.

**Results:** Respiratory epithelial adenomatoid hamartoma represents a benign process that is generally cured with conservative surgical resection of the involved area. Nevertheless, as shown in our case example, this can be a locally aggressive process that can lead to significant morbidity if left untreated.

**Conclusion:** Hamartomas of the paranasal sinuses represent a rare entity, which should be considered in the differential diagnosis of expansile sinonasal lesions. Treatment of choice is surgical resection. Frontal sinus involvement may extend into the surrounding orbit and intracranial cavities, which may need to be addressed with standard skull base surgery techniques.

© 2005 Elsevier Inc. All rights reserved.

Hamartomas are nonmalignant lesions that represent congenital errors of tissue development. Albrecht first coined the term hamartoma in 1904 [1]. These lesions are characterized by an abnormal overgrowth of tissue elements indigenous to a particular area of the body. In most hamartomas, 1 or more of the cellular elements are expressed in excess [2]. Hamartomas do not clearly represent either a neoplastic or an inflammatory disorder.

In this article, we will review the clinical features associated with paranasal sinus hamartomas using an illustrative case example and review of reported patients.

### 1. Case report

EB is a 66-year-old white woman with no significant medical history. She takes no medications on a regular basis and has had no previous surgeries. She presented for evaluation and treatment of progressive right-sided proptosis and dystopia without diplopia or changes in visual acuity over the previous 6 to 9 months. Her review of systems was positive only for an increase in frequency and duration of frontal headaches, which the patient self-treated with

acetaminophen. The patient underwent a complete ophthalmologic examination, which was significant only for 6 mm of proptosis compared with the contralateral side.

Computed tomographic scanning scan findings revealed considerable proptosis of the right eye related to a large retrobulbar mass, which did not invade conal adipose tissue (Fig. 1). The mass showed considerable enhancement, but also appeared to be very slowly growing as evidenced by expansion rather than erosion of adjacent osseous structures. The presumed origin of the mass was the right frontal sinus, which displayed considerable expansion, including involvement of the posterior right orbital wall. The mass appeared to be mostly soft tissue in character with multiple calcifications. Radiological differential diagnosis included lymphoma, metastatic squamous cell carcinoma, mucocoele, fibrous dysplasia, neurofibroma, and optic nerve glioma. Because of the lack of bony destruction, the differential diagnosis led more toward a benign process.

The patient was taken to the operating room with the plan to undergo a right orbitocranial approach to resect the expansile mass. Examination intraoperatively revealed thinning of the roof of the right orbit due to extrinsic compression from the frontal sinus expansile mass.

A frontal craniotomy was performed to safely expose the posterior table of the frontal sinus and to facilitate subsequent cranialization. Removal of the anterior table of the frontal sinus revealed a large mass completely filling the

\* Corresponding author. Otolaryngology and Facial Plastic Surgery, 1500 South Main Street, Fort Worth, TX 76104, USA. Tel.: +1 817 927 1171; fax: +1 817 927 1605.

E-mail address: [yducic@sbcglobal.net](mailto:yducic@sbcglobal.net) (Y. Ducic).

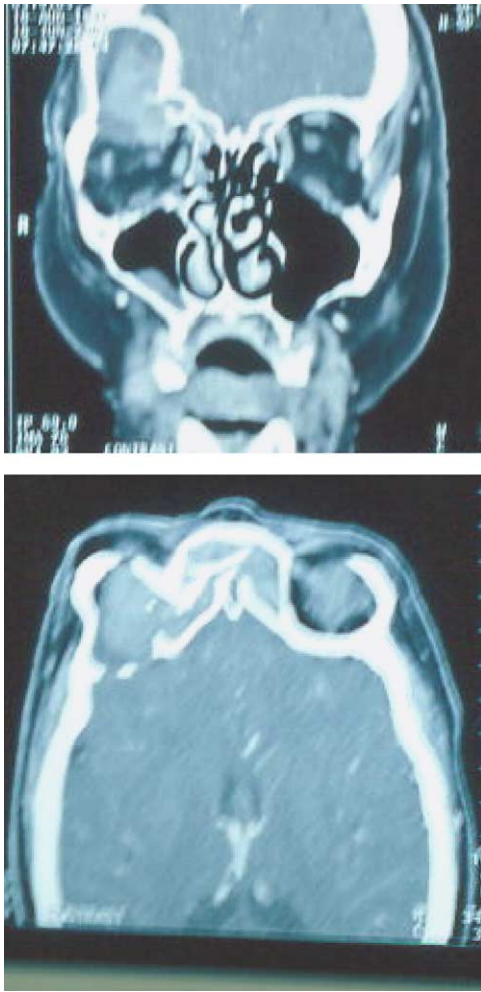


Fig. 1. Coronal and axial computed tomography scans demonstrating osseous expansion of the frontal sinus, extension of the soft tissue mass into the right orbit, and extension through the posterior wall of the frontal sinus.

frontal sinus and expanding into the anterior and middle cranial fossae, as well as into the right orbit.

The orbital roof was completely involved with the mass and was excised along with mass. The mass was removed

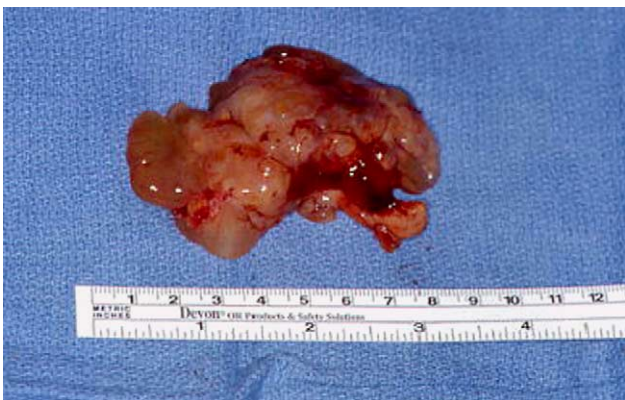

Fig. 2. Gross appearance of frontal sinus hamartoma demonstrating multicystic jelly-like consistency that was firm.

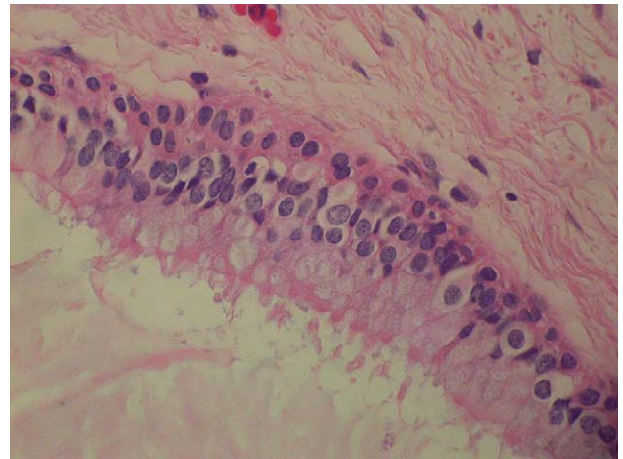


Fig. 3. Microscopic (hematoxylin-eosin stain, magnification  $\times 50$ ) demonstrating a benign, pseudostratified, ciliated, columnar epithelium. Underlying stroma is edematous. There is lack of mitotic activity with proliferation of seromucinous glands.

easily without adhesion to dura or surrounding structures. The mass had a jellylike consistency (Fig. 2).

The frontal sinus was cranialized and the orbital roof reconstructed using calvarial bone grafting. The intracranial and extracranial compartments were separated by a watertight closure using an extended pericranial flap. The patient's postoperative course was uneventful. Her proptosis was reversed, and she has had no evidence of recurrent or persistent disease.

Microscopic sections of the mass showed it to be multicystic, with the surface and most of the cyst spaces being lined by benign respiratory-type pseudostratified, ciliated, columnar epithelium (Fig. 3). Underlying stroma was edematous and contained widely separated stellate cells having small uniform nuclei without mitotic activity. Some of the cystic spaces were filled with inspissated mucoid secretions. No evidence of malignancy was noted on any of the pathological sections.

## 2. Discussion

Hamartomas are most commonly noted in the liver, kidney, and spleen but can occur in any part of the body. They represent malformations derived from excess proliferation of a specific cellular component of a given tissue that is normally found there, albeit in smaller quantities. Because they do not represent a malignant process, they do not have the capacity for spread. Generally, their growth is self-limited, and most of the resultant sequelae are secondary to mass effect rather than erosion and invasion [3]. This is in contradistinction to teratomas, which are capable of continuous growth and are composed of tissue elements from all 3 germ layers occurring in areas they are not normally noted.

Wenig and Heffner [4] described a subtype of hamartomas termed respiratory epithelial adenomatoid hamartoma

Table 1  
Hamartomas in the nasal cavity and paranasal sinuses

Year	No. of cases	Pathological diagnosis
1973 [6]	1	Vascular hamartoma
1978 [7]	2	Angiomatous hamartoma
1978 [7]	1	Lipomatous hamartoma
1981 [8]	1	Vascular hamartoma
1987 [9]	1	Hamartoma
1992 [10]	3	Hamartoma
1993 [11]	1	Hamartoma
1995 [4]	22	Adenomatoid hamartoma
1999 [12]	1	Hamartoma
1999 [13]	1	Chondroid hamartoma
2000 [1]	1	Adenomatoid hamartoma
2002 [5]	1	Adenomatoid hamartoma

(REAH). To meet the definition of REAH, a hamartoma must display the following characteristics:

- The glandular component of the mass consists of respiratory epithelium originating from the surface epithelium
- Polypoid growth is the result of respiratory epithelium-lined adenomatoid proliferation

There are no specific immunohistochemical studies for REAH. MIB-1 staining can sometimes be helpful in differentiating neoplasms from REAH. Neoplasms show a higher degree of immunoreactivity for MIB-1 [1]. The key feature differentiating this entity from inflammatory sinonasal polyps is that of extensive glandular proliferation.

Long-term chronic inflammation and polyposis of the respiratory epithelium may be an etiologic precursor of REAH [4]. Thus, patients with REAH often have signs and symptoms of chronic rhinosinusitis including, but not limited to rhinorrhea, sinus headaches, nasal stuffiness, nasal airway obstruction, and epistaxis [5].

Hamartomas of the nasal cavity and paranasal sinuses are rare. To date, only 36 previous cases of hamartomas of the nasal cavities and paranasal sinuses have been reported. A pathological subtype summary of these cases is listed in Table 1. More than 90% of patients reported have isolated involvement of the nasal cavity, with a median age of 58 years, and a strong male to female preponderance of approximately 7:1. Extensive progression of the disease to involve the orbit and intracranial vault as described herein is exceedingly rare. To our knowledge, this represents only the second reported case of isolated frontal sinus involvement by REAH. As such, in addition to the above symptoms, extension outside the confines of the sinus can be expected to give rise to orbital complaints such as proptosis or intracranial pressure symptoms such as progressive headaches. Involvement of the frontal sinus and extension beyond it necessitate the need for standard craniofacial approaches to provide not only for safe access to the lesion for complete removal, but also for reconstruction of any associated significant osseous deficits.

The differential diagnosis of REAH in the nasal cavity and paranasal sinuses includes inverting papilloma and adenocarcinoma. Differentiation between these entities is important because REAH is a nonmalignant lesion, and complete resection of the mass is curative without a need to remove a cuff of normal surrounding tissue. Inverting papillomas represent overgrowth of the squamous portion of the epithelium admixed with mucocytes, intraepithelial mucous cysts, and an inflammatory cell infiltrate invading through the epithelial layer. Adenocarcinomas, in contrast, consist of glandular overgrowth, with glands arranged in a back-to-back fashion without interrupting the background stromal tissue [2].

### 3. Conclusion

In comparison to malignancies that represent neoplasms with unimpeded growth potential, hamartomas represent overgrowth of tissue endogenous to a particular area of the body. Hamartomas do not have unlimited growth potential, nor do they have metastatic potential. Conservative surgical resection of hamartomas is curative, and the literature describes no instances of recurrent, persistent, progressive, or metastatic disease. Differentiation between hamartomas and malignancies or other neoplasms is important because operative management and postoperative therapeutic regimens between the 2 cases differ vastly.

### References

- [1] Endo R, Matsuda H, et al. Respiratory epithelial adenomatoid hamartoma in the nasal cavity. *Acta Otolaryngol* 2002;122:398-400.
- [2] Willis RA. Hamartoma and hamartomatous syndromes. *Borderland of embryology and pathology*. 2nd ed. London: Butterworths; 1962. p. 351-92.
- [3] Kapadia SB, Popek EJ, Barnes L. Pediatric otorhinolaryngic pathology: diagnosis of selected lesions. *Pathol Annu* 1994;29:159-209.
- [4] Wenig BM, Heffner DK. Respiratory epithelial adenomatoid hamartomas of the sinonasal tract and nasopharynx: a clinicopathological study of 31 cases. *Ann Otol Rhinol Laryngol* 1995;104:639-45.
- [5] Himi Y, Yoshizaki T, et al. Pathology in focus; respiratory epithelial adenomatoid hamartoma of the maxillary sinus. *J Laryngol Otol* 2002; 116:317-8.
- [6] Kacker SK, Dasgupta G. Hamartomas of ear and nose. *J Laryngol Otol* 1973;81:801-5.
- [7] Mahindra S, Daljit R, et al. Hamartomas of the nose. *J Laryngol Otol* 1978;92:57-60.
- [8] Mahindra S, Bazaz MG, Bais AS, et al. Vascular hamartoma of the paranasal sinuses. *Acta Otolaryngol (Stockh)* 1981;92:379-82.
- [9] Chisin R, Ragozzino MW, et al. MR assessment of a hamartoma of the nasal cavity. *AJR Am J Roentgenol* 1987;149:1083-4.
- [10] Grame-Cook F, Pilch BZ. Hamartomas of the nose and nasopharynx. *Head Neck* 1992;14:321-7.
- [11] Terris MH, Billman GF, Pransky SM. Nasal hamartoma: case report and review of the literature. *Int J Pediatr Otorhinolaryngol* 1993;28: 83-8.
- [12] Kaneko C, Inokuchi A, Kimitsuki T, et al. Huge hamartoma with inverted papilloma in the nasal cavity. *Eur Arch Otorhinolaryngol* 1999;256:33-7.
- [13] Kim DW, Low W, et al. Chondroid hamartoma presenting as a neonatal nasal mass. *Int J Pediatr Otorhinolaryngol* 1999;47:253-9.