

## How I Do It

# Interim Fixation of Mandible Fractures

Jesse E. Smith, MD, and Yadranko Ducic, MD, FRCSC, FACS

The mandible provides structural support for the teeth and a route for neural and vascular supply to the dentition, as well as sensory perception for the lower one-third of the face. Although the mandible is the largest and strongest facial bone, fractures frequently result as a sequela of facial trauma because of the mandible's physical prominence in the lower face. Vehicular accidents and assaults are the leading causes of mandibular fractures.<sup>1-3</sup>

Open reduction and internal fixation are often the treatment of choice for significantly displaced mandible fractures.<sup>4</sup> Yet reduction of these displaced bony fragments, and their subsequent stabilization during plating, can be difficult and occasionally cumbersome, involving several instruments and multiple hands in a small operative field. Thus, reduction and plating techniques for open repair of mandible fractures often require two surgeons or at least one surgeon and a skilled technician. To lessen the technical assistance needed and to assist with reduction prior to plating, several methods have been proposed in the literature. These involve the use of towel clamps, screws, and wires.<sup>5</sup> However, in theory, these are not completely optimal. With towel clamp and modified towel clamp techniques, the surgeon is still required to manipulate large clamps while drilling and plating.<sup>5</sup> One must also remember that a large clamp remains in the operative field, possibly compromising direct visualization, especially when operating through a small incision. The screw-wire osteosynthesis technique described by Dym and coworkers was used on more than 40 unfavourable mandible angle fractures as the sole source of repair.<sup>6</sup> This technique uses 8-mm screws and 24-gauge wire at the angle of the mandible. Dym and colleagues reported no complications for their small cohort.<sup>6</sup>

This brief article outlines an approach to the interim fixation of the fractured mandible prior to definitive plating. This technique provides the surgeon with the opportunity to use both hands during placement of plates and the additional comfort of having fewer instruments in the area of interest during plating. In addition, this technique provides for increased stability of fracture fixation, serving as a useful tension band because the interim stabilization device is not removed after plating. This procedure also decreases the probability of incorrectly placed plate holes because it permits reduction prior to plating in a manner that allows simultaneous evaluation of both the occlusion and the fracture line.

### Technique

We generally favour the use of transoral fracture exposure and fixation in most patients unless a significant facial laceration provides direct transfacial access to the fracture site. After local infiltration of the proposed access site with lidocaine hydrochloride and epinephrine 1:100,000, an incision is made along the gingivobuccal or gingivolabial sulcus, leaving a cuff of gingival mucosa and mentalis muscle to facilitate closure after completion of the procedure. The incision should be of adequate length to obtain sufficient exposure to the fracture site and to allow for plate application. Electrocautery is then used to incise the mucosa in layers, posteroinferior to the incision. Subperiosteal dissection is then carried inferiorly with periosteal elevators to the level of the inferior border of the mandible. The mental nerve should be identified if the incision's location is adjacent to or opposes the ipsilateral premolars (Figs. 1 and 2).

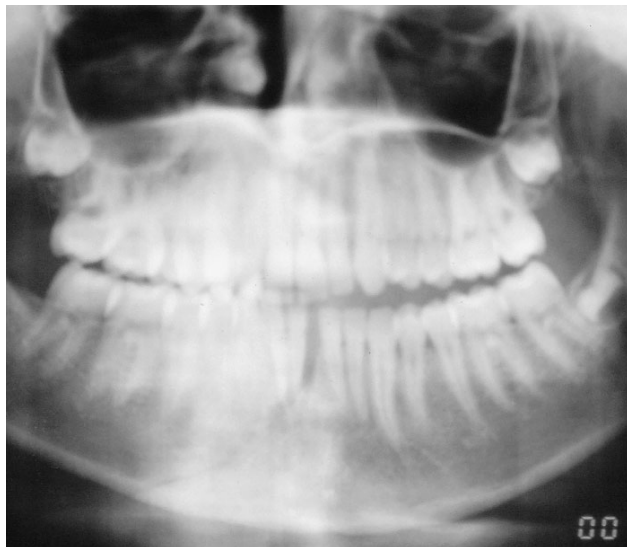
In vertically favourable fractures, two monocortical holes are then drilled perpendicular to the bony surface, directly across from one another and approximately 5 to 8 mm on either side of the fracture line. In vertically unfavourable fractures, diagonal placement of screws across the fracture line assists in fracture reduction. Proper placement of the drill holes is dependent on the site of the fracture. For fractures of the symphysis and body, interim fixation is done superior to the inferior alveolar nerve canal. For fractures of the angle and ramus, the interim fixation may be applied more inferiorly since the plate will most likely be medial to the

---

Received 27/02/01. Received revised 13/12/01. Accepted for publication 13/12/01.

Jesse E. Smith: Department of Otolaryngology-Head and Neck Surgery, University of Texas Southwestern Medical Center, Dallas, Texas; and Yadranko Ducic: Department of Otolaryngology-Head and Neck Surgery, University of Texas Southwestern Medical Center, Dallas, Texas, and the Division of Otolaryngology and Facial Plastic Surgery, John Peter Smith Hospital, Fort Worth, Texas.

Address reprint requests to: Dr. Yadranko Ducic, Director, Otolaryngology and Facial Plastic Surgery, John Peter Smith Hospital, 1500 South Main Street, Fort Worth, TX 76104.



**Figure 1** Panorex demonstrating fracture of the right mandibular body.

oblique line on the proximal segment. A 4-mm drill bit should be used in an effort to avoid both tooth roots and the inferior alveolar neurovascular bundle.

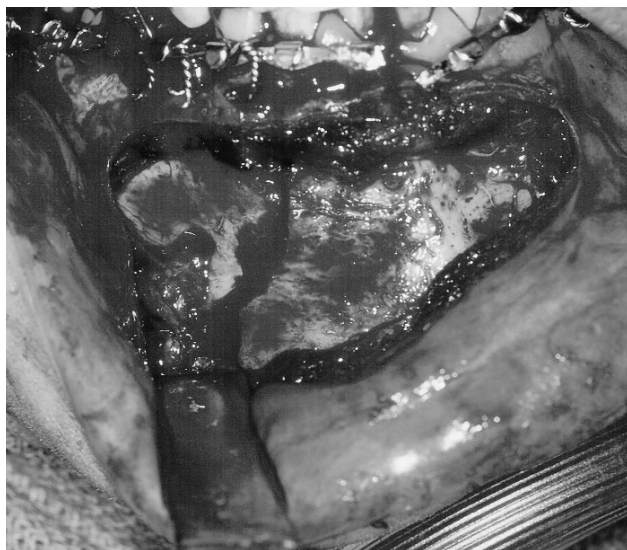
The fracture is then appropriately reduced at both the lingual and buccal cortices. Two 6.0-mm length screws (2.0 mm diameter) are then placed in the drill holes in a monocortical fashion. These 2.0 system screws are incompletely seated within the screw holes, allowing for wire application. This raised portion allows the placement of a 24-gauge wire loop around the two screws. As the wire loop is tightened, the approximated gap and instability between the fracture fragments progressively decrease until full reduction is

achieved. At this point, the monocortical screws and wire alone hold the reduction in place. Once the surgeon is satisfied with the reduction, the screws are tightened onto the wire, and the wire is trimmed and tucked. Following reduction, the surgeon can effortlessly evaluate the patient's occlusion and reduction status. After satisfactory evaluation, the surgeon can readily plate the mandible fracture with a clear field of visualization, even through a small incision. Plate position is still determined by the optimal lines of osteosynthesis as described by Champy et al. (Figs. 3 and 4).<sup>7</sup>

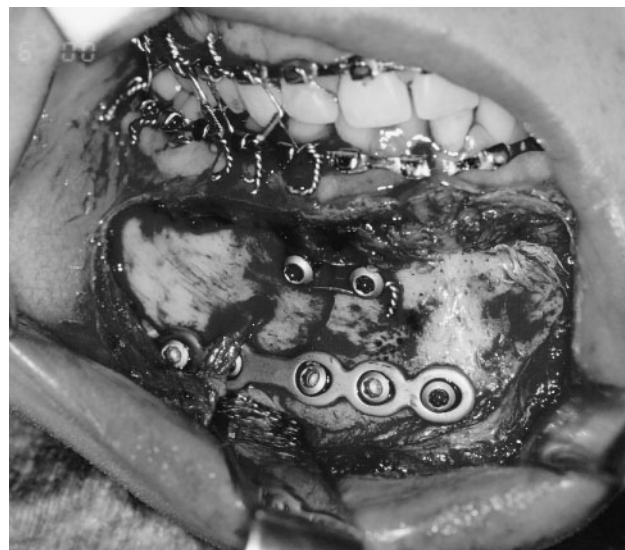
## Discussion

The parabolic body of the mandible consists of outer and inner cortical layers and a central spongiosa. The outer cortex is thicker and stronger, especially in the region of the mentum, thus providing adequate anchorage for screws. It is important to recognize that the interim fixation screws described above are placed in a monocortical fashion, firmly seated in the outer cortex, so as not to interfere with the tooth roots and the inferior alveolar neurovascular bundle. Although the outer mandibular cortex is 5 mm thick on average, in some cases, it may be as thin as 3 mm or less, especially near the tooth root apices.<sup>8</sup> Therefore, the surgeon should choose a drill bit that ensures monocortical depth of penetration, such as the 4-mm bit described above. Sound surgical judgement and thoughtful placement of the interim fixation screws are required to avoid root tip injuries.

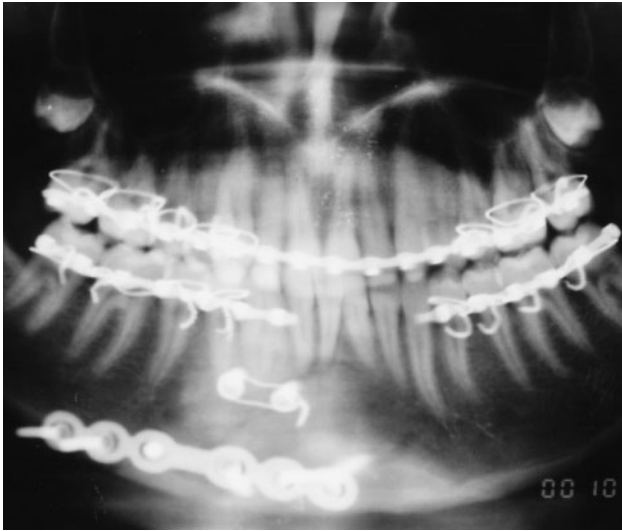We have encountered no complications, wound infection, plate exposure, or malocclusion in greater than 30 consecutive fractures of the mandible in which the interim fixation technique was used by the senior



**Figure 2** Intraoperative view of the patient in Figure 1 demonstrating a grossly displaced fracture immediately anterior to the mental foramen.



**Figure 3** Interim fixation applied across the superior aspect of the fracture line, facilitating plate application across the inferior portion of the fracture.



**Figure 4** Postoperative panorex demonstrating adequate reduction. Note that the interim fixation across the superior aspect of the fracture line serves as a tension band when left in situ as in this patient, in whom the arch bar required sectioning to allow for intraoperative fracture reduction.

author (YD). When using the interim fixation technique, there are some instances for which special care and attention are necessary. While tightening the 24-gauge wire around the screws, one should note that too much compression on the outer cortex with the interim fixation wire may splay the lingual cortex or cause disruption of the occlusal relationship. The surgeon should also note fractures that are of a severely oblique nature. In such cases, the screw nearest the acute angle should be placed further from the fracture line to prevent the screw tip from entering the fracture line and thus interfering with proper reduction. Finally, when there are two or more fractures of the mandible, osteosynthesis is first performed in the tooth-bearing section of the jaw. In these comminuted or multifocal fractures, multiple screw interim fixations may be required. These may serve as the sole method of fixation for small, comminuted fracture segments for which plate fixation is neither practical nor possible.

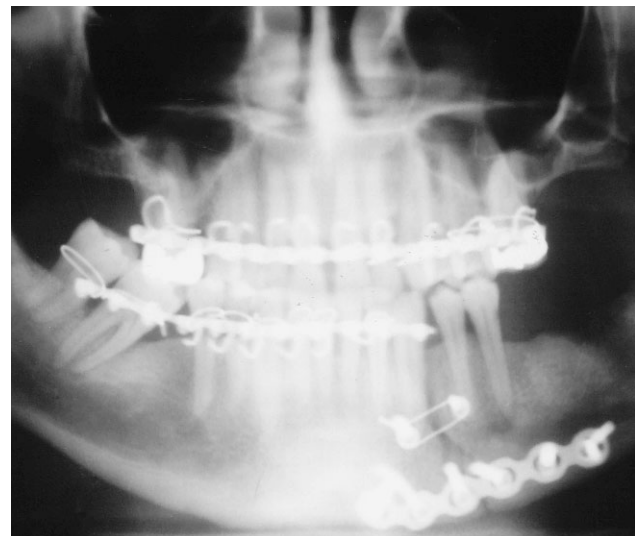
Some authors fear that the engagement of only the outer cortex near a fracture may cause comminution of the bone.<sup>5</sup> Valentino and associates used monocortical miniplating techniques across fracture lines to repair 313 mandibular fractures.<sup>3</sup> Only 3 of these 313 patients had loosening of hardware within the first 5 postoperative weeks, but there was no mention of fixation causing comminution in this series.<sup>3</sup> Hardware-induced comminution would likely be a concern in only extremely oblique fracture lines; however, the interim fixation technique described herein reduces this risk by placing the monocortical screws 3 to 4 mm deep to the bone surface and 5 to 8 mm from the fracture edge, allowing an oblique fracture angle to be as sharp as 20

to 30 degrees without the risk of added comminution across the fracture.

The arch bar often acts as a suitable tension band for fractures within the occlusal area. Yet when the arch bar has been sectioned to allow for fracture reduction, or an arch bar cannot be placed in an area of either poor dentition or tooth loss, the screw fixation technique serves as a useful tension band when left in place (Figs. 4 and 5). In such cases, it allows for the maintenance of reduction during plate application and increases the stability of the final fixation.

## Conclusion

The method of interim fixation described above outlines an approach that is easily applied to most mandible fractures repaired by open reduction. Not only does this technique assist in the reduction of the fracture, it also maintains this reduction, thus easily allowing the surgeon an opportunity to simultaneously evaluate the occlusion and the fracture line. The technique requires no special tools or devices other than those already found within standard mandibular fracture surgical instrument and plating sets. Interim fixation offers the surgeon multiple benefits, including better visualization secondary to the presence of less instrumentation in a small operative field, the need for less technical assistance, added stabilization across the fracture line, and the luxury of using both hands in plate placement, thus reducing the chance of misplaced drill holes.



**Figure 5** Panorex of another patient in whom adequate reduction has been achieved across a comminuted fracture of the left mandibular body. Note that the interim fixation again increases the stability of the reduction, preventing splaying across the occlusal surface by serving as a tension band in this patient with lack of adequate posterior dentition preventing arch bar application distal to the fracture.

## References

1. Sinn DP. Mandibular fractures. Selected readings in oral and maxillofacial surgery. Vol 1. 1989:4–5.
2. Haug RH, Prather J, Indresano AT. An epidemiologic survey of facial fractures and concomitant injuries. *J Oral Maxillofac Surg* 1990; 48:926–932.
3. Valentino J, Levy FE, Marentette LJ. Intraoral monocortical miniplating of mandibular fractures. *Arch Otolaryngol Head Neck Surg* 1994; 120:605–612.
4. Chu L, Gussack GS, Muller T. A treatment protocol for mandible fractures. *J Trauma* 1994; 36:48–52.
5. Rogers GF, Sargent LA. Modified towel-clamp technique to effect reduction of displaced mandible fractures. *Plast Reconstr Surg* 2000; 105:695–697.
6. Dym H, Coro CM, Ogle OE. Screw-wire osteosynthesis technique for intraoral open reduction of mandibular angle fractures. *J Oral Maxillofac Surg* 1992; 50:1247–1248.
7. Champy M, Lodde J, Schmitt R, et al. Mandibular osteosynthesis by miniaturized screwed plate via a buccal approach. *J Maxillofac Surg* 1978; 6:14–21.
8. Eberhard K, Schilli W. Mandible fractures. In: Champy M, Hans-Dieter P, Gerlach KL, Lodde JP, eds. *Oral and maxillofacial traumatology*. Vol. 2. Chicago: Quintessence, 1986:19–43.