

# Lipotransfer as an Adjunct in Head and Neck Reconstruction

Yadranko Ducic, MD, FRCS(C), FACS; Allison T. Pontius, MD; Jesse E. Smith, MD

**Objectives:** To present our technique of lipotransfer and to evaluate a single center's experience in the use of lipotransfer as an adjunct to head and neck reconstruction. **Study Design:** A retrospective review of all patients undergoing lipotransfer over a 5-year period by the senior author was undertaken. A total of 23 patients with a minimum follow-up of 1 year were available for analysis. **Methods:** Patient records were retrospectively reviewed to assess functional (in the case of palate augmentation) and esthetic outcomes. **Results:** Twenty-three patients undergoing lipotransfer as part of their reconstructive effort included (1) eight patients undergoing temporal fossa augmentation following temporalis muscle flap reconstruction for extirpative skull base surgery, (2) six patients undergoing facial defect augmentation following traumatic atrophy, (3) three patients undergoing palatal augmentation for correction of velopharyngeal insufficiency, and (4) six patients undergoing soft tissue augmentation following flap reconstruction of the face. Twenty of the 23 patients had excellent maintenance of graft volume. An adequately vascularized recipient bed appears to be an important factor in determining ultimate graft survival using our technique. **Conclusions:** Lipotransfer of the head and neck represents a simple, effective adjunctive technique providing for large amounts of readily available, well-tolerated soft tissue filler material. Patient selection is important, specifically in regard to determining that there is adequate vascularity of the recipient bed. **Keywords:** Lipotransfer, reconstruction, fat grafting, facial plastic surgery.

*Laryngoscope*, 113:1600–1604, 2003

Soft tissue augmentation has been successfully accomplished with a number of materials of varying biocompatibility. These include injectable silicone (no longer approved by the US Food and Drug Administration) and other alloplasts, collagen, acellular dermis, fascia, and

adipose tissue. The ideal material is biocompatible and inexpensive, persists over the long term, is available in large quantities, and carries no risk of rejection and a low chance of infection. Autologous fat has historically been accepted as fulfilling all of these criteria with some uncertainty as to long-term risk of resorption. However, there is increasing evidence to support its persistence with proper preparation, injection, and patient selection.

Lipotransfer is certainly not a new procedure. The first attempt at fat transfer took place more than 100 years ago when Neuber<sup>1</sup> used small pearls of fat taken from the arm to fill a depressed facial defect. In 1911, Bruning<sup>2</sup> was the first to inject autologous fat into the subcutaneous tissues for the purpose of soft tissue augmentation. For the next 40 years, fat transplants were largely neglected as surgeons became more interested in pedicled flaps and the use of artificial injectable substances, such as paraffin and silicone. In 1950, however, there was renewed interest in lipotransfer as Peer<sup>3</sup> demonstrated an average retention of the transplanted fat of 40 to 50%. Interest continued to escalate in the 1980s, largely in Europe and among the dermatology community, because liposuction now provided easy and abundant access to large amounts of adipose tissue.<sup>4</sup> Chajchir<sup>5</sup> discussed the use of fat grafts for facial rhytids and Vita<sup>6</sup> explored the use of fat transfer for rejuvenation of aging hands. In the 1990s, Coleman<sup>7,8</sup> concentrated fat by centrifugation and used this fat in multiple planes across the face for a "facelift bypass." Over the past decade, the majority of published articles discuss refinement of these techniques and demonstrate positive long-term results of fat transfer used in cosmetic augmentation.<sup>9–18</sup>

As the role of lipotransfer in esthetic soft tissue augmentation of the face, neck, and body has continued to expand, there remains little information in the literature regarding its use as an adjunct in reconstructive surgery of the head and neck. In this article, we review our positive experience in the routine use of lipotransfer to improve the functional and esthetic outcomes in this patient population.

## METHODS AND MATERIALS

A retrospective review of all patients undergoing lipotransfer for head and neck reconstruction over a 5-year period by the senior author (Y.D.) was undertaken. A total of 23 patients with a

From the Department of Otolaryngology–Head and Neck Surgery, University of Texas Southwestern Medical Center, Dallas, Texas, and the Division of Otolaryngology and Facial Plastic Surgery, John Peter Smith Hospital, Fort Worth, Texas, USA.

Editor's Note: This Manuscript was accepted for publication May 7, 2003.

Correspondence to Yadranko Ducic, MD, FRCS(C), FACS, Director, Otolaryngology and Facial Plastic Surgery, John Peter Smith Hospital, 1500 South Main Street, Fort Worth, TX 76104, U.S.A. E-mail: yducicj@aol.com

minimum follow-up of 1 year were analyzed for the purpose of this study. Serial photographic documentation during the follow-up period was used to evaluate the response to treatment at all sites. In addition, speech therapy evaluation of patients with palatal augmentation for velopharyngeal insufficiency was utilized to evaluate the effectiveness of palatal augmentation in terms of functional outcome. Lipotransfer was used in four broad categories of patients: (1) soft tissue augmentation of the temporal fossa following temporalis muscle flap harvest; (2) correction of soft tissue atrophy in the patient sustaining facial trauma; (3) augmentation of the soft palate for correction of velopharyngeal insufficiency; and (4) esthetic enhancement of facial contour following flap reconstruction of oncologic defects.

### **Lipotransfer Technique**

The patient is placed in a supine position with the head, neck, and abdomen prepped and draped. Two small stab incisions are made along the inner lateral borders of the umbilicus. Next, tumescent solution is introduced through an infiltrating cannula. The senior author (Y.D.) uses the following tumescent solution, which facilitates fat harvest, decreases postoperative bruising, and decreases intraoperative blood loss:

- 500 mL lactated Ringer solution
- 20 mL 2% plain lidocaine
- 1 mL epinephrine 1:1000
- 1 mL 3% sodium bicarbonate

Approximately 40 mL of tumescent solution is used during an average case. Full benefit is derived from the tumescent solution by waiting approximately 10 minutes prior to harvest. A 35 mL, 3.7 mm cannula is then attached to a 30 mL syringe. With the open portion of the cannula facing away from the skin surface, quick precise sweeping movements are made along the previously established planes. The nondominant hand continues to grasp the skin and abdominal fat and pull it ventrally. The dominant hand retracts the plunger of the 30 mL syringe, bringing fat globules into the syringe through the negative pressure provided by constant traction on the plunger. Once both sides of the abdominal wall have been harvested in approximately equal amounts, the collected fat is allowed to sit for approximately 15 minutes to allow for settling out of the layers (Fig. 1). Use of a centrifuge will expedite this process. The top layer is discarded because it contains a high concentration of free fatty acids and other promoters



Fig. 1. Harvested fat has been allowed to settle into well-defined layers. Large arrow, free fatty acid layer; small arrow, serous fluid layer. The tissue layer for transplantation lies between the serous and the free fatty acid layers.

of the inflammatory response. The next layer contains the non-traumatized fat that is suitable for injection. The bottom layer is serous fluid that is discarded because it provides a false sense of augmentation that is not sustained. The central viable fat layer is then transferred with an anaerobic connector (Fig. 2) into a series of 10 mL syringes, which are loaded onto an injection gun (Fig. 3). This will allow for metered pearls of fat to be deposited into the desired location and for restoration of soft tissue form. We believe that overcorrection is not required with the outlined technique. Thus, soft tissue augmentation ceases once an esthetically favorable form has been attained.

Depending on the size of the needle used for injection and the amount of fat injected, an absorbable 5.0 or 6.0 plain gut suture can be used to seal the injection site so as to prevent any extrusion of fat and to reapproximate the skin edges to enhance cosmesis. The umbilical stab incisions are closed with a similar suture. An abdominal binder is worn by the patient for 1 week continuously and then nightly for a further 3 weeks. Preoperatively, we habitually use first-generation cephalosporin and metronidazole and a single dose of intravenous dexamethasone. Postoperatively, oral first-generation cephalosporins are provided for 1 week.

## **RESULTS**

### **Temporal Fossa Augmentation**

Eight patients underwent lipotransfer to the temporal fossa after temporalis muscle flap reconstruction following extirpative skull base surgery. We typically perform initial temporal fossa cranioplasty by restoration of the volume deficit left by temporalis muscle harvest, with hydroxyapatite cement. This is performed in all patients and suffices to provide for the initial correction of the deformity. Over the long term, as the edema completely subsides, there is a loss of the normal “soft” appearance to

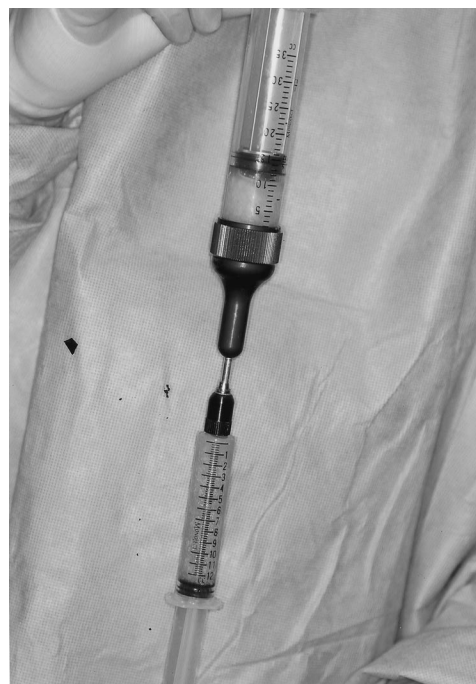


Fig. 2. Anaerobic transfer is accomplished to allow for transfer of the harvested fat into 10 mL syringes. Significant exposure to air may allow for unwanted oxidation of the fat.

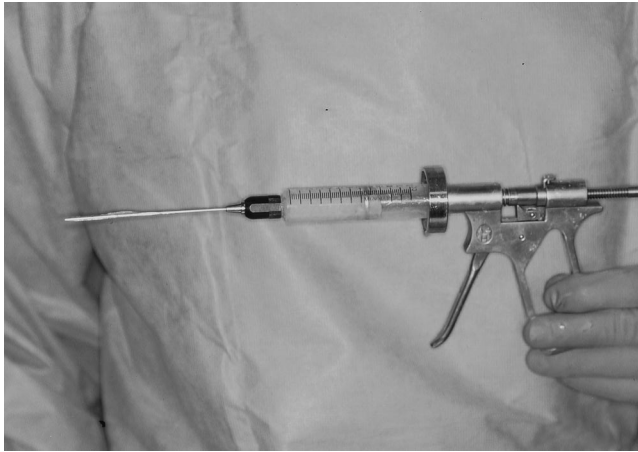

Fig. 3. A 10 mL syringe loaded onto an injector gun to allow for delivery of metered globules of fat into the recipient site.

the temporal fossa when augmented with cement. Thus, we habitually offer disease-free patients lipotransfer to the temporal fossa to soften the appearance of the well-augmented defect at 6 months following initial surgery (some patients are quite content with their initial appearance and desire no further surgery). A total of 13 lipotransfers were performed in this group of patients (four patients underwent one procedure each; three patients, two procedures each; and one patient, three procedures). The 1-year contour improvement was felt to be good in six patients and inadequate in two. The patients with what was judged to be a good result (reasonable contour correction, soft appearance, maintenance of graft volume) had initially undergone augmentation of the intact calvarium of the temporal fossa with hydroxyapatite cement only, whereas the other two patients had undergone alloplastic (titanium mesh and hydroxyapatite) cement reconstruction of a complete calvarial defect initially (Figs. 8 and 9).

#### ***Facial Defect Augmentation after Traumatic Atrophy***

A number of patients sustaining trauma to the soft tissues of the face will develop subsequent atrophy of the underlying subcutaneous tissue, resulting in significant contour irregularities. Six patients underwent lipotransfer to help correct some of these post-traumatic irregularities. All six underwent only a single procedure and were able to achieve sustainable improvement without the need for any further augmentation (Figs. 4 and 5).

#### ***Augmentation of the Palate for Treatment of Velopharyngeal Insufficiency***

Three patients with velopharyngeal insufficiency following oncologic oropharyngeal resection ( $n = 2$ ) and bi-maxillary swing ( $n = 1$ ) underwent lipotransfer to the free edge of the soft palate. Two patients underwent a single procedure and one underwent two procedures. Significant improvement in both hypernasality and nasopharyngeal reflux of food was noted in each case.

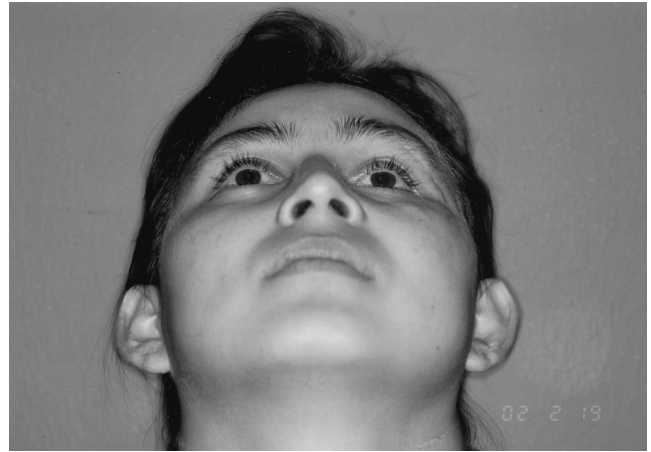


Fig. 4. Preoperative appearance of a patient who had sustained trauma to the left periorbital region, leaving her with significant subcutaneous tissue atrophy and soft tissue irregularities.

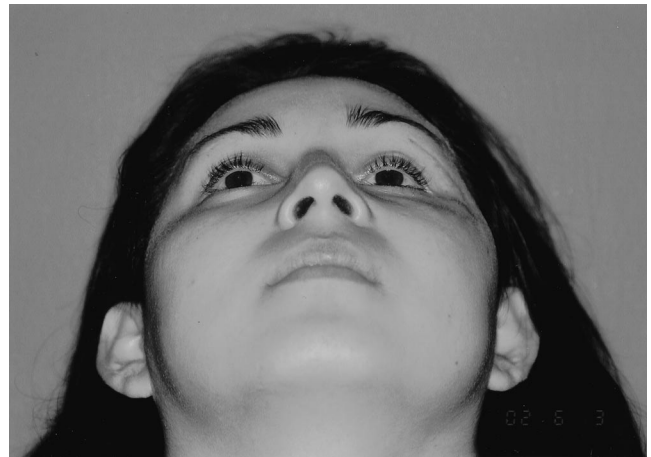


Fig. 5. Early 4-month postoperative appearance of the patient shown in Figure 4 following a single lipotransfer.

#### ***Soft Tissue Augmentation Following Flap Reconstruction of the Face***

Although regional flaps provide for excellent coverage of cutaneous defects of the face and neck, on occasion there is inadequate subcutaneous tissue volume to the flap as compared to normal. This is most commonly noted when cervical flaps (relatively little subcutaneous tissue) are used to reconstruct cheek tissues (relatively large amount of subcutaneous tissue) removed as a result of extirpative surgery or lost as a result of trauma. Six patients underwent a total of eight lipotransfer procedures (four patients underwent one procedure each and two patients underwent two procedures each). The final result was judged to be good in five patients and remained inadequate in one patient after two episodes of augmentation (Figs. 6 and 7).

Other than the expected ecchymosis noted at the donor site, no donor site morbidity has been noted in our patient population to date. No seromas were noted. The umbilical scar has been well accepted owing to its minor



Fig. 6. Preoperative appearance of a patient who had undergone a cervicofacial rotation flap for coverage of a right cheek defect following excision of a dermatofibrosarcoma protuberans. Although her reconstructive result is adequate, there is a relative deficiency of subcutaneous tissue in the flap portion of the cheek.

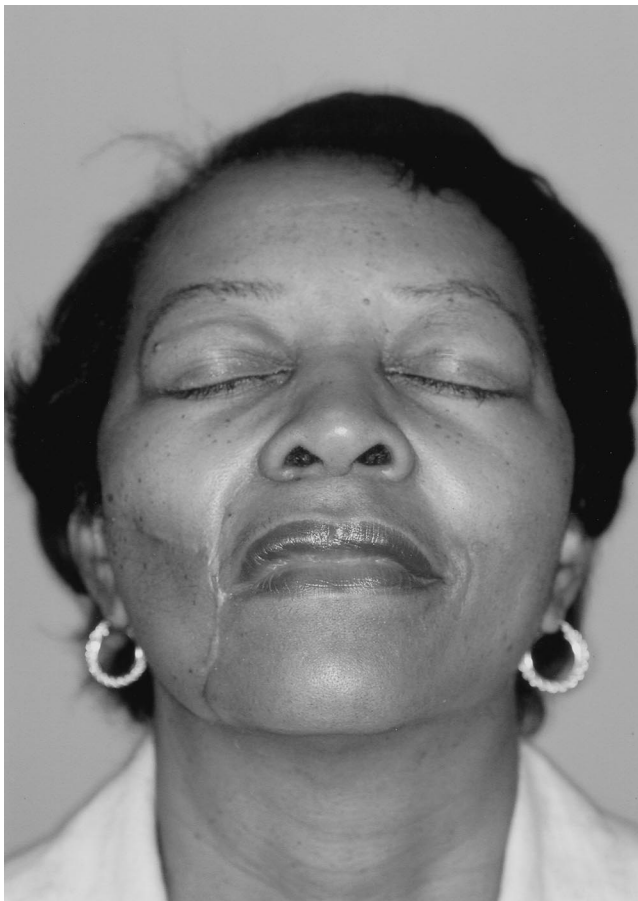


Fig. 7. The 1-year postoperative appearance of the patient shown in Figure 6 following a single lipotransfer.

size and relatively hidden nature. No recipient site morbidity was noted in our study population. There was no evidence of autograft infection, extrusion, or rejection.

## DISCUSSION

In theory, injectable autologous adipose tissue represents a nearly ideal soft tissue replacement material for head and neck reconstruction. Donor site morbidity is minimal and may be construed as being esthetically beneficial by the patient through removal of unwanted areas of lipodystrophy. The material is readily available in large quantities and is biocompatible, well tolerated, and accepted by the patient population. As early as 1940, Clark and Clark<sup>19</sup> reported that storage of fat was a dynamic process, with cyclic deposition and removal of lipid material from larger fat droplets within adipocytes. Subsequently, Saunders et al.<sup>20</sup> examined the ultimate survival of adipose tissue autografts used over dura following laminectomy in humans. In both this human model of graft survival and a mouse experimental model, the authors noted survival of the autograft with normal adipose tissue and no evidence of scar tissue. This lack of fibrous tissue reaction with long-term persistence of the graft material is a unique characteristic of autologous fat that is not seen with alloplasts or other autografts.

The ease of use, biocompatibility, availability, and patient acceptance of adipose autografts is well recognized. Long-term graft volume maintenance remains a potential problem, preventing the routine use of this material by many reconstructive surgeons. Yet the surgical literature is replete with affirmative studies demonstrating long-term survival of transplanted fat in a variety of recipient sites.<sup>21-24</sup>

In our series, we have noted excellent maintenance of graft volume in the majority of our patient population (20 of 23). We defined maintenance of graft volume by examining serial photographs demonstrating no significant change at the recipient site from initial augmentation. Among the three patients with lack of long-term volume maintenance, two underwent augmentation of the temporal fossa following titanium mesh-hydroxyapatite cement cranioplasty,<sup>25</sup> and one underwent lipotransfer following flap reconstruction of the cheek. The first two are postulated to have failed secondary to augmentation between an alloplastic construct and atrophied overlying temporal fossa skin and its inability to provide for adequate neovascularization of the grafted adipocytes. The patient who failed following flap reconstruction to the cheek had developed a significant fibrotic reaction within the flap after radiation therapy to the region. This also is believed to have formed an inadequate recipient bed for the transplanted adipocytes, contributing to their subsequent resorption. With these exceptions, we noted excellent graft survival with functional (in the case of palate augmentation) and esthetic restoration of form through the outlined technique of lipotransfer without the need for initial overcorrection.

All members of this study population had healed well following major reconstructive surgery of the head and neck. The procedure in question was presented as a method of enhancing their final result. Lipotransfer represents an outpatient procedure with little discomfort and no foreign body implantation. Patient acceptance for this procedure both preoperatively and postoperatively was high.

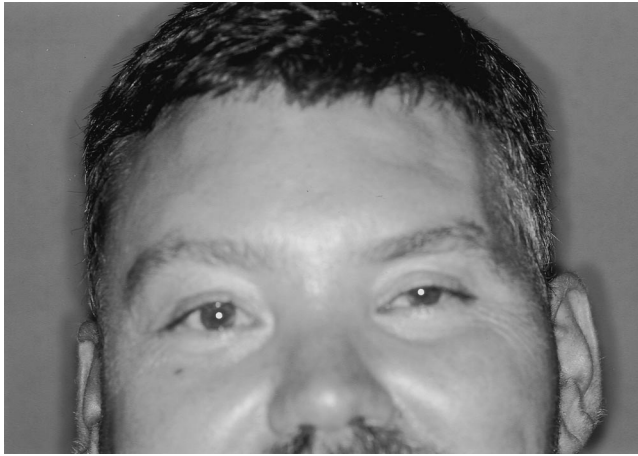

Fig. 8. Preoperative appearance of a patient who had undergone temporalis muscle flap reconstruction of a base of skull defect following an orbitozygomatic approach to a schwannoma of the second division of the trigeminal nerve. The initial contour was achieved with a hydroxyapatite cement cranioplasty. Note that there remains some long-term hollowing and contour deficit in the left temporal fossa.

Significant complications are possible at the donor site, however. Such complications would include seroma or hematoma formation, dysesthesias, contour irregularities, intra-abdominal perforation, and adverse scarring. The senior author (Y.D.) feels strongly that the goal of lipotransfer is soft tissue augmentation of the face and neck. This is well within the scope of many facial plastic surgeons' practices. Although the fat is harvested in a symmetric fashion from the abdominal wall to lessen the possibility of asymmetries, we do not attempt to remove significantly more fat than is required for the augmentation. Thus, the overall appearance at the donor site is minimally altered even in obese individuals who would otherwise esthetically benefit from cosmetic liposuction. As with all procedures, proper training and experience will decrease the possibility of complications.

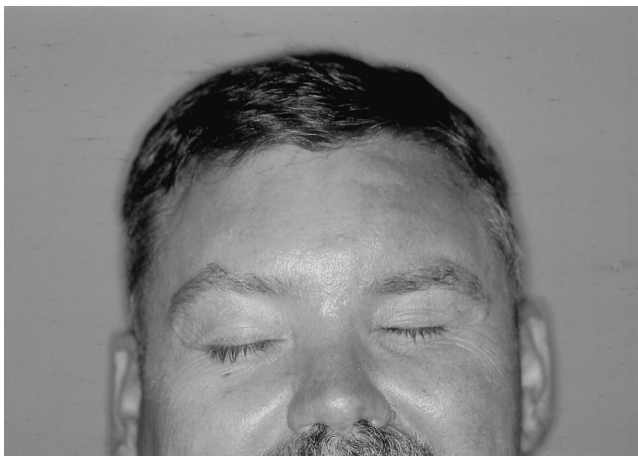


Fig. 9. The 18-month postoperative appearance of the patient shown in Figure 7 following lipotransfer resulting in maintenance of contour over the long term.

## CONCLUSION

Lipotransfer in head and neck reconstruction appears to represent a simple, efficacious, well-tolerated technique associated with excellent functional and esthetic outcomes at a number of sites. Long-term graft volume maintenance is seen in the majority of patients. One should expect a decrease in graft volume over time in patients with a poorly vascularized recipient bed.

## BIBLIOGRAPHY

1. Neuber F. Fet Transplantation. *Chir Knogr Verhandl Dtsche Gesellsch Chir* 1893;22:66–68.
2. Bruning. Contribution a l'etude des greffes adipeuses. *Bull Acad R Med Belgique* 1914;28:440–443.
3. Peer LA. Loss of weight and volume in human fat grafts. *Plast Reconstr Surg* 1950;5:217–220.
4. Newman J. Preliminary report on fat recycling. *Am J Cosmet Surg* 1986;3:67–69.
5. Charjchir A. Liposuction: fat grafts and face wrinkles. *Adv Plast Surg* 1986;10:115–121.
6. Vita VT. Lipoinjection and aging hands. *Am J Cosmet Surg* 1989;6:27–32.
7. Coleman SR. Techniques of periorbital infiltration. *Oper Tech Plastic Reconstr Surg* 1994;1:120–126.
8. Coleman S. Long term survival of fat transplants: controlled demonstration. *Adv Plast Surg* 1995;19:421–425.
9. Ellenbogen R. Fat transfer: current use in practice. *Clinic Plast Surg* 2000;27:545–556.
10. Fulton JE, Parastouk N. Fat grafting. *Derm Clin* 2001;19:523–530.
11. Shiffman MA, Mirrafati S. Fat transfer techniques: the effect of harvest and transfer methods on adipocyte viability and review of the literature. *Dermatol Surg* 2001;27:819–826.
12. Eremia S, Newman N. Long-term follow-up after autologous fat grafting: analysis of results from 116 patients followed at least 12 months after receiving the last of a minimum of two treatments. *Dermatol Surg* 2000;26:1150–1158.
13. Niechajev I, Sevchuk O. Long-term results of fat transplantation: clinical and histologic studies. *Plast Reconstr Surg* 1994;94:496–500.
14. Chajchir A, Bezaquen I, Moretti E. Comparative study of autologous adipose tissue processed by different techniques. *Aesthet Plast Surg* 1993;17:113–115.
15. Carpaneda CA, Ribiero MT. Percentage of graft viability versus injection volume in adipose auto transplants. *Aesthet Plast Surg* 1993;17:43–47.
16. Pinski JB, Roenick HH Jr. Autologous fat transplantation: long-term follow-up. *J Dermatol Surg Oncol* 1992;14:194–199.
17. Fulton JE, Suarez M, Silverton K, et al. Small volume fat transfer. *Dermatol Surg* 1998;24:1–9.
18. Jones JK, Lyles ME. The viability of human adipocytes after closed syringe liposuction harvest. *Am J Cosmet Surg* 1997;14:275–279.
19. Clark ER, Clark EL. Microscopic studies of new formation of fat in living adult rabbits. *Am J Anat* 1940;67:255–257.
20. Saunders MC, Keller JT, Dunsker SB, et al. Survival of autologous fat grafts in humans and in mice. *Connective Tissue Research* 1981;8:85–88.
21. Meyer DR, Wobig JL. Diamond shaped incision for obtaining dermis fat grafts. *Am J Ophthalmol* 1990;109:746–748.
22. Bryant MS, Bremer AM, Nguyen TQ. Autogenic fat transplants in the epidural space in routing lumbar spine surgery. *Neurosurgery* 1983;13:367–370.
23. Van Akkerveeken PF, Van de Kraan, Muller JWT. The fate of free fat graft: a prospective study using CT scanning. *Spine* 1986;11:501–504.
24. Mikaelian DO, Lowry LD, Sataloff RT. Lipoinjection for unilateral vocal cord paralysis. *Laryngoscope* 1991;101:465–468.
25. Ducic Y. Titanium mesh and hydroxyapatite cement cranioplasty: a report of 20 cases. *J Oral Maxillofac Surg* 2002;60:272–276.