

Metastatic Acinic Cell Carcinoma Presenting as a Recurrent Pituitary Adenoma

Tim Thomason, MD, Lance E. Oxford, MD, and Yadranko Ducic, MD, FRCSC, FACS

Acinic cell carcinoma is the third most common epithelial malignancy of the salivary glands. In the Armed Forces Institute of Pathology registry, acinic cell carcinoma accounts for 6% of all salivary gland tumours.¹ It most often develops in the parotid gland (86%) and is slightly more common in females (58.8%). Acinic cell carcinoma has a more favourable prognosis than most salivary gland malignancies. However, local and regional recurrence may develop in 34%.² Distant metastatic disease is rare and most often arises in the lungs and bones. Acinic cell carcinoma metastases to the brain have been reported previously. However, no cases of acinic cell carcinoma metastasizing to the pituitary gland have been reported. We present a case of metastatic acinic cell carcinoma presenting as a recurrent pituitary adenoma.

Case Report

A 49-year-old female presented for evaluation of a progressively enlarging left parotid mass. The mass had been present for several months but was not associated with significant pain or overlying skin changes. She denied dysphagia, dysphonia, odynophagia, nasal airway obstruction, epistaxis, or weight loss. Her past medical history was significant for multiple sclerosis, which had caused some visual problems and gait disturbance. On physical examination, a left parotid mass was present with significant deep lobe extension. Fibre-optic nasopharyngolaryngoscopy revealed left parapharyngeal fullness but was otherwise within normal limits. The facial nerve was normal bilaterally, and the neck was without clinically evident adenopathy. A computed tomographic scan

demonstrated a deep lobe solid parotid tumour. No other adenopathy was identified. However, a mass was identified in the sella turcica that extended into the sphenoid sinus.

Fine-needle aspiration biopsy was performed of the parotid mass, and the results were consistent with acinic cell carcinoma. Therefore, the patient was then taken to the operating room and a total parotidectomy was performed. At the time of surgery, the mass had extension superiorly toward the skull base but was removed en bloc without sacrifice of the facial nerve. Pathology revealed a classic acinic cell carcinoma with large irregular sheets of cells forming gland-like structures. There was moderate nuclear pleiomorphism with numerous mitotic figures (Figure 1). The tumour cells had large irregular nuclei, and the tumour itself was interspersed with areas of hyalinization. One month later, the patient underwent transsphenoidal removal of the pituitary adenoma. The patient then had 6 weeks of external beam radiation therapy in the region of the left parotid gland.

The patient remained free of disease for 21 months postoperatively. At that time, she developed left abducens palsy, and subsequent imaging revealed recurrence of the pituitary tumour. She was taken back to the operating

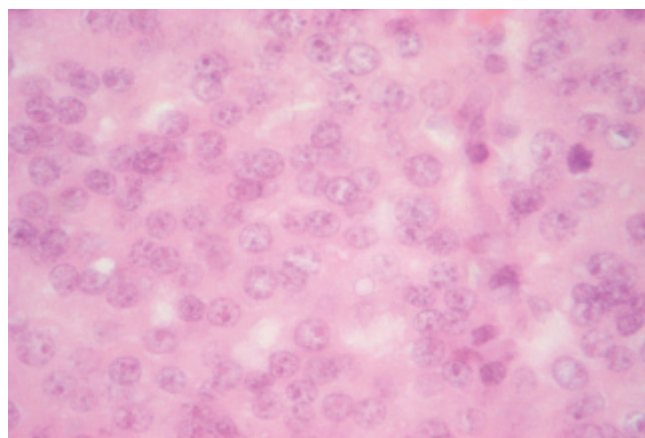


Figure 1. Photomicrograph (hematoxylin-eosin stain; $\times 40$ original magnification) demonstrating large irregular sheets of cells with nuclear pleiomorphism and areas of hyalinization.

Tim Thomason, Lance E. Oxford, and Yadranko Ducic: *Otolaryngology and Facial Plastic Surgery Associates, Fort Worth, Texas and the Department of Otolaryngology-Head and Neck Surgery, University of Texas Southwestern Medical Center, Dallas, Texas.*

Address reprint requests to: Yadranko Ducic, MD, FRCSC, FACS, *Otolaryngology and Facial Plastic Surgery, 5405 Miramar Lane, Colleyville, TX 76034; e-mail: yducic@sbcglobal.net.*

DOI 10.2310/7070.2007.E0017

room, and a biopsy of this mass revealed the presence of metastatic acinic cell carcinoma.

Discussion

Acinic cell carcinoma is a low-grade malignancy that most commonly involves the major salivary glands. It occurs in the parotid gland in 86% of cases. Women are preferentially affected (58%), and patients present at a younger age (median 52 years) than those with most salivary malignancies. Recurrences are most often local or regional and occurred in 34% of patients entered in the National Cancer Data Base from 1985 to 1990. Distant metastatic disease is rare and typically involves the lungs and bones. The overall 5-year survival is 83.3%, with a disease-specific survival of 91.4%. Factors associated with a decreased survival include high grade, age of 30 or greater, and metastatic disease.²

Acinic cell carcinoma typically presents as a painless, solitary parotid mass. Grossly, the tumour is usually soft, soft greyish-white, and encapsulated. With hematoxylin-eosin staining, the cytoplasm typically appears to be basophilic and granular but may be vacuolated in some cases. Tumour cells are round or polygonal, with inconspicuous nucleoli and eccentrically placed nuclei. Cell patterns may resemble acini, intercalated duct cells, or transitional morphology.³ Ultrastructural evidence supports the origin of acinic cell carcinoma from intercalated duct reserve cells, which may develop into acini during normal development.⁴

Central nervous system metastases are exceedingly rare with acinic cell carcinoma. Given that there is no vascular communication between the parotid gland and the pituitary gland, it is unusual for a parotid acinic cell carcinoma to metastasize to the hypophysis. A haematogenous metastasis from the parotid gland would first pass

through the pulmonary circulation prior to reaching the central nervous system, assuming no abnormal vascular communications. Our patient had no evidence of arteriovenous shunts or other anomalies.

Metastatic disease to the pituitary gland is rare and was identified in 1% of 1857 autopsy specimens. The two most common primary sites involved with hypophyseal metastatic disease are breast cancer and lung cancer, respectively. There were no identified cases of metastatic salivary gland cancer to the pituitary specimens.^{3,5}

To our knowledge, this represents the first case of metastatic acinic cell carcinoma to the pituitary gland. As demonstrated in this article, differentiation preoperatively from benign adenoma is often difficult. Consideration of metastatic disease to the pituitary gland should be in the differential diagnosis in patients with a known history of carcinoma. The prognosis in this group of patients appears to be dismal.

References

1. Ellis GL, Auclair PL. Malignant epithelial tumors. In: Armed Forces Institute of Pathology, Atlas of tumor pathology: tumors of the salivary glands, third series fascicle 17. Bethesda (MD): Universities Associated for Research and Education in Pathology, Inc; 1996. p. 183.
2. Hoffman HT, Karnell LH, Robinson RA, et al. National cancer data base report on cancer of the head and neck: acinic cell carcinoma. *Head Neck* 1999;21:297-309.
3. Spiro RH, Huvos AG, Strong EW. Acinic cell carcinoma of salivary origin: a clinicopathologic study of 67 cases. *Cancer* 1978;41:924-35.
4. Chaudhry AP, Cutler LS, Leifer C, et al. Histogenesis of acinic cell carcinoma of the major and minor salivary glands. An ultrastructural study. *J Pathol* 1986;148:307-20.
5. Kovacs K. Metastatic cancer of the pituitary gland. *Oncology* 1973;27: 533-42.