

Metastatic basal cell carcinoma

Yadranko Ducic, MD, FRCS(C), FACS^{a,b,c,*}, Diego E. Marra, MD, FAAD^d

^aOtolaryngology and Facial Plastic Surgery Associates, Fort Worth, Texas

^bThe Baylor Neuroscience Center for Skullbase Surgery, Dallas, Texas

^cThe University of Texas Southwestern Medical Center, Dallas, Texas

^dMohs Surgery Private Practice, Fort Worth, Texas

Received 7 December 2009

Abstract

Objective: The purpose of this study is to review our series of metastatic basal cell carcinomas of the head and neck.

Study Design: A retrospective review was conducted for this study.

Methods: All cases of documented metastatic basal cell carcinomas arising from a primary within the head and neck region and presenting for treatment to one of the authors (Y.D.) were included in this review.

Results: Nine patients were available for review. Five patients had extension to but not transgression of the base of skull. Sites for metastatic disease included 4 lungs and 5 parotid glands. All metastatic lesions were treated with surgical excision, and 6 also received postoperative radiation therapy. No patient deaths from disease have been noted at an average follow-up of 4.7 years (range, 3–8.5 years). No evidence of further metastatic disease has been noted in any of these patients on follow-up.

Conclusions: Metastatic basal cell carcinoma arising from a head and neck primary is a rare entity. However, initial involvement of the skull base and/or dura by a basal cell carcinoma appears to warrant a complete metastatic workup and metastatic surveillance. When metastatic disease is discovered, it appears to be well treated by surgical resection with/without adjunctive radiation therapy. We do not favor chemotherapy for resectable basal cell carcinomas.

© 2011 Elsevier Inc. All rights reserved.

1. Introduction

Basal cell carcinoma represents the most common skin cancer in the Caucasian population. Metastatic disease arising from basal cell carcinomas in the head and neck region is exceptionally rare, occurring at an estimated rate of only 0.03% [1]. The true incidence of metastatic basal cell carcinomas (MBCCs) may be higher, with under-reporting arising because of rarity of diagnosis and lack of awareness on the part of clinicians [2]. Less than 300 cases have been reported in the world literature to date, most

consisting of case reports or case series of less than a handful of patients [3].

In 1894, Beadles [4] reported a case of a so-called rodent ulcer deposit within lymphatic gland tissue. Later, Lattes and Kessler [5] described the most widely accepted criteria for a diagnosis of MBCC to include the following: (a) the primary lesion and metastasis cannot be primarily squamous; (b) the primary tumor may not originate in salivary glands or mucous membranes, and (c) the metastatic nodules must be in lymph nodes or distinct from the primary tumor.

In this article, we will review our series of MBCC all of which arose from a primary extending to or transgressing the skull base.

2. Study design

This study involved retrospective case series.

* Corresponding author. Otolaryngology and Facial Plastic Surgery Associates, 923 Pennsylvania Avenue, Suite 100, Fort Worth, Texas 76104. Tel.: +1 817 920 0484; fax: +1 817 927 1605.

E-mail address: yducic@sbcglobal.net (Y. Ducic).

3. Methods

All cases presented to one of the authors (Y.D.) who had documented MBCC per classic criteria as outlined by Lattes and Kessler and cases with a minimum follow-up of 3 years were reviewed. Demographic data, pathology, radiographic imaging, treatment, and follow-up data were all collected. Institutional review board approval was obtained for this study.

4. Results

A total of 9 patients were available for review as defined above. The male/female ratio was 5:4 with a mean age of 63.2 years at presentation (range, 42–72 years). The average

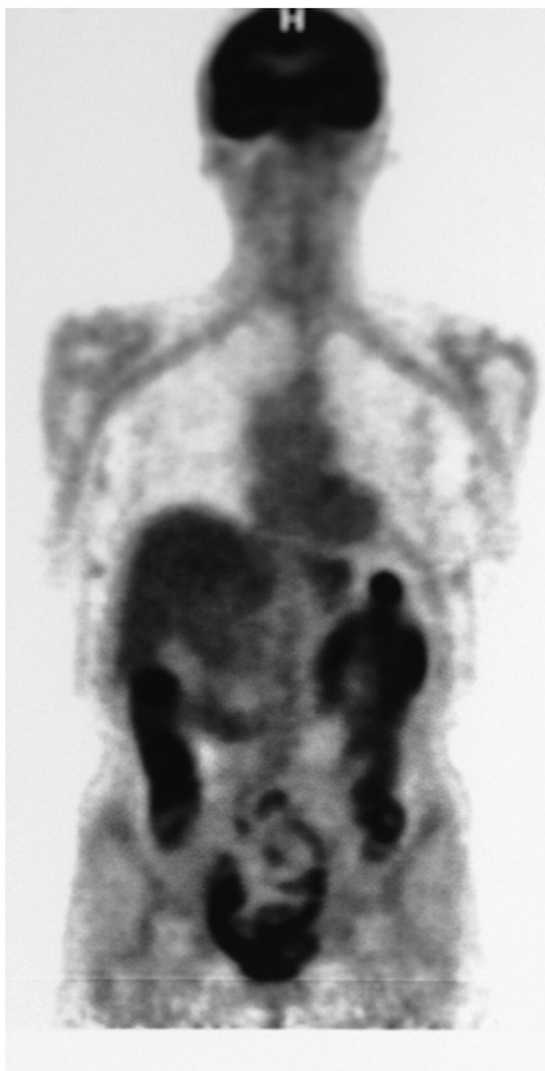

Fig. 1. Positron emission tomography scan demonstrating a positron emission tomography–avid lung metastasis in a patient with known massive primary basal cell carcinoma of the left face, nose, orbit, and base of intracranial fossa with dural involvement.

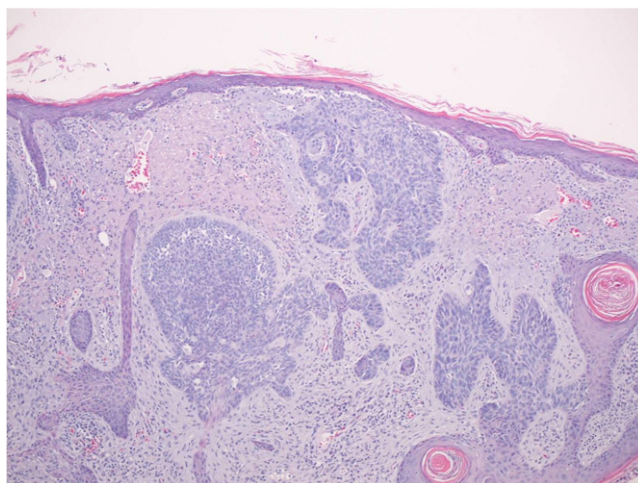


Fig. 2. Nests of invasive basal cell carcinoma at the primary site (hematoxylin and eosin, original magnification $\times 40$).

primary lesion dimension was 10.4 cm (range, 5–22 cm). The average time to presentation/discovery of metastatic disease was 2.5 years (range, 0–4.2 years). Four patients had dural involvement, and one of these had focal brain parenchymal involvement. The remaining patients all had extension to but not transgression of the base of skull. Sites for metastatic disease included 4 lungs (3 solitary, single patient with 2 lung sites) and 5 parotid glands (Figs. 1–3). The parotid gland lesions were metastatic to intraparotid lymph nodes. All cases were reviewed by at least 2 pathologists. All metastatic lesions were treated with surgical excision, and 6 also received postoperative radiation therapy. Local recurrence occurred in 2 patients who underwent further surgery and radiation. No patient deaths from disease have been noted at an average follow-up of 4.7 years (range, 3–8.5 years). No evidence of further metastatic disease has been noted in any of these patients on follow-up.

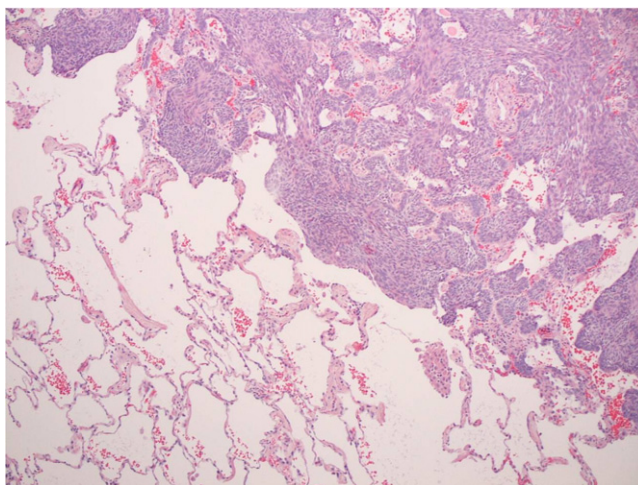


Fig. 3. Invasive basal cell carcinoma invading normal lung tissue (hematoxylin and eosin, original magnification $\times 40$).

5. Discussion

There appears to be an almost equal rate of hematogenous and lymphatic spread of basal cell carcinomas, with a slight predominance of the former route, in case reports as reviewed by von Domarus and Stevens [6]. Our patient series favored the lymphatic route of spread.

Immunohistochemically, MBCCs have not been reported to exhibit certain characteristics more frequently as compared with their nonmetastatic counterparts. Immunohistochemical markers for Ki-67, p53, and Bcl-2 were similar when a group of MBCC was compared with a nonmetastasized population [7]. Uzquiano et al [1] have suggested that there is increased actin formation in locally aggressive basal cell carcinomas but not in metastatic lesions. In addition, they suggest that a history of prior radiation therapy may be associated with metastatic lesions [1]. None of our patient population has a history of having received radiation therapy to the primary site before definitive surgical resection. Histologically, metastatic lesions appear to be indistinguishable in general terms from aggressive forms of nonmetastatic lesions both at the primary and distant metastatic site. Aggressive variants of basal cell carcinoma such as morpheaform, infiltrating and metatypical, are more commonly seen both in metastasizing and nonmetastasizing aggressive primary lesions [3].

Conway and Hugo [8] reported that many cases of MBCC arose from lesions that were often large and neglected for many years. Historic data have suggested that intervals between diagnosis of the primary and the appearance of metastatic disease have varied from 7 to 43 years, but intervals from diagnosis of metastatic disease to death from disease have been short [9,10]. Our experience with basal cell carcinomas extending to and through the skull base favors a more rapid development of metastatic disease that appears to be quite responsive to intervention with curative intent both at the level of the primary and distant sites. We do report interval from treatment of the primary as opposed to diagnosis of the primary as was noted in many previous studies. Many of our patients had a longstanding diagnosis of basal cell carcinomas, but for a variety of reasons, they neglected their lesions until they grew often times to massive proportions.

Traditionally, no metastatic workup has been felt to be necessary for basal cell carcinomas. Some authors have suggested the use of sentinel lymph node biopsy in high-risk lesions [11]. There are no significant data to support the use of this modality in this patient population. Moreover, because there is as significant a risk of hematogenous spread, this would not appear to be beneficial. Approximately two thirds of reported cases of MBCC arise from a primary within the facial region [12]. Snow et al [12] reported that primary tumors greater than 3 cm in dimension had a rate of metastatic disease of 1.9%. Smaller lesions had exceptionally rare metastatic disease. It would seem logical that massive, neglected lesions present for extended periods before treatment would have the highest rates of metastatic disease present. All of the patients in our series of MBCC had

extension to or transgression of the skull base. Extension to this area appears to confer a significant potential for formation of metastatic deposits. The generous vascular supply in the brain parenchyma, dura, and immediate subjacent base of skull region makes such spread more likely to be seen. Based on our data, we would recommend metastatic workup and surveillance in patients with basal cell carcinomas extending to the skull base from a primary in the head and neck region. Our lesions all metastasized to the parotid gland lymph node basin and lungs. Thus, imaging to include the neck/parotid and chest should be considered. In our series, we did not find any patient with MBCC who did not have initial skull base extension, despite often having massive primary lesions.

Treatment of basal cell carcinomas has traditionally been surgical. Radiation therapy may be offered as primary definitive therapy for poor surgical candidates and in cases where there is patient refusal to undergo surgery. Adjunctive radiation therapy has been useful in high-risk lesions (deep invasion, perineural/intravascular spread, and positive margins) after surgical excision. The ideal treatment of MBCC has not been elucidated to date because of the paucity of data on the subject. Meaningful prospective trials are not going to be possible for this subset of patients. It would make sense that metastatic lesions would respond or fail to respond to treatment modalities as their primary counterparts. Thus, we treated all metastatic lesions to the parotid gland with parotidectomy (partial nerve sparing where possible) and postoperative radiation therapy. Lung lesions were all treated with resection, with one patient receiving localized radiation therapy for a close margin.

Despite reports in the literature favoring systemic chemotherapy for metastatic disease, we do not feel that it has been shown to be effective to recommend it as a proven modality on the setting of MBCC [13,14]. Newer agents may be more effective in this regard. This remains to be seen. At this time, we favor surgical excision of distant metastatic lesions when possible and adjunctive radiation therapy for metastatic lesions in the head and neck region.

Historically, prognosis for MBCC has been grim [15]. Many cases in the literature presented with widely disseminated disease at the time of initial diagnosis. This scenario certainly seems unfavorable and may be related to historically less accurate imaging seen in the past when many of these cases were reported. Our series of patients appears to have responded favorably to intervention as outlined above, but certainly, follow-up for at least 10 years will be required to ascertain cure because some cases of MBCC may have decade-long latency periods between development of distant lesions.

6. Conclusions

Metastatic basal cell carcinoma arising from a head and neck primary is a rare entity. However, initial involvement of the skull base and/or dura by a basal cell carcinoma appears

to warrant a complete metastatic workup and metastatic surveillance. When metastatic disease is discovered, it appears to be well treated by surgical resection with/without adjunctive radiation therapy. We do not favor chemotherapy for resectable basal cell carcinomas.

References

- [1] Uzquiano MC, Prieto VG, Nash JW, et al. Metastatic basal cell carcinoma exhibits reduced actin expression. *Mod Pathol* 2008;5: 540-3.
- [2] Wadhera A, Fazio M, Bricca G, et al. Metastatic basal cell carcinoma: a case report and literature review. How accurate is our incidence data? *Dermatol Online J* 2006;5:7-10.
- [3] Ting PT, Kasper R, Arlette JP. Metastatic basal cell carcinoma: a report of 2 cases and literature review. *J Cutan Med Surg* 2005;1:10-5.
- [4] Beadles CF. Rodent ulcer. *Transcripts Pathol Soc London* 1894;45: 176-7.
- [5] Lattes R, Kessler RW. Metastasizing basal cell epithelioma of skin. *Cancer* 1951;4:866-78.
- [6] Domarus H, Stevens PJ. Metastatic basal cell carcinoma. *J Am Acad Dermatol* 1984;10:43-60.
- [7] Ionesu DN, Arida M, Jukic DM. Metastatic basal cell carcinoma: four case reports, review of literature and immunohistochemical evaluation. *Arch Pathol Lab Med* 2006;1:45-51.
- [8] Conway H, Hugo NE. Metastatic basal cell carcinoma. *Am J Surg* 1965;620-2.
- [9] Warmuth BM, Fajardo LF. Metastatic basal cell carcinoma: a review. *Arch Pathol* 1970;458-62.
- [10] Costanza ME, Dayal Y, Binder S. Metastatic basal cell carcinoma: a review, report of a case and chemotherapy. *Cancer* 1974;230-6.
- [11] Harwood M, Wu H, Tanabe K, et al. Metastatic basal cell carcinoma diagnosed by sentinel lymph node biopsy. *J Am Acad Dermatol* 2005; 3:475-8.
- [12] Snow SN, Sahl W, Lo JS, et al. Metastatic basal cell carcinoma. Report of five cases. *Cancer* 1994;2:328-35.
- [13] Woods RL, Stewart JF. Metastatic basal cell carcinoma: report of a case responding to chemotherapy. *Postgrad Med J* 1980;654:272-3.
- [14] Coker DD, Elias EG, Viravathana T, et al. Chemotherapy for metastatic basal cell carcinoma 1983(119)1:44-50.
- [15] Smith JM, Irons GB. Metastatic basal cell carcinoma: a review of the literature and report of three cases. *Ann Plast Surg* 1983;6:551-3.