



Midface lifts

Robert DeFatta, MD, PhD, Yadranko Ducic, MD, MSc, FRCS(C), FACS

From the Center for Aesthetic Surgery, Colleyville, Texas.

KEYWORDS

Midface lift;
Cheek implants;
Facelift;
Periorbital
rejuvenation

Age is the most significant factor contributing to the overall change in the appearance of an individual's facial features over time. This gradual process of structural weakening of the face begins during the third decade and continues to worsen during the remainder of an individual's lifetime. The purpose of the midface lift procedure is to reverse some of the central third changes seen early in the aging process. This can be accomplished through a variety of techniques that have been developed to date. However, whichever procedure is used, the ultimate goal is the same. The aim is to reposition the facial tissues in such a way as to return a more youthful and rested appearance to an individual's face in lieu of introducing an "operated appearance" during the process. In this article, we cover three techniques that we use to address the midface, depending on the individual. These include the subciliary approach to the midface, the endoscopic approach to the midface, and the use of alloplastic contouring of the midface.

© 2007 Elsevier Inc. All rights reserved.

Age is the most significant factor contributing to the overall change in the appearance of an individual's facial features over time. This gradual process of structural weakening of the face begins during the third decade and continues to worsen during the remainder of an individual's lifetime (Figure 1). One of the earliest changes to occur is the descent of the eyebrows, creating the appearance of smaller eyes. This is followed by the appearance of excess skin laxity, pseudoherniation of orbital fat through a weakened septum in both the upper and lower eyelids, the formation of glabellar frown lines, and an increased prominence of the nasolabial folds during the fourth decade. The fifth decade brings deepening of the forehead wrinkles, glabellar furrows, and crow's feet. At the same time, in the lower face, jowling begins to occur along the mandibular line, and vertical lines begin to form in the perioral region. In the sixth decade, prominent wrinkling occurs in the perioral region and the neck, the nose begins to droop, and the lateral canthus weakens, causing a downward slant of the lateral eyes. Also, the glabellar and forehead wrinkles continue to deepen and become evident even at rest. One of the most prominent occurrences in the aging process is the descent of the midface structures, which results in a worsening appear-

ance of the nasojugal folds and lower eyelids. The seventh decade brings a thinning of the skin and fat resorption throughout the face. Finally, during the eighth decade, all of the changes to this time are exaggerated while the skin continues to thin because of a diminishing subcutaneous fat distribution.¹

The purpose of the midface lift procedure is to reverse the aging process that has occurred in an individual. This can be accomplished through various techniques have been developed to date. However, whichever procedure is used, the ultimate goal is the same. That is, to reposition the facial tissues in such a way as to return a more youthful and rested appearance to an individual's face in lieu of introducing an "operated appearance" during the process (Figure 2).

History

Before the First World War, physicians were often guarded in sharing their wisdom regarding cosmetic surgery procedures because of the lack of its acceptance. In fact the American medical establishment of the 1920s called for a ban on cosmetic surgery.²

The first case of surgical treatment of rhytids occurred in 1912 by Dr. Hollander.³ Shrouded in secrecy, distinguished European physicians such as Lexer, Passot, Joseph, and Noel continued to refine facial rejuvenation techniques.⁴⁻⁷ During this time, Miller is credited as publishing the first

Address reprint requests and correspondence: Yadranko Ducic, MD, MSc, FRCS(C), FACS, Center for Aesthetic Surgery, 75 Main Street, Suite 150, Colleyville, TX 76034.

E-mail address: yducic@sbcglobal.net.

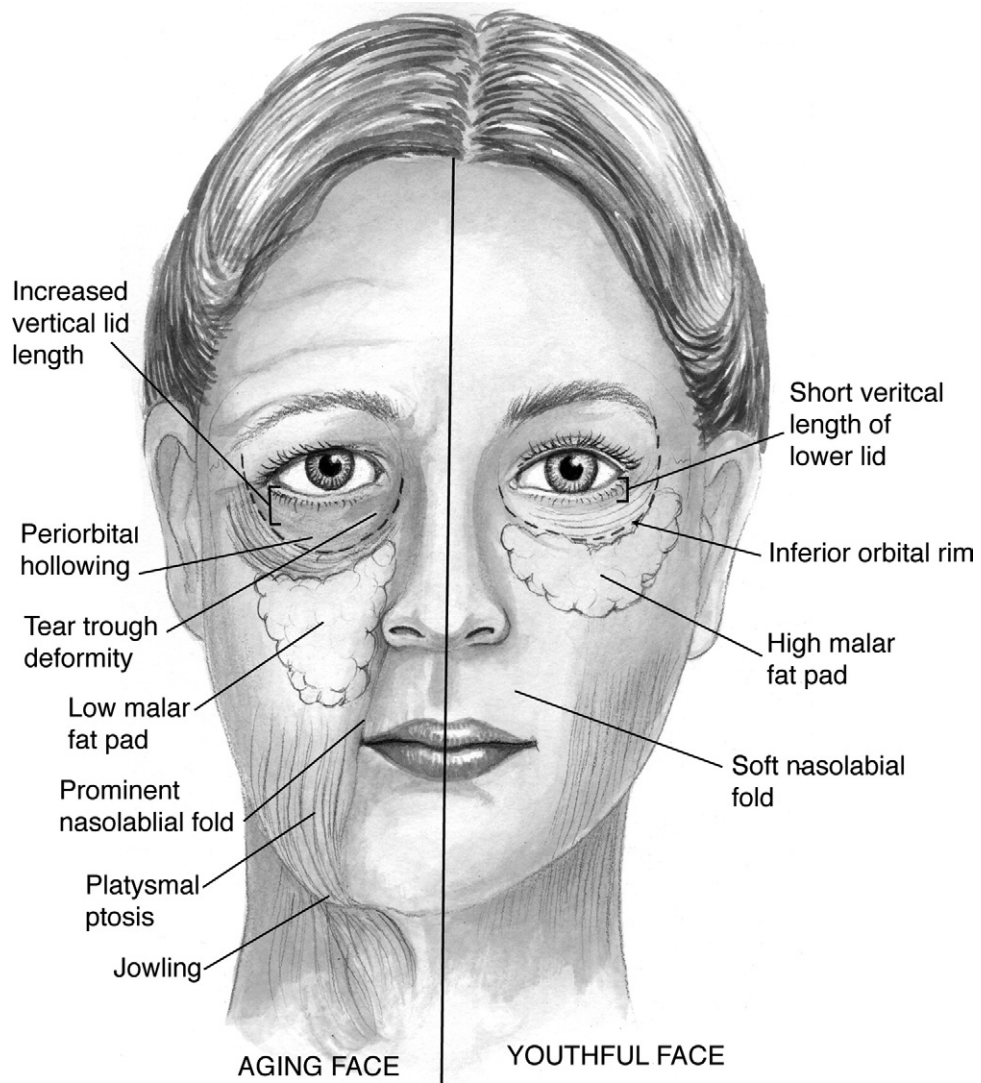


Figure 1 Midface changes during the aging process.

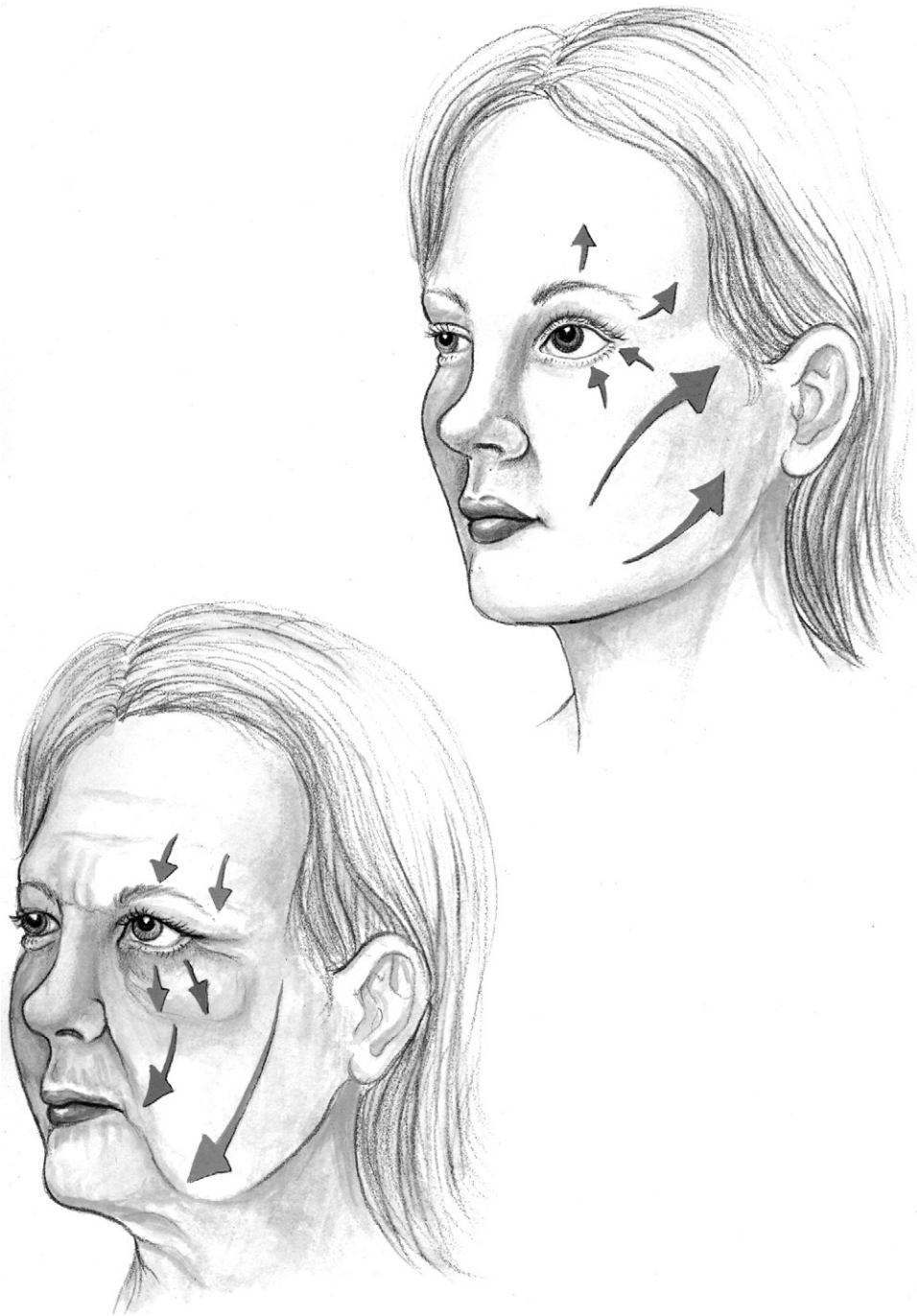
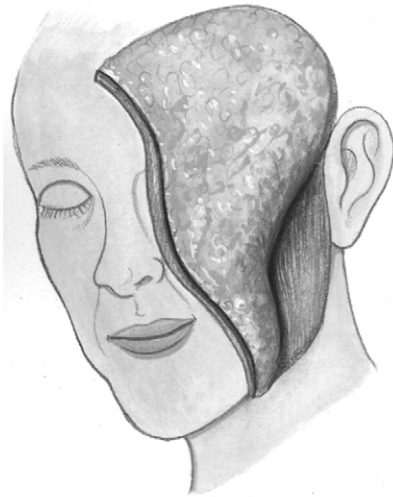
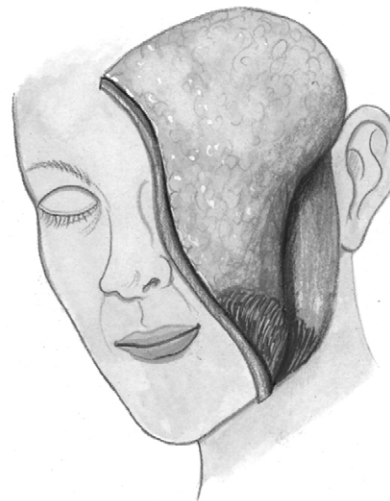

Figure 2 Vectors of change that occur in the face with aging.

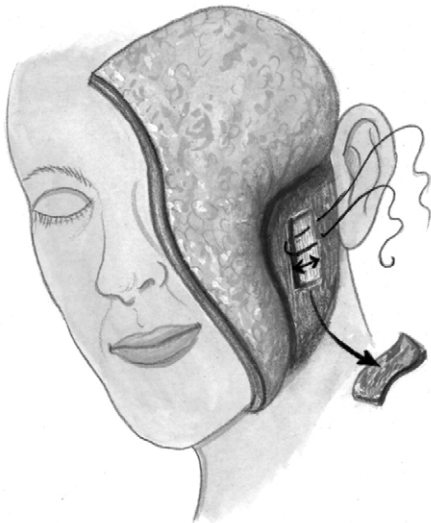A. Subcutaneous Rhytidectomy



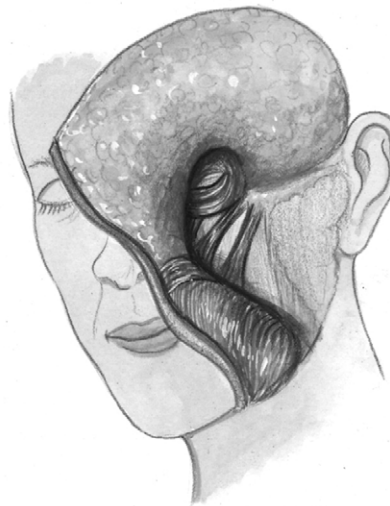
B. Skoog Rhytidectomy



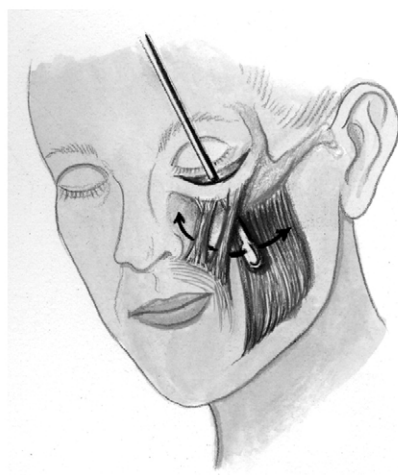C. SMAS Rhytidectomy



D. Deep Plane Rhytidectomy



E. Subciliary Rhytidectomy



F. Endoscopic Rhytidectomy

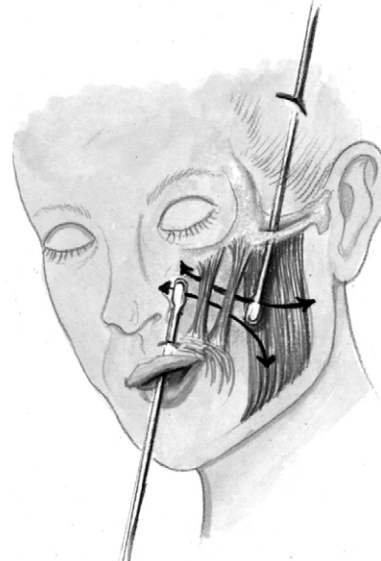


Figure 3 Rhytidectomy techniques.

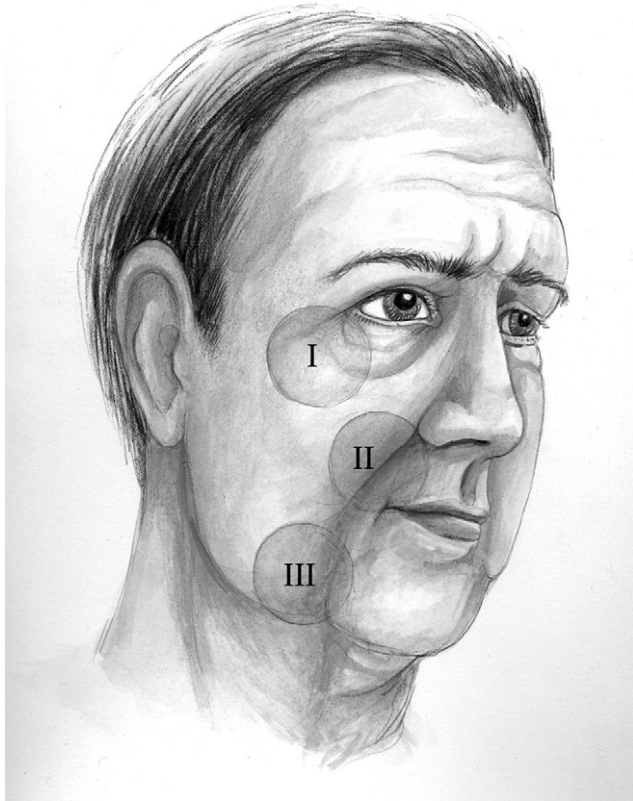


Figure 4 Treatment zones to be analyzed during preoperative consult.

article furthering the development and refinement of the midface lift in the United States.⁸

These first techniques consisted of interrupted incisions placed both in front of and behind the ears in natural creases, and were combined with limited strips of excised skin. In 1919, Bourguet⁹ and Bettman¹⁰ were independently credited with the first subcutaneous rhytidectomy. Unlike previous procedures, this one consisted of extensive undermining and lipectomy. The next significant contribution occurred in 1928 when the posttragal incision was introduced by Joseph.⁶

More recently, technique modifications have occurred to address the dissatisfaction from the lack of long-term correction that occurred with the “classic” skin undermining from the procedures described in the early 1900s. In 1960 Aufrecht attempted to prolong the longevity of the lift by advocating suturing deep to the superficial fat (Figure 3A),¹¹ which was followed by the Skoog technique in 1968 where the fascia and platysma muscle were undermined to the level of the melolabial fold and jowl in an attempt to address the lower third of the face (Figure 3B).¹² In 1976, the discovery of the superficial musculoaponeurotic system by Mitz and Peyronie¹³ confirmed the existence of a fascial layer investing the facial mimetic musculature. This layer was noted to lie in a tissue plane that is continuous with the platysma below and the temporoparietal fascia above, and anatomically distinct from the underlying parotidomasseteric fascia. It is also important to note that this was the first approach that advocated the effectiveness of imbrication as a rhytidectomy technique (Figure 3C).

In the 1990s, the emphasis turned to improving the midface, traditionally the most difficult region of the face to effectively address. This was accomplished through the introduction of the deep plane and composite rhytidectomy. Pioneered by Hamra, these techniques proved to be effective at achieving improvement in the nasolabial region (Figure 3D).¹⁴

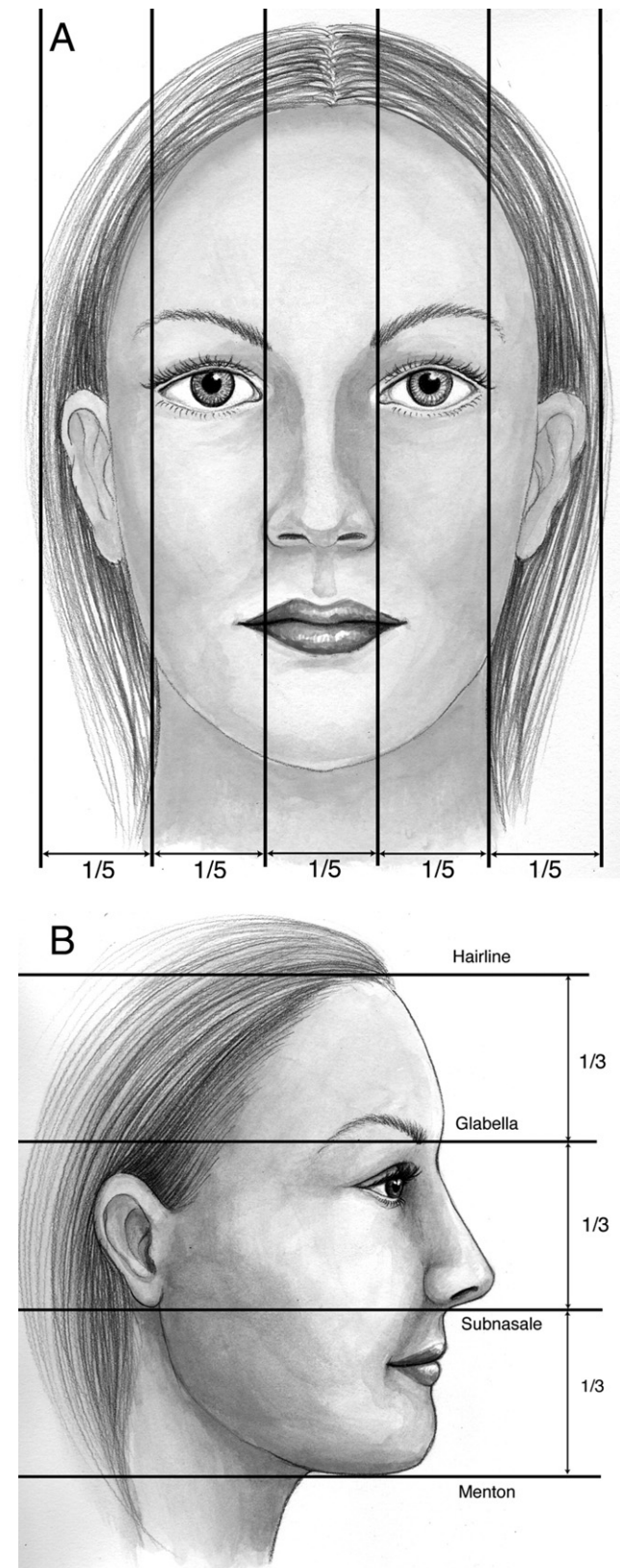


Figure 5 Preoperative analysis: (A) Vertical fifths; (B) horizontal thirds.

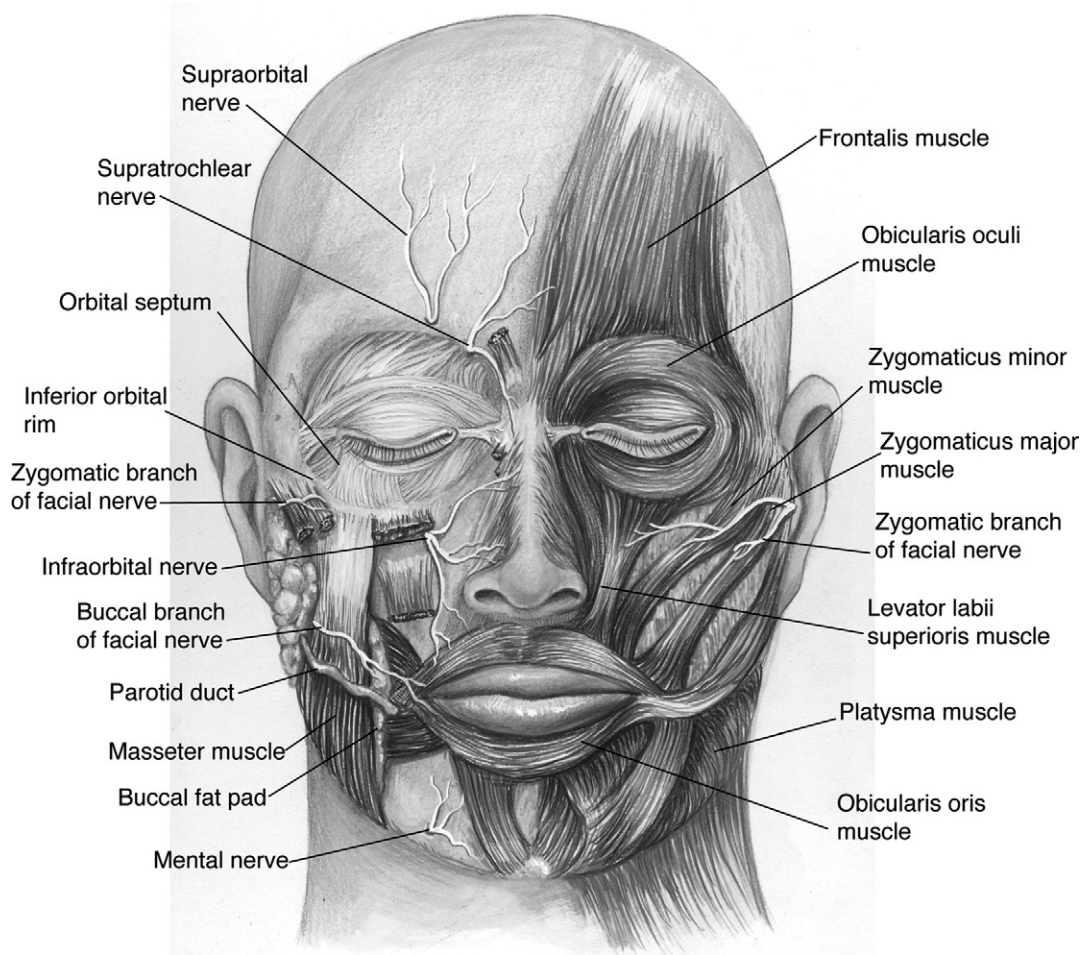


Figure 6 Muscles of facial expression.

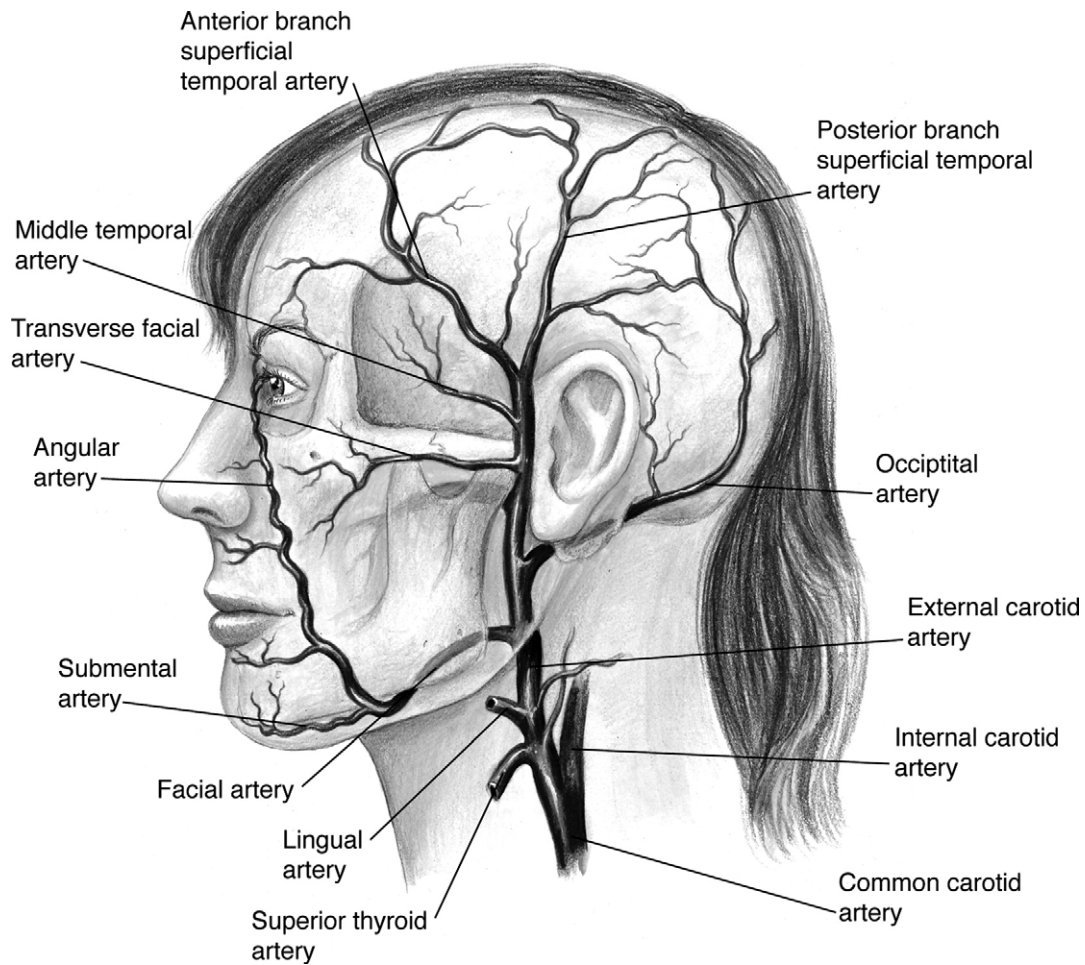


Figure 7 Vascularity of the face.

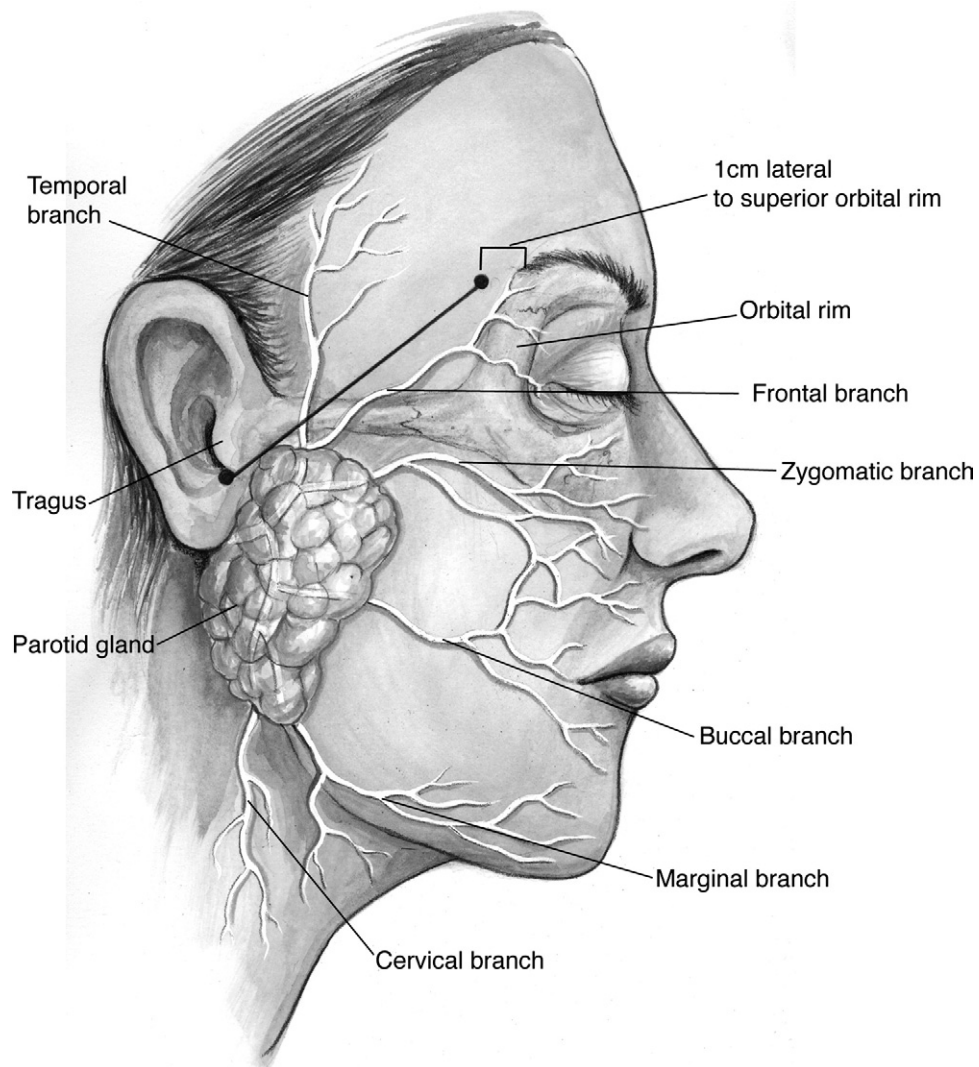


Figure 8 Anatomic relation of facial nerve frontal branch to zygomatic arch and orbital rim.

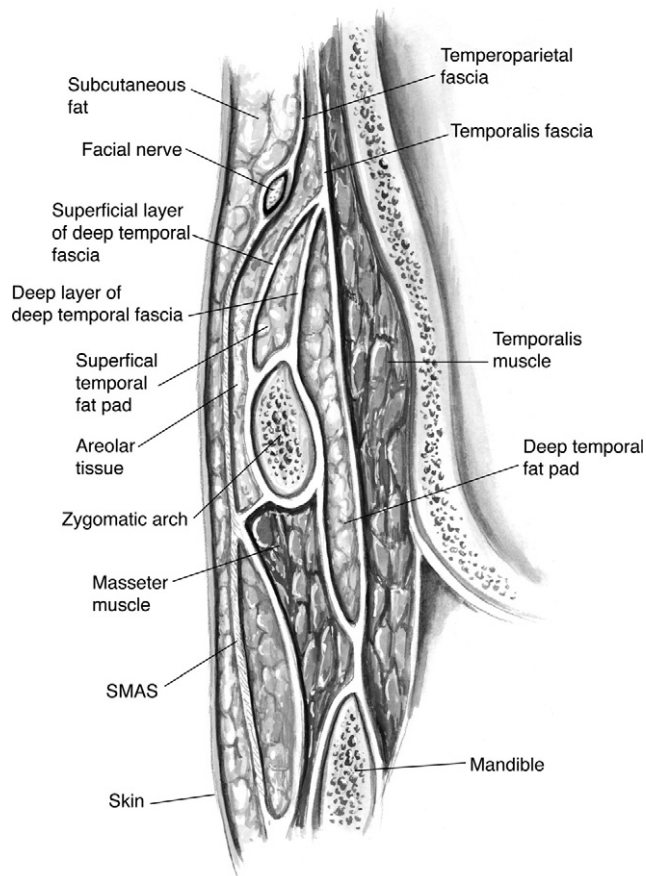


Figure 9 Coronal view of the facial nerve frontal branch as it crosses the zygomatic arch.

The importance of the advances introduced by Hamra is exemplified by their incorporation into newer, less invasive techniques, ie, the subciliary (Figure 3E)¹⁵ and the endoscopic approach (Figure 3F)¹⁶ to the midface. Because the principles from all of the previously described techniques were applied to the development of these latter 2 techniques, these will be the ones discussed in detail in this article.

Initial evaluation

When a patient presents for initial evaluation for midface rejuvenation surgery, it is important to note all of the areas that need to be addressed. It is easiest to evaluate a patient by dividing their face into three independent zones that can be addressed through the traditional midface lift (Figure 4). Zone I represents the malar and orbital complexes while zone II is the nasolabial groove. Finally, zone III corresponds to the jawline. It is important to note that the endoscopic approach to the midface also allows for treatment of the brows and forehead at the same time as the midface is addressed.

Another important aspect of the initial evaluation is to determine the patient's facial symmetry. It is of the upmost importance to not only consciously note any asymmetry that a patient may have, but also enlighten the patient as to these imperfections during the preoperative assessment.

On the frontal view, an individual's face can be divided into five equal parts (Figure 5A). When analyzing a client

with this method, it is important to note that the medial canthal distance should equal the nasal alar width. These distances should be proportional to the patient's intercanthal distance. Likewise, on the lateral view (Figure 5B), the face should be able to be divided into 3 equal parts, with the midface being bordered by the glabella superiorly and the subnasale inferiorly.

Anatomy

No matter which procedure is chosen, an intricate understanding of the anatomy is an absolute must to prevent complications, as well as to obtain a lasting result in a patient while preventing an "operated appearance." The various mimetic muscles (Figure 6) are what allow for an individual's facial expression. However, with age, muscle laxity, along with, decreased tone of the overlying subcutaneous fat and the skin all contribute to the aging process. It is important to note that once the various branches of the facial nerve exit the parotid gland, they follow a course that is intimately associated with the superficial surface of the mimetic muscles before they terminate in their respective locations. As with the facial nerve, the main blood supply traverses throughout the face in a plane superficial to the musculature. It is important to note that the blood supply to the face occurs through branches of the external carotid artery (Figure 7). Independent of whether a superficial or a deep plane midface lift is planned, it is this rich vascular supply to the face which prevents the loss of skin due to devascularization.

One of the feared complications after a midface rhytidectomy is a facial paralysis or paresis. As with the vascular supply to the face, the facial nerve branches run superficially to the facial musculature once they exit the parotid gland. The most commonly injured branch of the facial nerve is the temporal branch, which commonly occurs when elevating over the zygomatic arch. As with the marginal mandibular branch, injury to temporal branch is significantly more noticeable when compared with the other branches of the facial nerve because there is no cross-innervation in these branches.

The course of the temporal branch is fairly consistent as it traverses the zygomatic arch. The course of the nerve can be estimated by drawing a straight line from the bottom of the tragus to a point 1 cm lateral to the superior orbital rim (Figure 8). The frontal branch should course in very close vicinity to where the line crosses the zygoma. Not only knowing the path of the temporal branch, but also the fascial layer through which it traverses is paramount to preventing an injury. As depicted in Figure 9, the temporal branch crosses over the zygoma through the temporoparietal fascia, a layer that is superficial to the temporalis fascia and the underlying temporalis muscle.

Subciliary approach to the midface

As evidenced in Figure 1, aging leads to significant changes in both the lower eyelid complex and the midcheek, both of which are 2 of the most common causes of a patient's initial

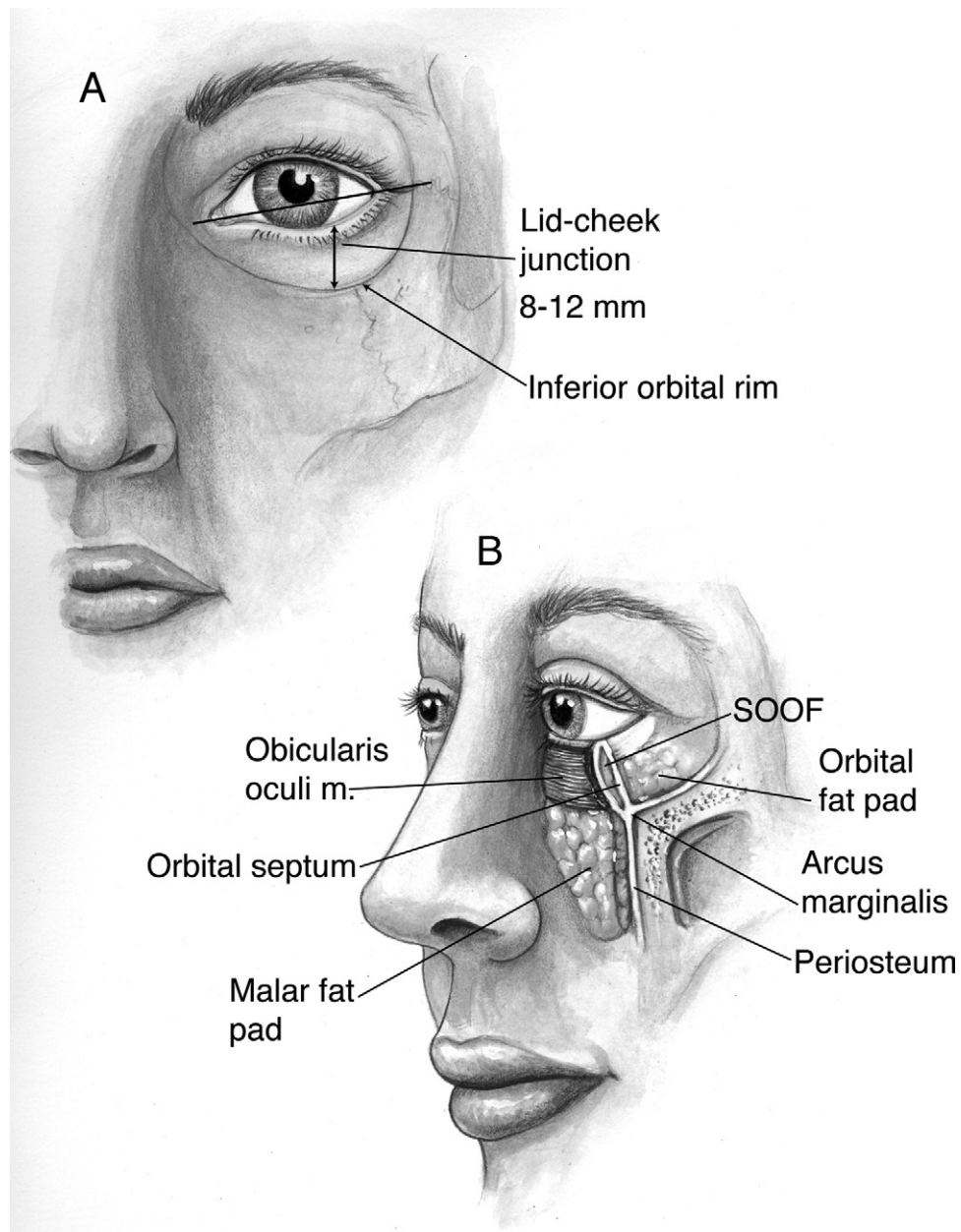


Figure 10 Youthful eyelid: (A) Frontal view; (B) three-quarter view.

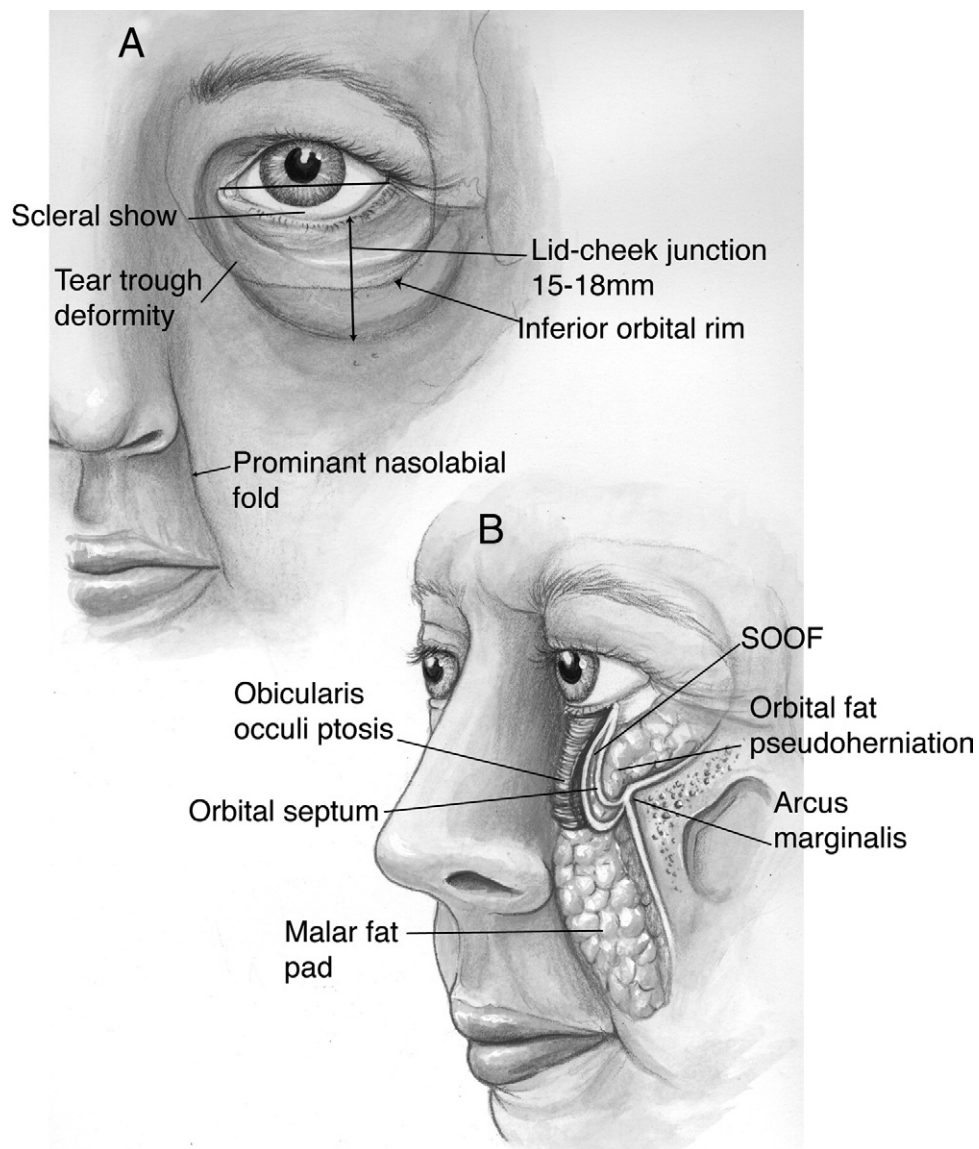


Figure 11 Changes in the aging eyelid: (A) Frontal view; (B) Three-quarter view.

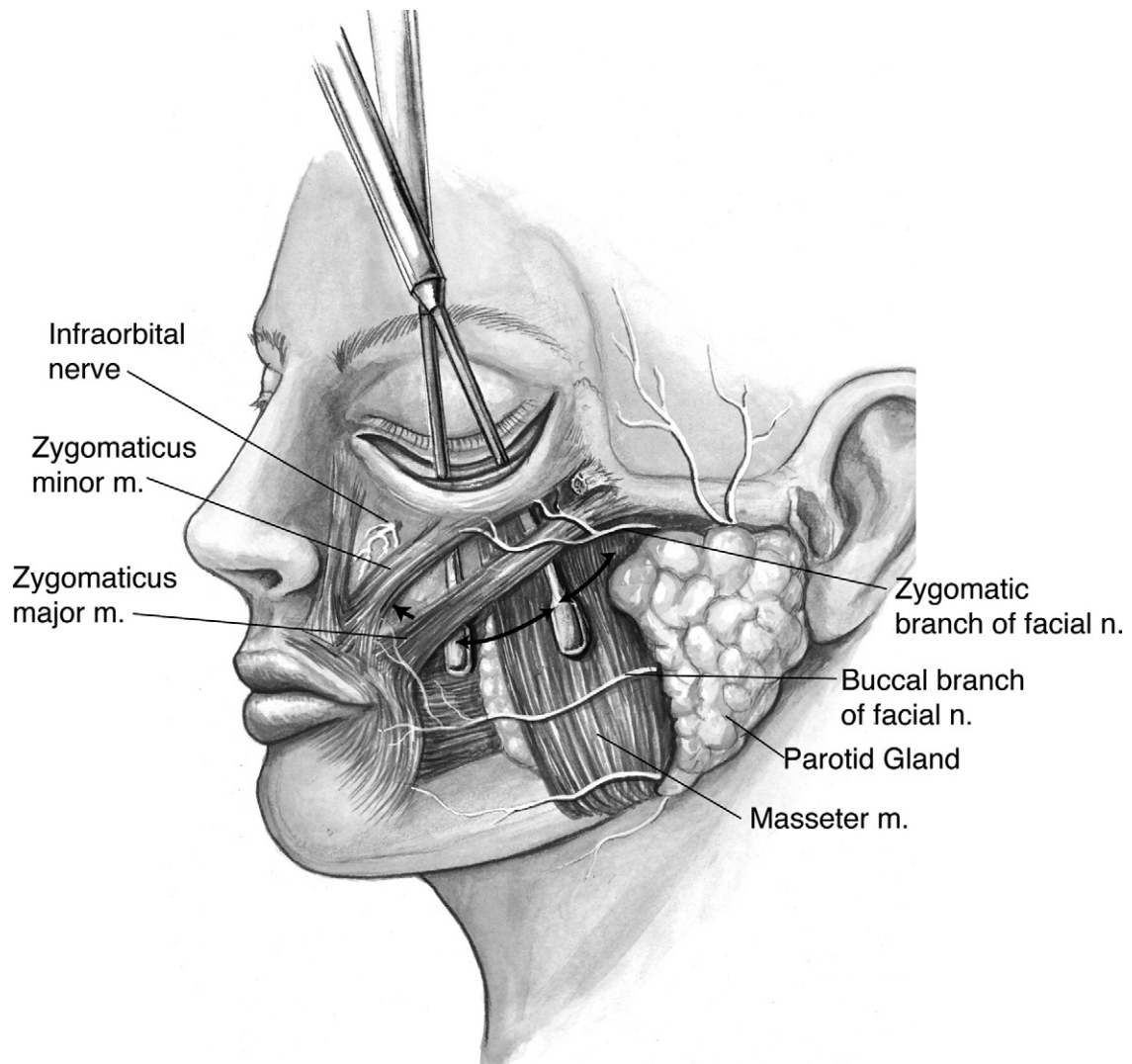


Figure 12 Subciliary approach to the midface.

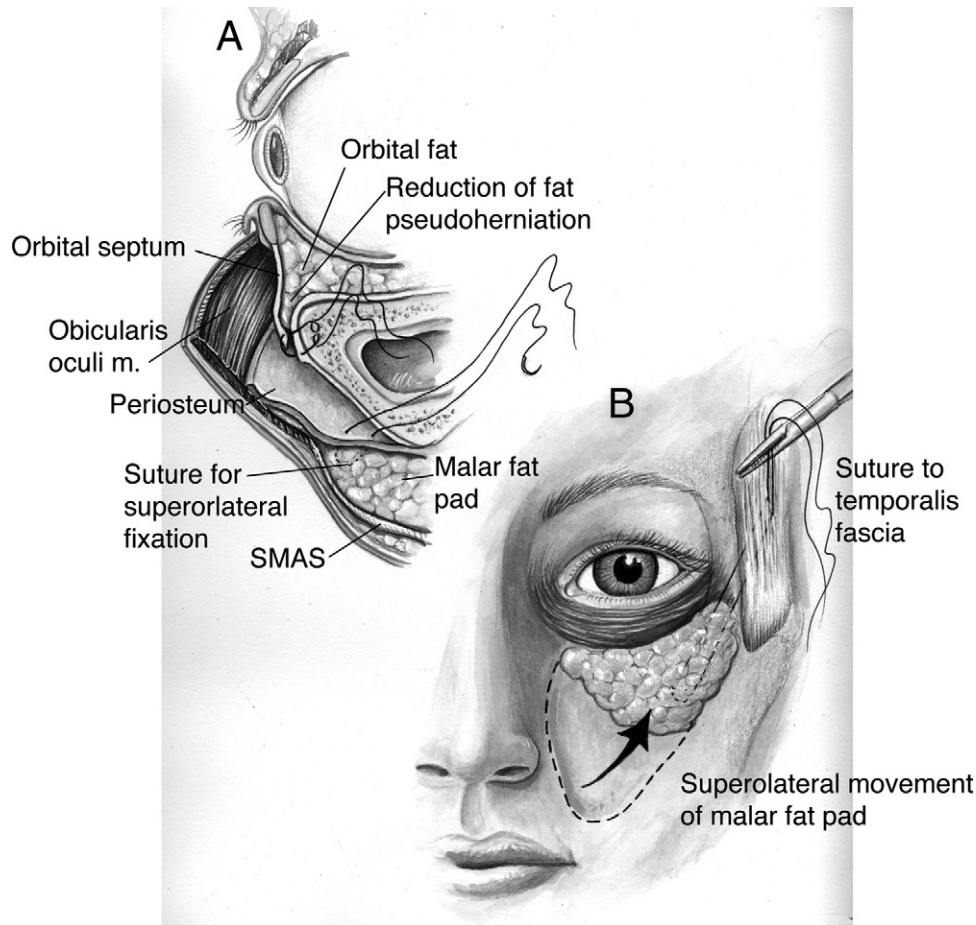


Figure 13 Suturing during subciliary approach to the midface: (A) Lateral view illustrating reduction of orbital fat pseudoherniation through repositioning of the arcus marginalis. (B) Frontal view illustrating the superiolateral movement of the malar fat pad to address the nasolabial folds.

consultation for facial rejuvenation. It should also be noted that correction of these area are some of the most difficult to effectively improve with natural and long lasting results through a traditional midface technique. Therefore, this was the initial impetus for a more direct, safe approach to address this area of the face.

A youthful eyelid consists of a slight upward slope from the medial to lateral canthi (Figure 10), along with an almond-shaped horizontal palpebral fissure. With the patient in forward gaze, the lower eyelid should be positioned either 1 to 2 mm above the lower edge of the limbus (nonprominent eye) to slightly below the limbus (prominent eye). The lower eyelid should have good tone and be free of tarsal ligament laxity, canthal tendon laxity, pseudo herniation of fat, or skin excess. In the youthful patient, the distance from the upper edge of the lower eyelid to the lid/cheek junction should be no more than 8 to 12 mm. In addition, this transition should be smooth and positioned at the infraorbital rim.

During the aging, rounding of the palpebral fissure occurs along with laxity of the lateral canthal tendon. It is the lateral canthal tendon laxity which lead to a lose of the upward slant of the lateral canthus, resulting in a tired appearance of the eyes (Figure 11). The combination of these defects, along with laxity of the tarsal ligament, results in an elongation of the vertical aperture of the eye and eventual scleral show.

A combination of laxity in both the muscle and skin lends to decreased eyelid tone which allows for visual irregularities in the lower eyelid secondary to pseudo herniation of fat through the orbital septum. The increased laxity ultimately results in a descent of the lid/cheek junction and increased vertical length of the lower eyelid, the combination of which allows for the visualization of the infraorbital rim through the lower eyelid skin. At this time,

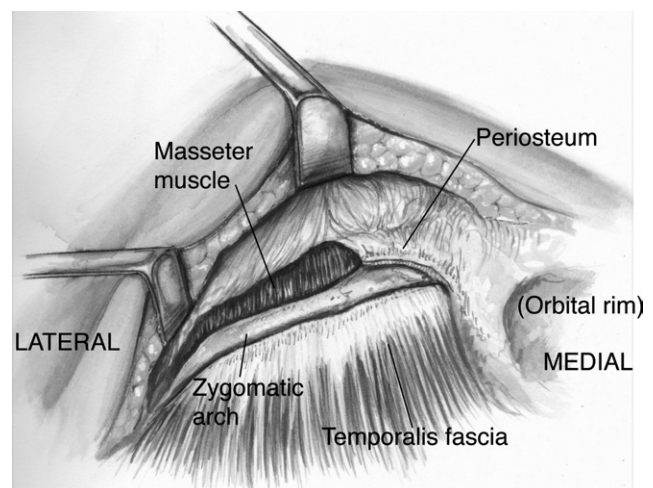


Figure 14 Plane of dissection at the zygomatic arch during the endoscopic midface lift.

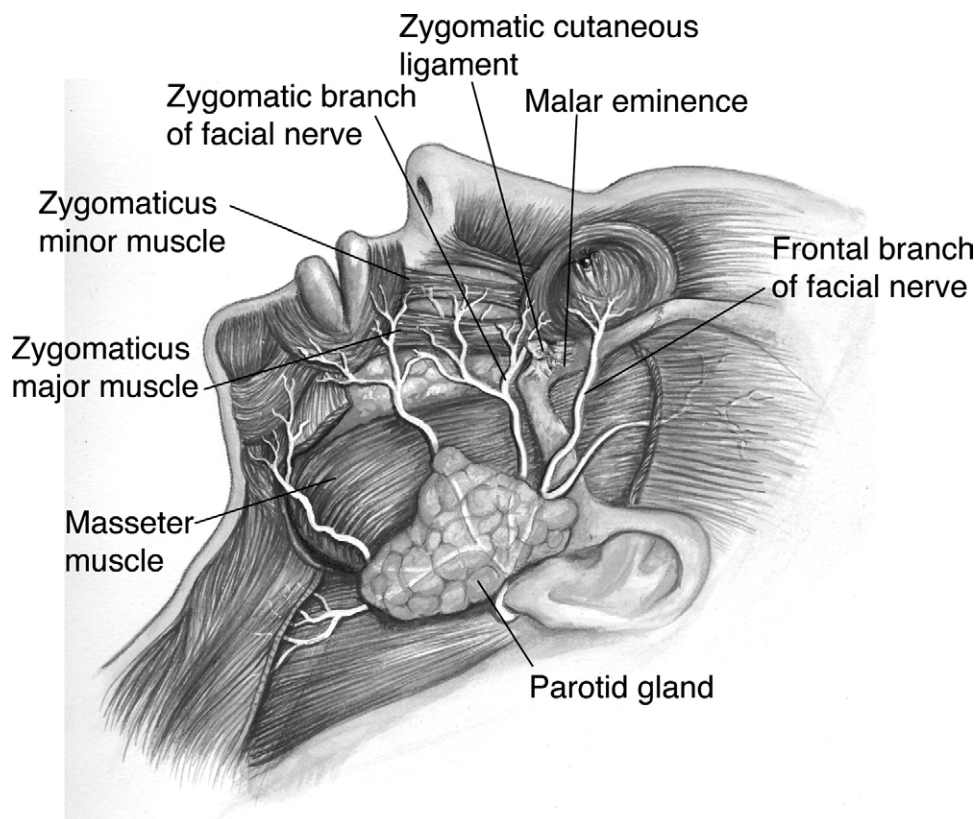


Figure 15 Relation of zygomatic branch of the facial nerve to the zygomatic cutaneous ligament.

the malar fat pads descend, resulting in a loss in the cheek prominence, a tear trough eyelid deformity, and the appearance of prominent nasolabial folds.

Once the site of the subciliary incision has been marked, a skin only incision is made 3 mm below the eyelid margin

and carried 7 mm beyond the lateral canthal angle. Next, a skin only flap is elevated for approximately 8 mm inferiorly along the eyelid and lateral canthus. At the inferior edge of this elevation, an incision is made through the orbicularis oculi muscle lateral to the lateral canthus. This incision is

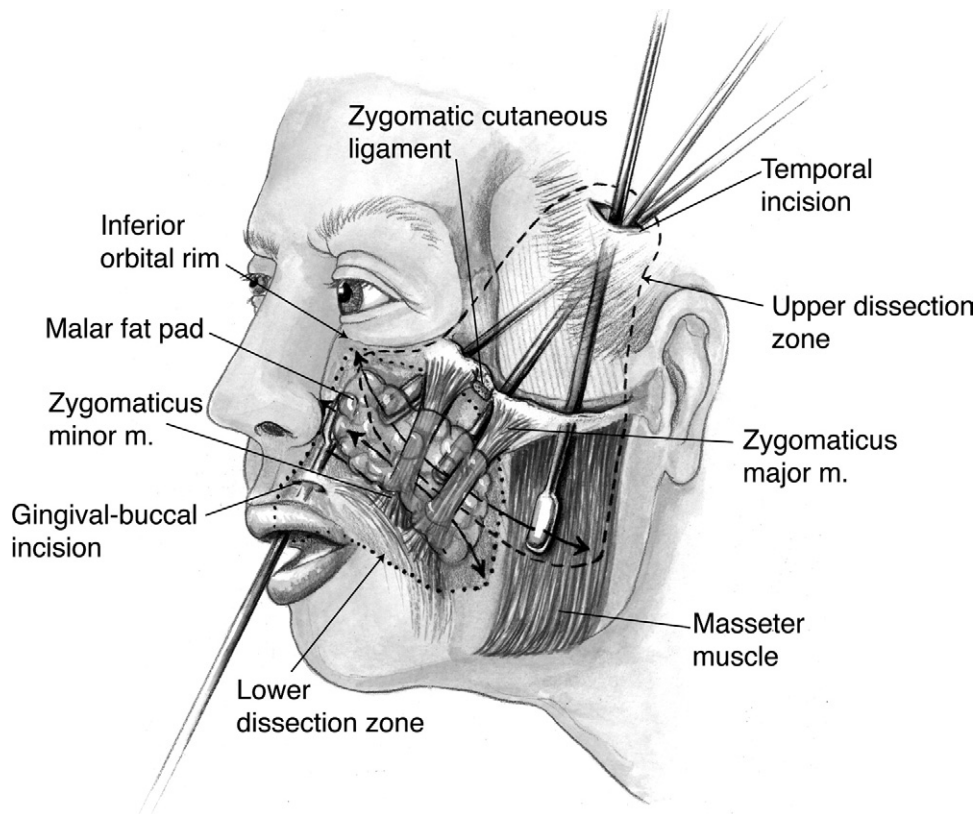


Figure 16 Zones of dissection through the temporal incision and gingival-buccal incision during the endoscopic midface lift.

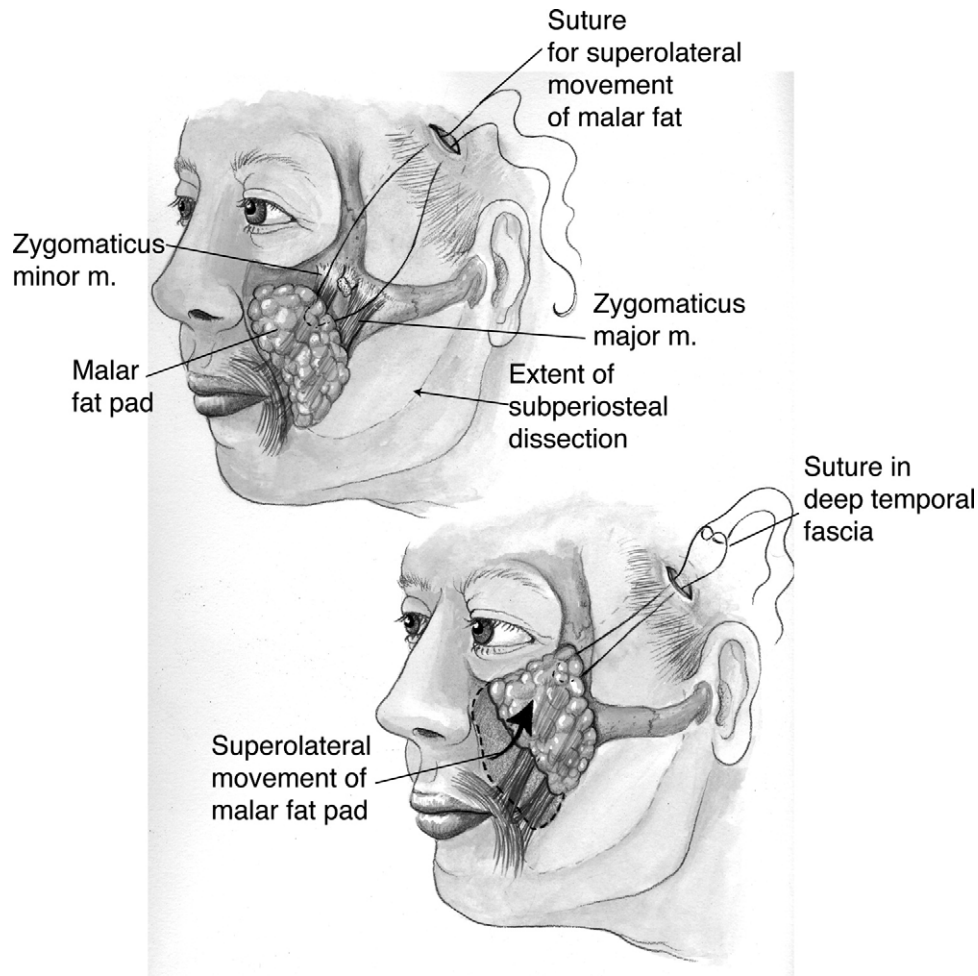


Figure 17 Endoscopic suturing of the malar fat pad to the temporalis to achieve a superolateral movement of the midface.

then carried medially along the inferior orbital rim. This stair-stepped incision allows for removal of skin without interruption of the orbicularis musculature. Once the arcus marginalis has been divided, a subperiosteal dissection of the midface can be performed (Figure 12). The dissection extends as far medially as the nasal bones and pyriform aperture, and continues along the zygoma to release the malar fat pad, along with the zygomatic muscles to the zygomatic arch which will ultimately release the zygomatic cutaneous ligament. Laterally, the dissection transitions from a subperiosteal plane deep to the zygomatic muscles to one that is superficial to the masseter muscle. Once the dissection is complete, the mobility of the midface is confirmed by pulling superiorly on the orbicularis oculi muscle at the lateral canthus. If any resistance remains, the dissection plane must be re-explored to determine where the tethering is occurring.

Once the midface is completely mobile, the orbital fat pseudoherniation is corrected by reattaching the arcus marginalis to the malar periosteum. Next, the malar fat pad is sutured to the temporalis fascia at the superior aspect of the lateral orbital rim, achieving a reduction of the nasolabial groove and anatomic repositioning of the malar fat pad (Figure 13). If the patient still suffers from laxity of the lower eyelid, a canthotomy and cantholysis can be performed to return the lateral canthus to a position that is

2 mm superior to the medial canthus. At this time, excess skin can be removed from the lower eyelid, and the incision closed in standard fashion.

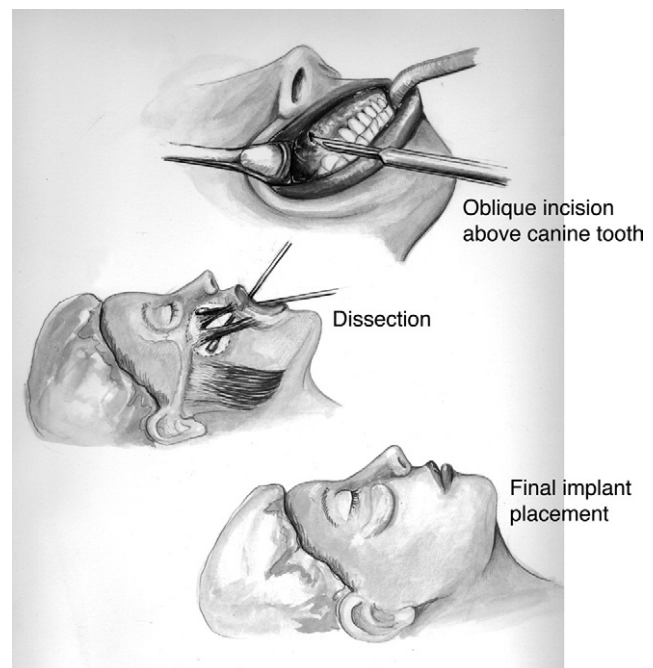


Figure 18 Malar implant through a gingival-buccal incision.

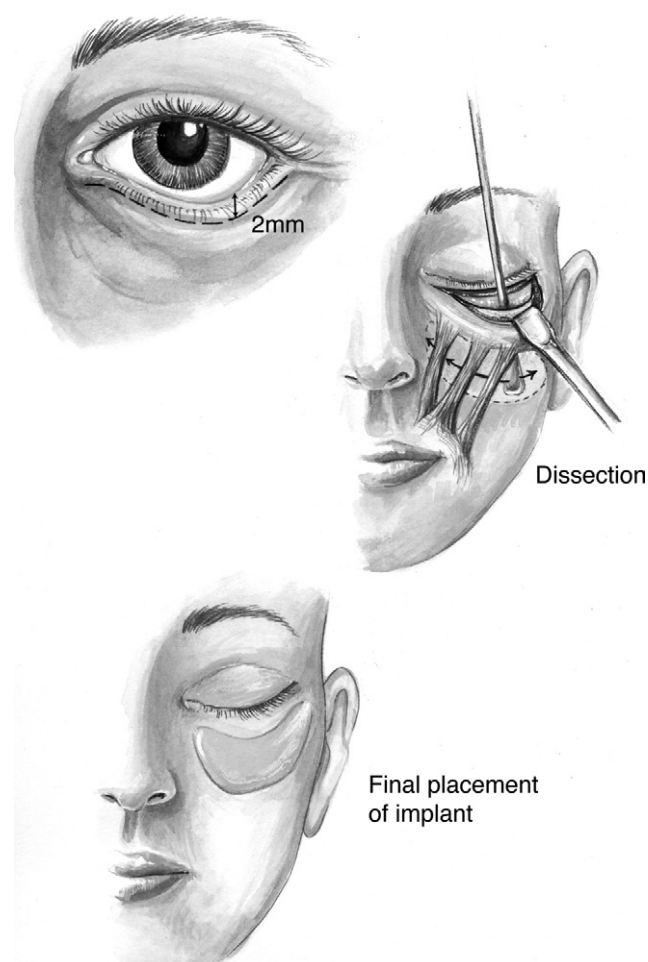


Figure 19 Malar implant through a subciliary incision.

Endoscopic approach to the midface

This technique involves a multiple anatomic plane approach to the midface. The temporal region will be elevated in a subtemporoparietal fascial approach, while a preperiosteal approach is used at the orbital rim, and finally, a subperiosteal approach is subsequently used at the zygomatic arch and zygomatic body. The purpose of the complex dissection is to ensure protection of the facial nerve.

Surgical markings for the temporal incision are first placed on the patient. First, a line is drawn from the base of the alar rim through the lateral limbus and into the hairline. This will be the superior limit of the temporal incision. A second mark is drawn from a point on the nasolabial fold, 2 cm below the alar base. This line is positioned perpendicular to the nasolabial fold, crosses the zygomatic eminence, and ends 1 cm posterior to the hairline over the temporalis muscle. These two points are connected by a 3- to 4-cm curvilinear line and define the temporal incision. The incision is not positioned further into the scalp to avoid transaction of the superficial temporal artery and to minimize the long trajectory of dissection needed to reach the midface. It is important to note that this procedure can be combined with an endoscopic procedure to address the brow, which is beyond the scope of this article.

A large, curved endoscopic dissector is used to take the incision down through the temporoparietal fascia, leaving the areolar tissue with the scalp flap. This allows one to

follow the true temporalis fascia to the superior orbital rim. At this point of the dissection, the temporalis fascia splits into the superficial and deep layers, and is separated by the superficial temporal fat pad (Figure 9). The superficial layer of the temporalis fascia is divided, and the undersurface is followed to the superior border of the zygomatic arch, which protects the facial nerve as it traverses over the zygomatic arch. It should also be noted that the dissection is superficial to the fat pad to prevent bleeding and possible temporal wasting.

The dissection then continues anteriorly to the lateral orbital rim, where the conjoint tendon is divided and the subsequent dense attachments between the orbicularis oculi muscle and the periosteum are released. These attachments at the lateral orbital rim constitute the superficial head of the lateral canthal tendon. The subsequent cephalad repositioning of these tissues will tighten the lower eyelid orbicularis oculi while increasing lateral canthal tendon support, and all the while, preserving the attachment of the deep head of the lateral canthal tendon.

Once the superior edge of the zygomatic arch is reached, the periosteum is incised, which allows access to the masseteric fascia (Figure 14). The subperiosteal dissection is extended from the mid-zygomatic arch to the junction of the zygomatic arch with the zygomatic body. The orbicularis oculi muscle is subsequently separated off the orbital rim in a preperiosteal plane.

Next, the zygomatic cutaneous ligament is released at the origin of the zygomatic major muscle, which subsequently mobilizes the malar fat pad. It is important to not injure the zygomatic branch of the facial nerve, as it travels inferior to the lateral cutaneous ligament to innervate the inferior portion of the orbicularis oculi muscle (Figure 15).

The dissection then continues to elevate the zygomatic major and minor muscles in a subperiosteal plane and transitioned to elevate the midface laterally, superficial to the masseter muscle. Once this dissection is completed, a 1 cm sublabial incision is made above the canine tooth and the medial aspect of the midface is elevated in a subperiosteal plane. The dissection releases the periosteum up the nasolabial sulcus to the pyriform aperture and continues up the lateral nasal sidewall up to the orbit, where the orbicularis oculi is released medial to the infraorbital nerve. Now, the entire midface, including the most medial aspects of the midface which are technically difficult to elevate through the temporal endoscopic technique are overcome by including the sublabial dissection (Figure 16).

Once the entire midface has been released from its attachments, a permanent suture is placed on the undersurface of the zygomatic cutaneous ligament and pulled in a superolateral vector where it is sutured to the deep temporal fascia (Figure 17). If adequate repositioning has not been accomplished, a second suture can be placed to advance the malar fat pad in a directly cephalad orientation to the junction of the lateral orbital rim and the temporalis fascia.

Alloplastic contouring of the midface

When a patient presents for consultation for midfacial rejuvenation, it is important to note which of these patients are suffering from a hypoplastic midface structure. In these

patients, a midface lift will not obtain the result either the surgeon or the patient was hoping to obtain without alloplastic augmentation.

The 2 techniques for inserting an implant in the middle third of the face are either through an intraoral or a subciliary incision. If an implant is to be used in combination with a midfacial rejuvenation procedure, the implantation method chosen should be based on which technique is to be used to address the midface.

The intraoral route is the original and most commonly chosen route of insertion. In this technique, a 1.5 cm oblique incision is initially made over the canine tooth and carried down to the maxilla. Next, a periosteal elevator is used to elevate a discrete pocket from the maxillary buttress up to the malar eminence. Once this pocket has been developed, the implant is introduced, and should remain immobile over the malar eminence (Figure 18). The intraoral incision is then closed in a standard two layer fashion. It is important to note that if there is any movement of the implant inferiorly toward the incision, the dissection needs to be extended, as the pocket is not large enough superiorly.

If a patient is undergoing a blepharoplasty procedure, the subciliary insertion method for midface rejuvenation is an excellent choice. A standard subciliary incision is initially made 3 mm below the lash line and a skin-muscle flap is raised. Next, a needle point electrocautery is used to penetrate the preseptal orbicularis oculi muscle, which leaves the pretarsal segment fully intact. The periosteum is then incised on the inferior orbital rim and an elevator is used to complete the subperosteal elevation along the malar body to the malar eminence. The implant is now ready to be inserted (Figure 19). Again, if there is any tendency for the implant to migrate toward the incision, the pocket must be enlarged to prevent extrusion.

References

1. Friedman O: Changes associated with the aging face. *Facial Plastic Surg Clin* 13:371-380, 2005
2. Fomon S: *The Surgery of Injury and Plastic Repair*. Baltimore, MD, Williams and Wilkins, 1939
3. Hollander E: *Cosmetic surgery*, in Joseph M (ed): *Handbuch der Kosmetik*. Leipzig, Verlag von Velt, 1912, p 688
4. Lexer E: *Die gesamte Wiederherstellung schiurgie*, vol 2. Leipzig, J.A. Barth, 1931, p 548
5. Passot R: *La chirurgie esthetique des rides du visage*. *Presse Med* 27:258, 1919
6. Joseph J: *Nasenplastic und sonstige Gesichtsplastik nebst einem Anhan uber Mamoplastik*. Leipzig: Verlag von Curt Kabitzsch, 1928-1931
7. Noel A: *La chirurgie esthetique*, in Noel A (ed): *Son Role Social*. Paris, Mason et Cie, 1926, pp 62-66
8. Miller CC: *The correction of featural imperfections*. Chicago, Oak Printing, 1907
9. Bourguet J: *La disparition chiurgicale des rides it plis du visage*. *Bull Acad Med (Paris)* 82:183, 1919
10. Bettman A: *Plastic and cosmetic surgery of the face*. *NW Med* 19:205, 1920
11. Adamson PA, Moran ML: Historical trends in surgery for the aging face. *Facial Plast Surg* 9:133-142, 1993
12. Skoog T: *Plastic surgery: New methods and refinements*. Philadelphia, W.B. Saunders, 1974
13. Mitz V, Peyronie M: The superficial musculoaponeurotic system (SMAS) in the parotid and cheek area. *Plast Reconstr Surg* 58:80-88, 1976
14. Hamra ST: The deep plane rhytidectomy. *Plast Reconstr Surg* 86:53-61, 1990
15. Hester TR, Codner MA, McCord CD, et al: Evolution of technique of the direct transblepharoplasty approach for the correction of lower lid and midfacial aging: Maximizing results and minimizing complications in a 5-year experience. *Plast Reconstr Surg* 105:393-406, 2000
16. Ramirez OM: Endoscopic full facelift. *Aesthetic Plast Surg* 18:363-71, 1994