

# Osteosarcomas of the Larynx

Raghu S. Athré, MD; Andrew Vories, MD; Steven Mudrovich, MD; Yadranko Ducic, MD, FRCS(C), FACS

**Objectives/Hypothesis:** The objective was to review the etiology, presentation, treatment, and prognosis in patients with osteosarcoma of the larynx using an illustrative case example. **Study Design:** Case report and literature review. **Methods:** A case is reported, and a review of all available published cases of osteosarcoma of the larynx is presented. **Results:** Osteosarcoma of the larynx may be a difficult clinical diagnosis. To be able to reach the correct diagnosis, a high index of suspicion and due diligence in obtaining deep biopsy specimens are important. Treatment is primarily surgical. Outcomes for this disease are generally poor, with most patients dying of the disease as a result of pulmonary metastasis. **Conclusion:** Osteosarcoma of the larynx is a rare entity, with only 14 cases reported to date. Pathological confirmation of osteoid is required for diagnosis. It is likely that aggressive surgical intervention directed at complete tumor extirpation is the treatment of choice, although long-term prognosis is poor. **Key Words:** Larynx cancer, osteoid, osteosarcoma.

*Laryngoscope*, 115:74–77, 2005

## INTRODUCTION

Sarcomas of the larynx<sup>1–10</sup> are relatively rare, non-epithelial derived neoplasms constituting only 0.32% to 2% of all laryngeal neoplasms, of which 50% are malignant.<sup>2</sup> Osteosarcoma represents the rarest of these soft tissue neoplasms. To date, only 13 cases of primary osteosarcoma of the larynx have been reported (Table I).<sup>1–4,6–9</sup> In the present study, we review this rare neoplasm with an illustrative case example.

## CASE REPORT

A 69-year-old Caucasian female with a history of smoking had been treated with partial resection followed by chemoradiation therapy for a supraglottic squamous cell carcinoma 4.5 years previously. During the past 3 years, she had had chronic aspiration and progressive dyspnea. Multiple biopsies at two outside

institutions were performed. The biopsy findings were negative for malignancy and were consistent with chondroradionecrosis. It was at this time that the patient presented to our institution.

Examination revealed the laryngeal framework to be larger than the normal. Fiberoptic laryngoscopy revealed diminished glottic opening attributable to cartilaginous overgrowth. Computed tomography (CT) scan demonstrated dystrophic calcification outside of the confines of the larynx (Fig. 1). As a result of these findings and the patient's progressive dyspnea, an elective tracheotomy was performed. Biopsies of the larynx revealed dystrophic calcification, but no frank evidence of malignancy. Because of a high clinical index of suspicion of chondrosarcoma, as well as the lack of functional value to her larynx from the standpoint of either respiration or phonation, consent was obtained for a total laryngectomy.

On dissection through the neck, the patient was found to have a firm mass involving the larynx, strap muscles, and thyroid gland with circumferential involvement of the esophagus. Intraoperative frozen-section specimens revealed osteosarcoma. The patient underwent total laryngectomy, total thyroidectomy, total pharyngectomy, and total esophagectomy with gastric pull-up. The patient's postoperative course was uneventful. However, the patient developed pulmonary metastases and died of disease 10 months later.

Final pathological findings revealed osteosarcoma of grade 4 (Fig. 2). Moderate calcification of neoplastic osteoid islands separated by large cells with irregular, hyperchromatic nuclei were observed. The tumor formed a band of closely spaced cells with large nuclei and scanty cytoplasm.

## DISCUSSION

Osteosarcoma of the larynx was first described in 1942.<sup>1</sup> Malignant sarcoma of the larynx is a rare entity, making up 0.5% to 1% of laryngeal neoplasms.<sup>2</sup> To date, 13 cases of osteosarcoma of the larynx have been described. Of these 13 cases, 12 cases were in men, and 1 of these cases presented following radiation therapy for other neoplasm.

To be classified as osteosarcoma, osteoid must be produced in the tumor.<sup>10</sup> Osteoid does not necessarily have to be calcified and may be noncalcified, lace-like, and trabecular in appearance. Production of osteoid is important in differentiating osteosarcoma from anaplastic chondrosarcoma.<sup>2</sup>

The most common presenting complaints in osteosarcoma of the larynx are hoarseness, dyspnea, and acute airway obstruction. In our review, we noted that the mean duration of symptoms was approximately 6 months before diagnosis.<sup>3</sup> Diagnosis is often made following multiple biopsies, because of the difficulty in obtaining a confirmatory specimen.

From the Department of Otolaryngology—Head and Neck Surgery (R.S.A., A.V., Y.D.), University of Texas Southwestern Medical Center, Dallas; the Division of Otolaryngology and Facial Plastic Surgery (R.S.A., A.V., Y.D.), John Peter Smith Hospital, Fort Worth; and the Department of Pathology (S.M.), Baylor All Saints Medical Center, Fort Worth, Texas, U.S.A.

Editor's Note: This Manuscript was accepted for publication May 26, 2004.

Send Correspondence to Yadranko Ducic, MD, FRCS(C), FACS, Director, Otolaryngology and Facial Plastic Surgery, John Peter Smith Hospital, 1500 South Main Street, Fort Worth, TX 76104, U.S.A.

DOI: 10.1097/01.mlg.0000150672.45484.5c

TABLE I.  
Summary of All Recorded Osteosarcoma Cases.

Case Number	Age (y)/Sex	Symptoms	Treatment	Outcome	Pathological Diagnosis
1	51/M	Dyspnea, hoarseness	Total laryngectomy	Recurrence at 3 mo, died at 6 mo with extensive mediastinal metastases	Osteosarcoma
2	51/M	Dyspnea, hoarseness	Total laryngectomy, XRT for local recurrence (no response)	Died at 14 mo; local recurrence in wound, bilaterally in neck, and in lungs	Fibrosteosarcoma*; previous diagnosis of osteochondrosarcoma
3	71/M	Hoarseness	Total laryngectomy	Alive and free of disease at 24 mo	Osteosarcoma; previous diagnosis on laryngoscopy of fibroma, papilloma, fibrosarcoma
4	62/M	Hoarseness, acute airway obstruction	Subtotal laryngectomy and XRT (4200 Gy) to stromal recurrence	Died at 3 mo with neck mass and cervical lymphadenopathy	Osteosarcoma
5	79/M	Chronic hoarseness, acute airway obstruction	Total laryngectomy	Died at 3 mo with multiple pulmonary metastases	Osteosarcoma; previous diagnosis of pyogenic granuloma
6	66/M	Progressive hoarseness, stridor	Total laryngectomy with thyroidectomy	Died at 20 mo with pulmonary metastases	Chondroblastic osteosarcoma; frozen-section diagnosis of chondrosarcoma
7	75/M	Hoarseness	Total laryngectomy with radical neck dissection	Died at 14 mo with regional and distant disease	Osteosarcoma
8	67/M	Hoarseness, dyspnea	XRT (6700 Gy) to right and left sides of neck	Died at 6 mo	Osteosarcoma
9	65/M	Hoarseness, dyspnea	XRT (4500 Gy); after 1 y, 4000 Gy for recurrence	Recurrence at 1 y	Chondroblastic osteosarcoma
10	56/M	XRT 3 y earlier for SCCA of larynx	Not available	Not available	Osteosarcoma
11	75/M	Mild dysphagia, odynophagia	Total laryngectomy, postoperative chemotherapy (cisplatin, doxorubicin); radiation therapy for soft tissue recurrence in neck	Recurrence in soft tissue of neck 13 mo later	Osteosarcoma; previous diagnosis of chondroma
12	65/M	Progressive dyspnea	Thyrotomy with tumor resection, tracheostomy, XRT (60 Gy over 6-wk period)	Recurrence at 1 mo, skin nodule resection and pectoralis flap; free of disease at 60 mo	Osteosarcoma
13	60/F	Odynophagia radiating to right ear, globus	Total laryngectomy	Free of disease at 44 mo	Osteosarcoma
14	69/F	Progressive dyspnea, XRT for previous SCCA of larynx	Total laryngectomy, thyroidectomy, total pharyngectomy, esophagectomy	Free of disease at 4 mo	Osteosarcoma

\*Histopathologic characteristics not available.  
XRT = radiation therapy; SCCA = squamous cell carcinoma.

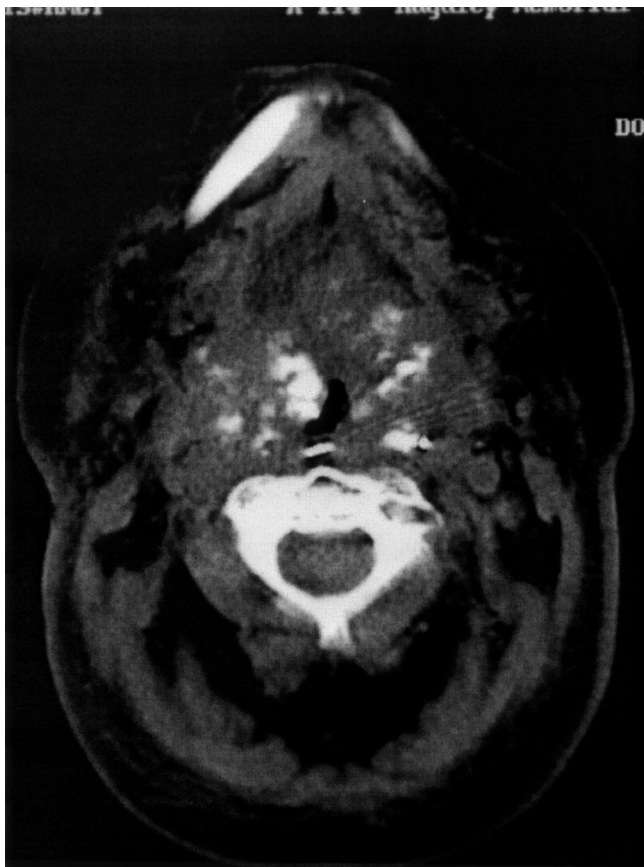


Fig. 1. Axial computed tomography scan demonstrating dystrophic calcification associated with a soft tissue mass of the endolarynx.

Treatment of osteosarcoma falls under three modalities: surgery, radiation therapy, and chemotherapy. Because of the rarity of this malignancy, no series has been able to show a dramatic improvement in survival attributable to the use of one particular therapy regimen. Most patients died soon after their initial diagnosis, mostly of pulmonary metastasis or local/regional recurrence. Two of

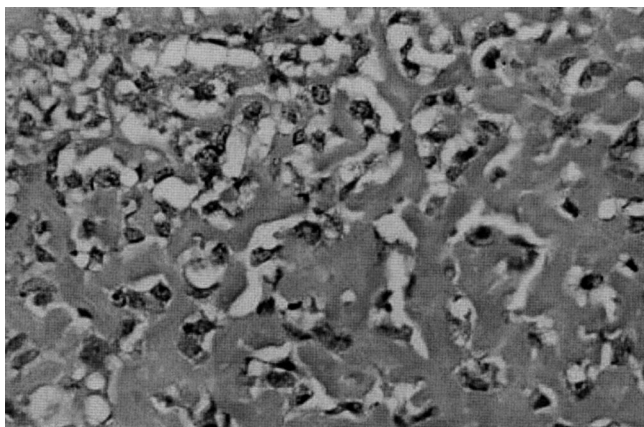


Fig. 2. Neoplastic osteoids between which are cells with large, irregular hyperchromatic nuclei (H&E stain, original magnification  $\times 40$ ).

the previous 13 patients were treated with primary radiation therapy. The first patient died within 6 months, and the second patient died within 12 months. Six patients were treated with surgery alone. All six patients underwent total laryngectomy. Only one patient was free of disease and alive at 36 months after diagnosis. The only other case report having a greater disease-free interval (5 y) was of a 65-year-old man who underwent thyrotomy with tumor resection, tracheostomy, and postoperative radiation therapy for a much more localized lesion.

The Cooperative Osteosarcoma Study (COSS) group<sup>10</sup> attempted to study the role of various chemotherapeutic regimens on the long-term survival and disease-free interval in patients with skeletal osteosarcoma. Because skeletal osteosarcoma is far more common, much more information is available regarding outcome studies. The COSS group<sup>10</sup> found no firm data from controlled studies comparing adjuvant versus neoadjuvant chemotherapy. The regimen recommended by the COSS group includes methotrexate, doxorubicin, and cisplatin.<sup>10</sup>

The differential diagnosis for osteosarcoma includes other mesenchymal tumors. Fibrosarcoma is the primary entity from which osteosarcoma must be differentiated. Fibrosarcoma is the most common mesenchymal malignancy of the larynx, differing from osteosarcoma in that it has fibroblasts with production of collagen fibrils and without production of osteoid. Pseudosarcoma can also mimic osteosarcoma.<sup>3</sup> Pseudosarcoma is a usually benign response to an epithelial-derived primary malignancy with bizarre, sarcomatous, stromal tissue. Malignant fibrous histiocytoma can exhibit chondroid and osteoid elements. However, usually, these elements are only in the periphery of the lesion and exhibit a high degree of differentiation. Furthermore, malignant fibrous histiocytoma exhibits xanthoma cells.

Often, the origin of osteosarcoma of the larynx is not known. Fifty percent of chondrosarcomas of the skeleton that dedifferentiate turn into osteosarcoma, whereas the remaining 50% differentiate into malignant fibrous histiocytoma.<sup>9</sup> Hence, osteosarcoma of the larynx may represent a dedifferentiation process. Radiation-induced sarcoma may also be seen. Laskin et al.<sup>5</sup> reported that 12% of radiation-induced tumors were sarcomas. They analyzed 53 cases of postradiation sarcomas, of which 68% were malignant fibrous histiocytoma and 12% were osteosarcoma.<sup>5</sup> Of the seven cases of extraskeletal osteosarcoma, one was in the larynx, two were on the face, and one was in the right side of the neck. Our case may represent a postradiation-induced primary sarcoma.

## CONCLUSION

We have presented a case of primary osteosarcoma of the larynx in a 69-year-old female who had previously received irradiation for squamous cell carcinoma of the larynx. Despite the dismal outcomes in the majority of patients, surgery appears to represent the treatment of choice. Most patients die of the disease within months of diagnosis, most often as a result of pulmonary metastases.

## BIBLIOGRAPHY

1. Berge JK, Kapadia SB, Myers EN. Osteosarcoma of the larynx. *Arch Otolaryngol Head Neck Surg* 1998;124:207-210.

2. Dahm LJ, Schaefer SD, Carder HM, Vellios F. Osteosarcoma of the soft tissue of the larynx: report of a case with light and electron microscopic studies. *Cancer* 1978;42: 2343–2351.
3. Gorenstein A, Neel HB, Weiland LH, Devine KD. Sarcomas of the larynx. *Arch Otolaryngol* 1980;106:8–12.
4. Haar JG, Chaudhry AP, Karankia MD, Milley PS. Chondroblastic osteosarcoma of the larynx. *Arch Otolaryngol* 1978; 104:477–481.
5. Laskin WB, Silverman TB, Enzinger FM. Postradiation soft tissue sarcomas: an analysis of 53 cases. *Cancer* 1988;62: 2330–2340.
6. Morley AR, Cameron DS, Watson AJ. Osteosarcoma of the larynx. *J Laryngol Otol* 1973;87:997–1005.
7. Shimizu KT, Selch MT, Fu YS, Anzai Y, Lufkin RB. Osteosarcoma metastatic to the larynx. *Ann Otol Rhinol Laryngol* 1994;103:160–163.
8. Sprinkle PM, Allen MS, Brookshire PF. Osteosarcoma of the larynx: a true primary sarcoma of the larynx. *Laryngoscope* 1966;325–333.
9. Van Laer CG, Helliwell TR, Atkinson MWA, Stell PM. Osteosarcoma of the larynx. *Ann Otol Rhinol Laryngol* 1989;98: 971–974.
10. Winkler K, Bielack SS, Delling G, Jurgens H, Kotz R, Salzer-Kuntschik M. Treatment of osteosarcoma: experience of the cooperative osteosarcoma study group (COSS). In: *Osteosarcoma in Adolescents and Young Adults*. Boston: Kluwer Academic, 1993.