

Postoperative Meleney's Ulcer

Yadranko Ducic, MD, FRCSC,
Paul Odell, MD, FRCSC, and Martin Corsten, MD, FRCSC

Meleney's ulcer, or progressive synergistic gangrene, was first accurately characterized by Meleney in 1924 as representing a polymicrobial infection in which microaerophilic streptococci flourished with *Staphylococcus aureus*.¹ Meleney demonstrated this synergy by noting the formation of the typical gangrenous lesion when both of the aforementioned organisms were injected into the skin of dogs.² Neither organism was capable of forming such a lesion when injected alone. Meleney's ulcer usually begins as a small, superficial ulcer following trauma or surgery (most often abdominal surgery).³ It may also arise from infected lymph nodes. Meleney's ulcer primarily represents an infection of the subcutaneous tissue leading to small-vessel thrombosis followed by subcutaneous necrosis.⁴ The unique synergistic reaction between the microaerophilic and aerobic organisms is most apt to occur at the advancing edge of the ulcer. However, it is important to note that the extent of the underlying process is uniformly much greater than is evidenced by changes in the overlying skin. Generally, the lesion slowly progresses over a period of months or even years, with a gradual enlargement of the visible ulcer. If left untreated, or undertreated, the ulcer can attain enormous proportions.

In this article, we present an illustrative case of Meleney's ulcer following total laryngectomy.

Case Report

A 43-year-old insulin-dependent diabetic male smoker presented to our service with a T4N0M0 squamous cell carcinoma of the larynx. Planned combined therapy

consisted of total laryngectomy and a full course of external-beam radiotherapy. One month after the completion of therapy, a small amount of drainage was noted at the stoma, for which the patient was placed on oral antibiotics (clindamycin). This limited drainage continued until the time of the patient's definitive procedure 6 months later. During this period, the patient was evaluated and followed by our infectious disease service, who placed him on ciprofloxacin, cloxacillin, and metronidazole in combination. Associated with the drainage was clinically evident ulceration of the stoma. The subcutaneous tissue at the margin of the ulcer was firm and indurated. However, there was no visible cutaneous gangrene present. As the area of subcutaneous induration increased, the overlying skin would just melt away (Fig. 1). The edges of the undermined skin were noted to roll inward, as is typically seen with Meleney's ulcer (Fig. 2). We performed three separate

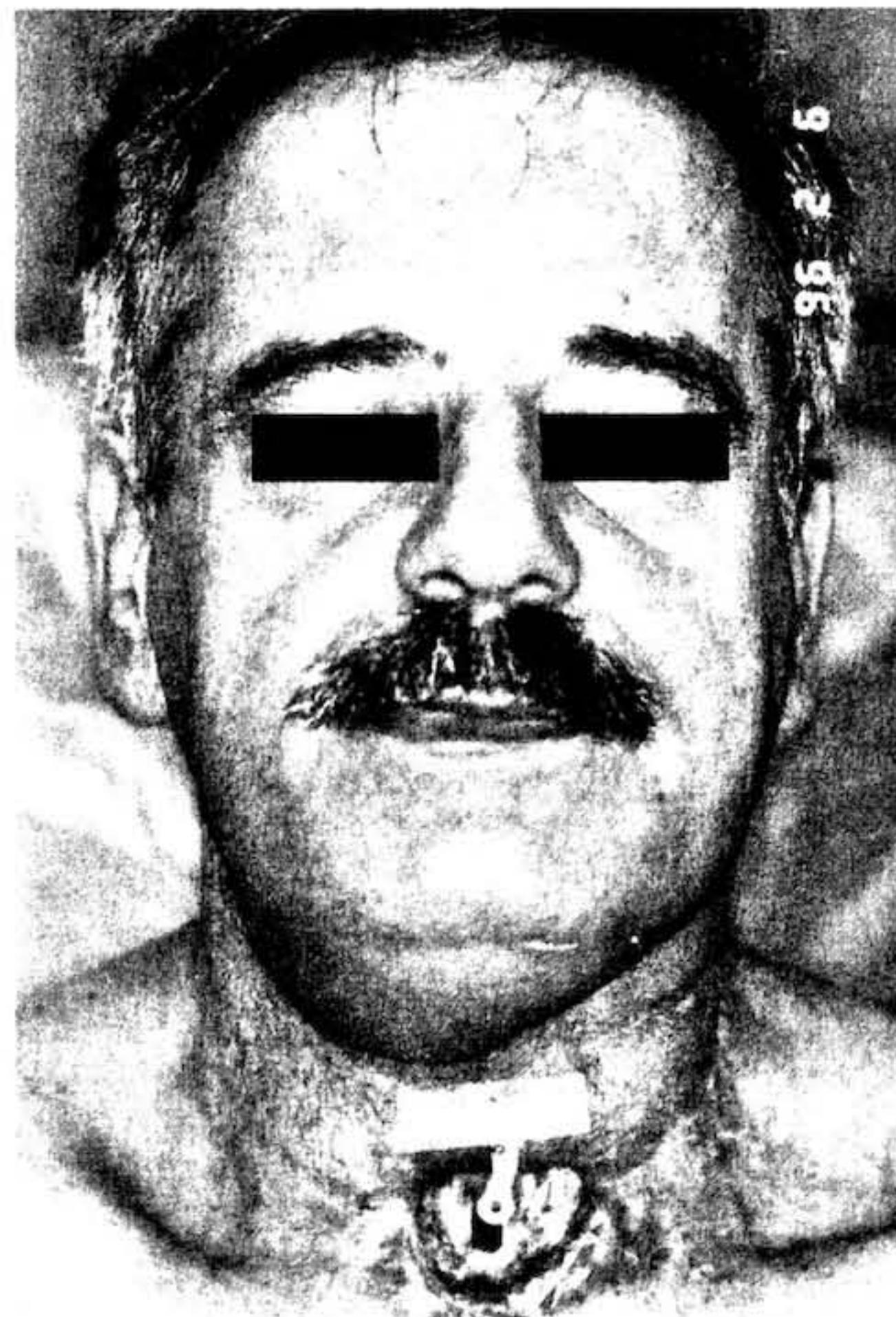


Figure 1 Patient with Meleney's ulcer of laryngectomy stoma. Note the loss of the full thickness of skin at this site.

Received 7/30/97. Received revised 11/17/97. Accepted for publication 11/17/97.

Yadranko Ducic: Department of Otolaryngology, University of Texas, Southwest Medical Center, Dallas, Texas, and Division of Otolaryngology and Facial Plastic Surgery, John Peter Smith Hospital, Fort Worth, Texas; *Paul Odell* and *Martin Corsten*: Department of Otolaryngology—Head and Neck Surgery, University of Ottawa, Ottawa, Ontario.

Address reprint requests to: *Dr. Yadranko Ducic*, Director, Division of Otolaryngology and Facial Plastic Surgery, John Peter Smith Hospital Network, 1500 Main Street, Fort Worth, TX.

generous wedge biopsies of the margins of the ulcer over a 6-month period. All were negative for any signs of malignant or premalignant changes. A large number of tissue cultures and Gram stains were obtained, revealing the presence of various gram-positive species, including streptococci and staphylococci.

After failure of both oral and intravenous antibiotics to control the relentless increase in the size of the ulcer, we decided that operative intervention was warranted. Throughout this period, the patient's diabetes had been difficult to control, likely as a result of his underlying condition. At the time of resection, the patient's symptoms were not prominent. He experienced a dull aching pain at the edges of the stomal ulcer, and relative anaesthesia in the ulcer's centre. Computerized tomographic (CT) scanning of the neck and upper mediastinum revealed edema and subcutaneous air in the peristomal region, with extension of the underlying process to the area adjacent to the sternoclavicular joints. We undertook a wide local resection of peristomal tissue, with the extent of removal dictated by intraoperative findings. We noted that the tissues well beyond the apparent edges of the ulcer were involved. Tissue planes and fascial coverings were not respected by this patient's Meleney's ulcer. The indurated area had poor blood supply, as evidenced by the lack of bleeding at the cut tissue edges. Resection of the involved tissue necessitated removal of the peristomal area to include the upper trachea, medial aspects of both clavicles, and the upper sternum. The esophagus appeared to be intact grossly and endoscopically. The mediastinal tracheotomy was separated from the great vessels of the upper mediastinum with a generous pedicled omental flap. The defect was covered with a well-vascularized pectoralis major flap (Fig. 3).

Postoperatively, despite aggressive intravenous antibiotics, we noted the apparent persistence of Meleney's

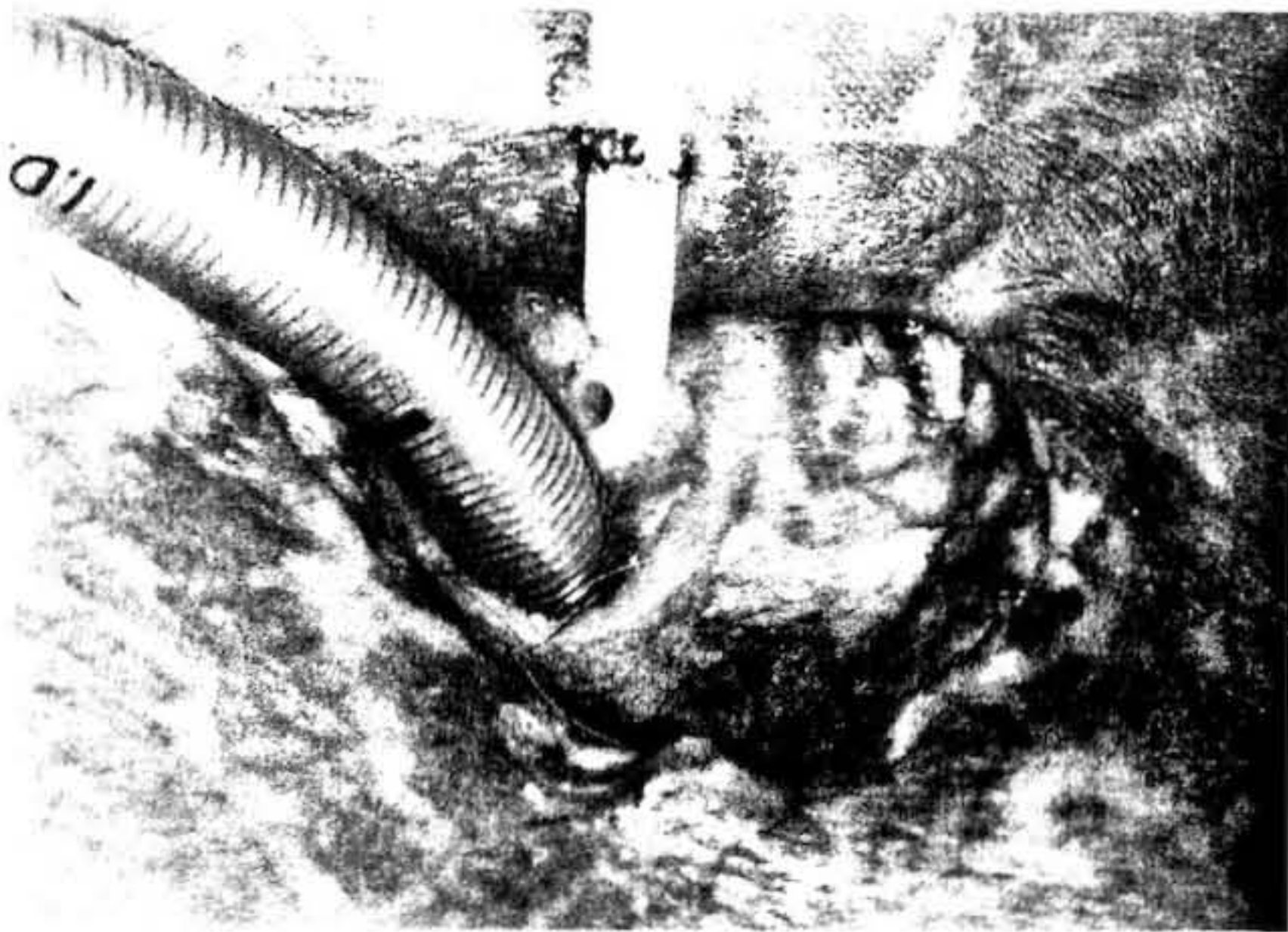


Figure 2 Magnified view of stoma. Note the undermining of the edges of the ulcer by the active leading edge of the infectious process.

ulcer evidenced by progressive ulcerative loss of the right side of the pectoralis major flap. A clearly visible line of progressive demarcation was noted. Repeated early aggressive debridement at the bedside eventually halted the process. The debrided area was left to form a bed of healthy-appearing granulation tissue, which was subsequently skin grafted 1 month later. Now 1.5 years since the resection, the patient remains asymptomatic and free of disease. Interestingly, once the infectious process was completely controlled, the patient's diabetes was much more amenable to treatment.

Discussion

This presentation is the first reported case of Meleney's ulcer following laryngectomy. It illustrates the typical presentation and extent of treatment required to bring this aggressive disease under control.

On average, 50% of patients with Meleney's ulcer will have underlying diabetes, and an additional 30% will have pre-existing compromised renal function.⁵⁻⁷ The resulting ischemic small-vessel disease and the relative decrease in the ability to mount a powerful immunologic response to infection characterize both of these conditions. Significant obesity, cardiovascular disease, advanced malignancy, and nutritional deficiencies are frequently noted concomitant problems. The majority of all subtypes of necrotizing fasciitis, including Meleney's ulcer, occurring in both the neck and other anatomic settings, will have arisen after surgery and/or trauma.^{3,8} As we have noted, the extent of the infection is much greater than is suggested by changes in the overlying skin. If untreated or undertreated, the relentless increase in ulcer size can lead to significant morbidity and mortality as a result of necrosis of the anatomically sensitive region of the neck.³ Typically, the ulcer is only mildly painful, and any systemic reaction is generally minimal. As the skin edge is undermined by underlying subcutaneous tissue thrombosis and necrosis, it will tend to roll inward.^{9,10} Microaerophilic streptococci and staphylococci can often be cultured from the advancing edge of the ulcer, as the microaerophilic environment within the newly thrombosed microvasculature provides the optimal environment to promote the synergism between these two species.² However, the clinically apparent edge of the ulcer often corresponds poorly with the actual margin, so accurate cultures may not always be easy to obtain.

There is generally no immediate urgency for operative intervention in the treatment of Meleney's ulcer. The patient's underlying medical condition (diabetes, renal failure, etc.) should be maximally managed. Broad-spectrum antibiotics should be administered to provide coverage for staphylococci, streptococci, and enterococci, such as *Proteus*. Anaerobes are notoriously difficult to culture, but likely also play some role in the

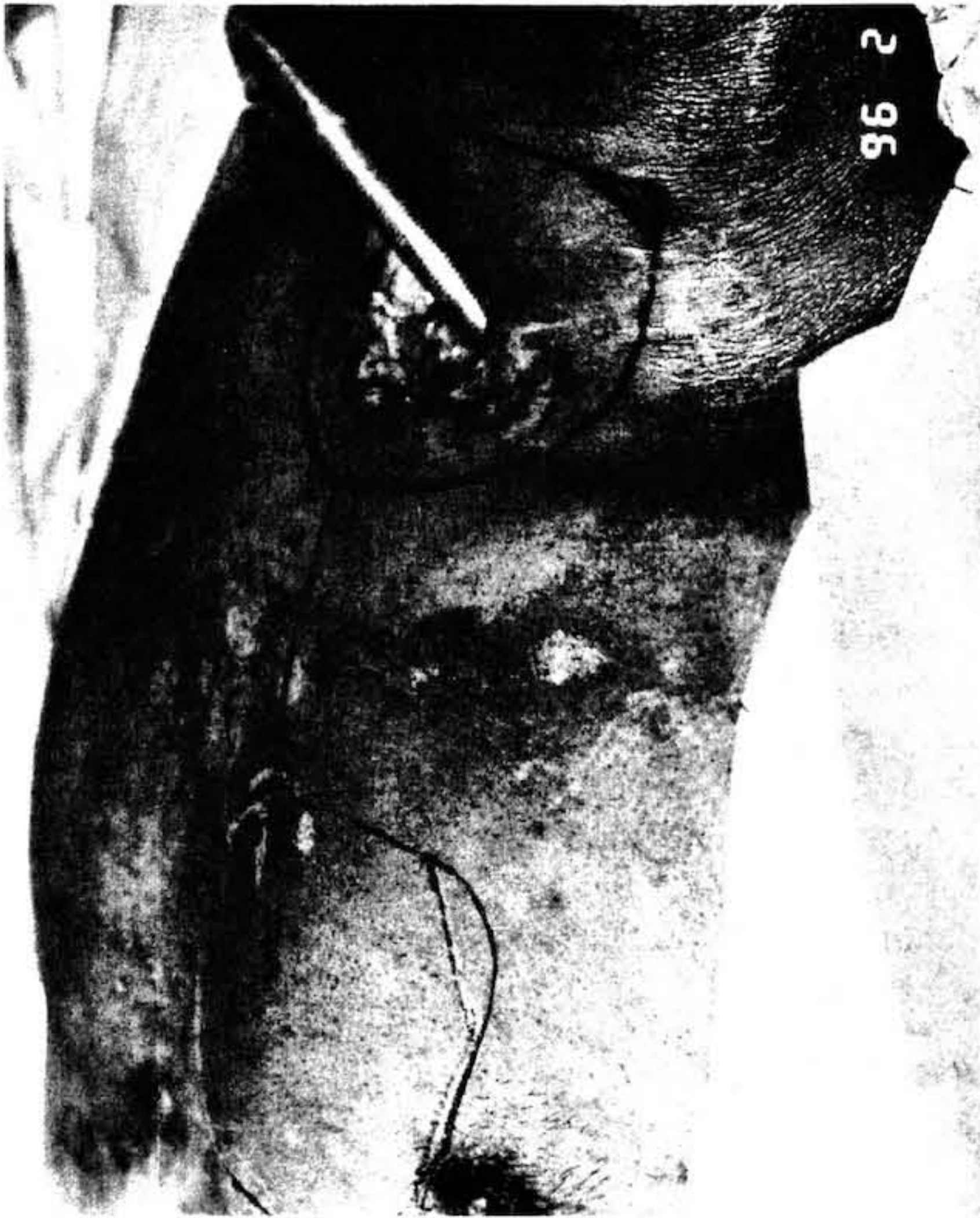


Figure 3 Intraoperative resection outline. The actual resection was extended slightly beyond these planned limits based on intraoperative findings of necrotic tissue.

development of this infection.⁴ Thus, metronidazole, ciprofloxacin and cloxacillin in combination appears to be a reasonable choice, providing gram-positive and negative, and anaerobic coverage. Hyperbaric oxygen therapy may hold some promise in the ancillary treatment of Meleney's ulcer; however, this is as yet unproven.¹¹

The cornerstone of treatment remains surgical resection of the ulcer and any associated fistulous tracts that may be present. The excision should encompass the entire ulcer as well as apparently normal skin in the adjacent areas. Excision should continue until good vascularity (as evidenced by intraoperative bleeding) of the subcutaneous tissue has been assured.^{1,12} Preoperative planning should take into account the possibility of reconstructing a much larger defect than suggested by preoperative imaging or clinical examination. Due to the exposure of the great vessels at the base of the neck, we chose to utilize well-vascularized tissue to fill our defect, as well as to protect vital exposed structures. However, as we noted, even well-vascularized

tissue that had been outside of the irradiation field was still susceptible to this infection. Early aggressive debridement is the treatment that is most likely to eradicate the infection with minimal tissue loss.

Conclusion

Meleney's ulcer is a slowly progressive, aggressive condition arising as a result of a synergistic relationship between microaerophilic and aerobic organisms at the wound margins, leading to unrelenting ulcer enlargement. The treatment of choice continues to remain as originally espoused by Meleney¹: that is, aggressive surgical resection. Coverage with broad-spectrum antibiotics is also recommended.

References

1. Meleney FL. Hemolytic streptococcus gangrene. *Arch Surg* 1924; 9:317.
2. Meleney FL. Bacterial synergism in disease processes with a confirmation of the synergistic bacterial etiology of a certain type of progressive gangrene of the abdominal wall. *Ann Surg* 1926; 94:961.
3. Krespi YP, Lawson W, Blaugrund SM, Biller HF. Massive necrotizing infections of the neck. *Head Neck Surg* 1981; 3: 475-481.
4. Beck HJ, Salassa JR, McCaffrey TV, Hermans PE. Life threatening soft tissue infections of the neck. *Laryngoscope* 1984; 94:354-362.
5. Freeman HP, Oluwole SF, Ganepola GAP, Dy E. Necrotizing fasciitis. *Am J Surg* 1981; 142:377-383.
6. Gozal D, Ziser A, Shupak A. Necrotizing fasciitis. *Arch Surg* 1986; 121; 233-235.
7. Rouse TM, Malangoni MA, Schulte WJ. Necrotizing fasciitis: a preventable disaster. *Surgery* 1982; 92:765-770.
8. Feingold DC. The diagnosis and treatment of gangrenous and crepitant cellulitis. In: *Current clinical topics in infectious diseases*. New York: McGraw-Hill, 1981:259-277.
9. Grainger RW. Progressive bacterial synergistic gangrene: chronic undermining ulcer of Meleney. *Can J Surg* 1967; 10:656.
10. Daly JW, King CR, Monif GR. Progressive necrotizing wound infections in postirradiated patients. *Obstet Gynecol* 1978; 52:5-8.
11. Grim PS, Gottlieb LJ, Boddie A, Batson E. Hyperbaric oxygen therapy. *JAMA* 1990; 263:2216-2220.
12. Ahrenholz DH. Necrotizing soft tissue infections. *Surg Clin North Am* 1988; 68:199