

# *Reconstruction of the upper eyelid with a pedicled bucket-handle brow flap*

## **A case report**

Yadranko Ducic MD, FRCS(C)<sup>1</sup>, Todd A. Schock DDS, MD<sup>2</sup> and Jeffrey S. Dean DDS, MD<sup>2</sup>  
*Departments of <sup>1</sup>Otolaryngology and <sup>2</sup>Oral and Maxillofacial Surgery, University of Texas SouthWestern Medical Center, Dallas; and <sup>1</sup>Division of Otolaryngology and Facial Plastic Surgery, John Peter Smith Hospital, Fort Worth; TX, USA*

## **Summary**

Restitution of form following traumatic avulsive upper eyelid loss may be accomplished with any of a number of diverse reconstructive options. These options include primary closure, free skin grafts or, a variety of local pedicled flaps. In this brief article, the authors present their positive experience utilizing a pedicled bucket-handle brow flap for reconstruction of an upper eyelid defect.

## **Preliminary discussion**

In addition to having obvious functional significance in terms of globe protection, the eyelids constitute an important aesthetic highlight of the face. Absence of the upper eyelid may result in corneal ulceration, scarring, and the likelihood of blindness. Often, even partial avulsion of the upper eyelid, if untreated or inadequately treated, will result in fibrotic superiorly directed lid traction, with consequent corneal exposure. This a surgically challenging problem that is significantly more difficult to correct secondarily. Thus, early surgical correction is advised.

Techniques for upper eyelid reconstruction may variably include direct closure (small defects that may be closed primarily without causing any significant lid retraction), split thickness grafts (skin only defects that are ideally reconstructed with the use of contralateral upper eyelid skin, if available), and a variety of local flaps

(Tenzel flap, sliding tarsal flap, pedicle from lower lid, forehead flap, Cutler-Beard flap)<sup>1-5</sup>.

In this article, we will present our positive experience with the use of a pedicled bucket-handle flap brow flap for reconstruction of a full thickness upper eyelid-infrabrow defect arising as a consequence of traumatic avulsive loss.

## **Case report**

Patient HL was referred to the Otolaryngology and Facial Plastic Surgery service for evaluation and treatment of an avulsive upper lid defect. The patient is a 35-year-old male who attempted to commit suicide by driving his motor vehicle at high speed into a concrete embankment. He managed to inflict serious multisystem trauma on himself, suffering a closed head injury, intestinal disruption, bilateral hemothoraces, splenic laceration, pelvic and four limb fractures.



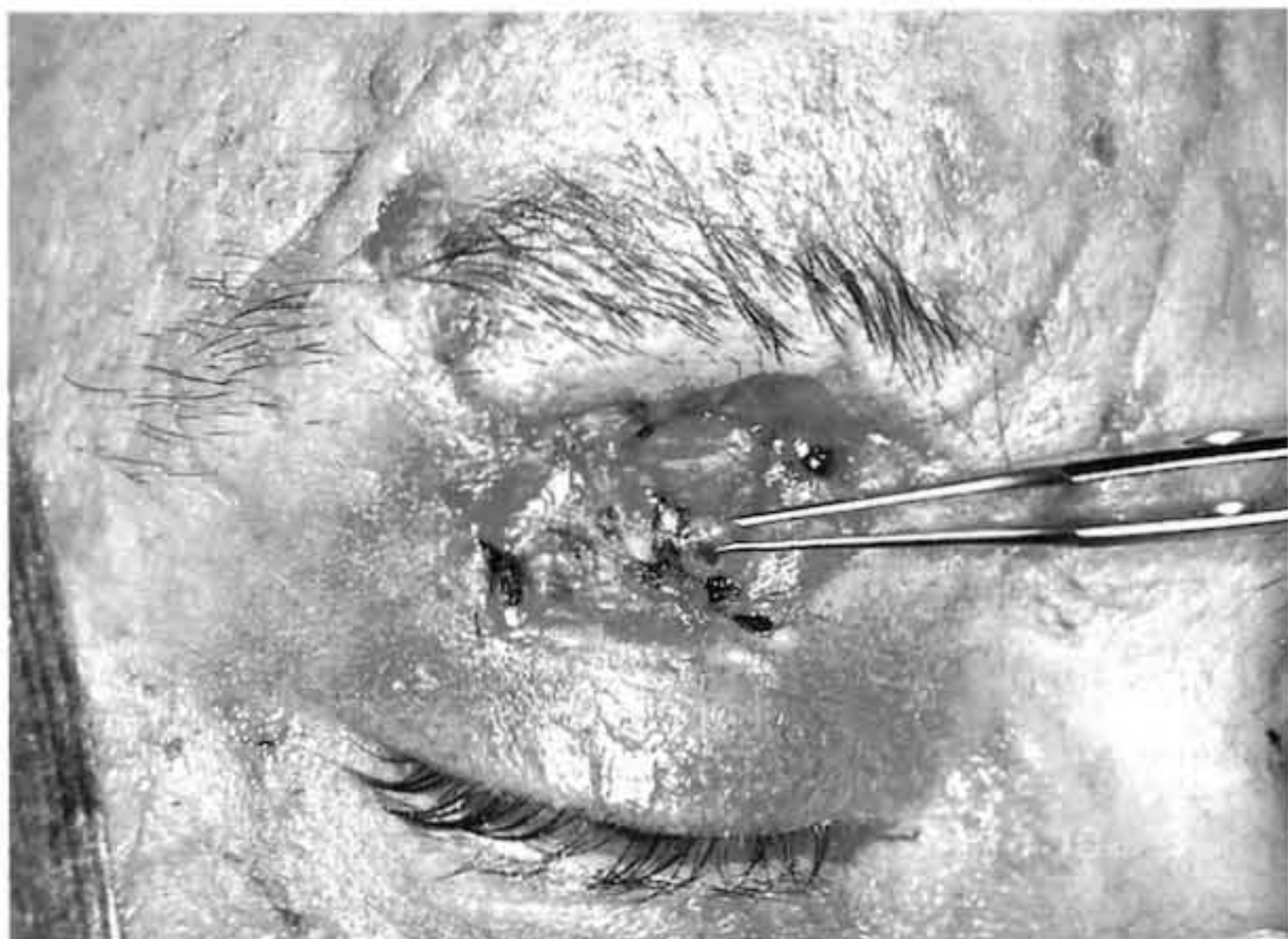

Fig. 1. Full thickness upper eyelid defect. Forceps demonstrating osseous exposure of the superior orbital rim.

After initial emergent treatment of his serious life-threatening injuries, the patient developed adult respiratory distress syndrome and a persistent intestinal fistula. Renal and hepatic function also adversely affected this patient.

It is against this background that our service was asked to evaluate his upper eyelid defect. In fact, the patient had avulsed a  $3 \times 2$  cm full thickness area of his right upper eyelid, extending from the immediate infrabrow area and crossing the supratarsal crease. There was osseous exposure of the superior orbital rim (Fig. 1). The patient also had a number of superficial abrasions in the right supraorbital area, both medially and laterally.

We entertained a number of possibilities for reconstruction. We felt that his healing potential was quite poor due to the severity of his overall condition. Thus, we designed a local, pedicled flap which we felt was simple and expeditious to raise and inset, and, which we felt, maximized the potential vascularity of the transferred tissue. A bucket handle bipedicled flap of suprabrow skin was transferred onto the upper eyelid defect after conservative debridement and thorough irrigation of the tissues with copious amounts of sterile water solution. The inferior limb of the incision was made along the margin of the superior brow, bevel cutting it to avoid unnecessary trauma to the hair follicles (Fig. 2). The superior limb of the incision was made parallel and 1.5 cm superior to the inferior incision. The medial and lateral ends of the

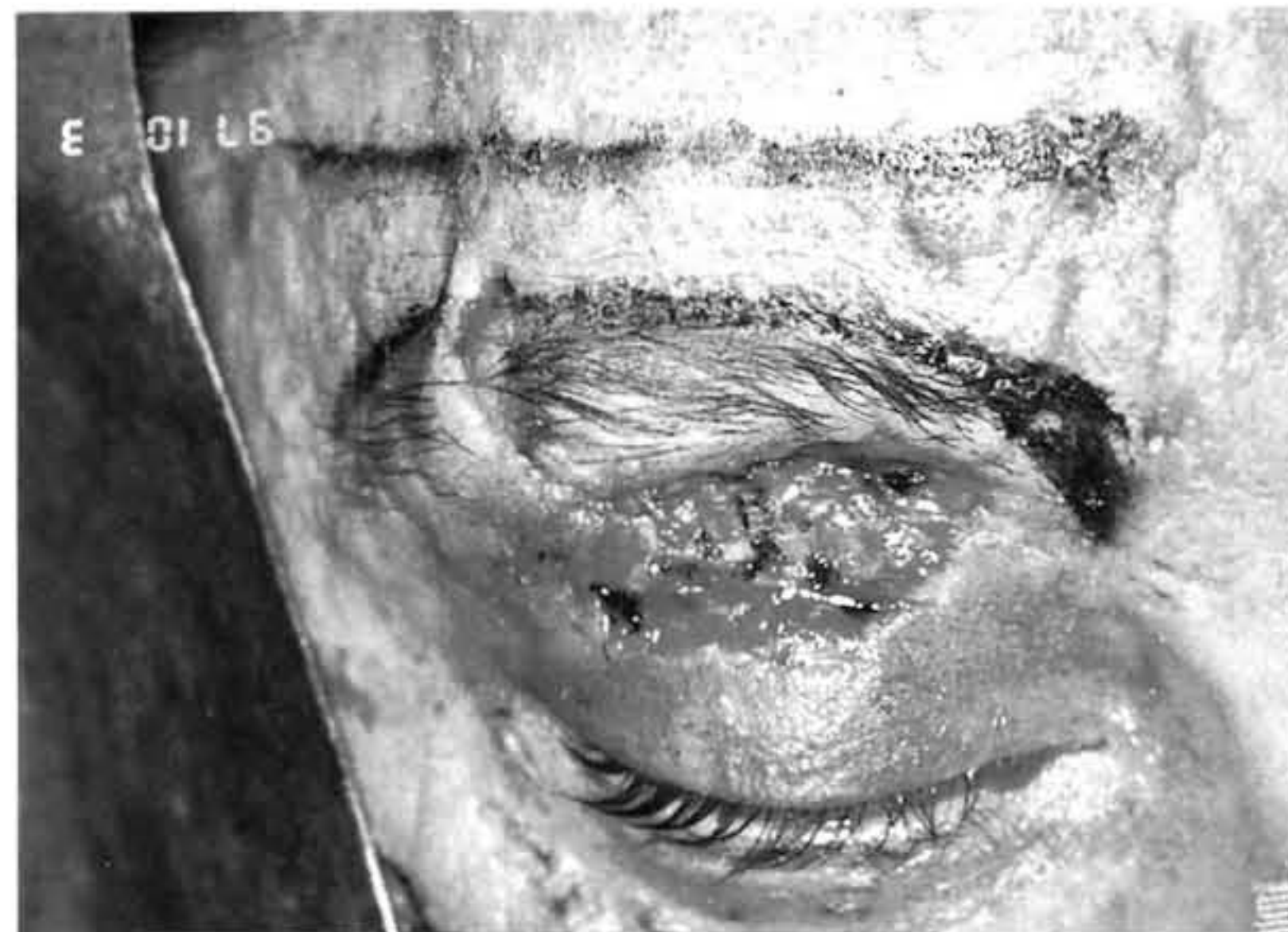


Fig. 2. Proposed outline of pedicled bucket handle brow flap. Note flaring medially and laterally.

flap were flared slightly in an effort to maximize the blood supply at each end of the flap. The flap was raised in a subcutaneous plane of dissection until it was mobile enough to allow for tension-free inset into the eyelid defect (Fig. 3). The transected orbicularis fibers and levator were reattached and the flap inset into the defect with a series of absorbable and non-absorbable sutures (Fig. 4). Two and a half weeks later, the pedicles were divided and the flap insetting completed (Fig. 5). Despite tremendous hemodynamic instability, and the multisystem disease previously outlined, flap vascularity remained complete throughout and flap survival was 100%. Unfortunately, the patient was not able to overcome his multiorgan failure, and passed away.

## Discussion

As far as we are aware, in this brief communication, we have outlined a previously unreported method of upper eyelid repair after traumatic loss. We found the pedicled bucket handle brow flap was simple to design, raise and inset. Its reliability likely arises from vascular contributions of the superficial temporal artery through the lateral pedicle, and the supratrochlear artery through the medial pedicle. The ability of this patient to heal a simple skin graft adequately was reasonably in question as a result of his injuries. Thus, we felt a pedicled flap was mandatory. As a consequence of the significant number of superficial abrasions extending across



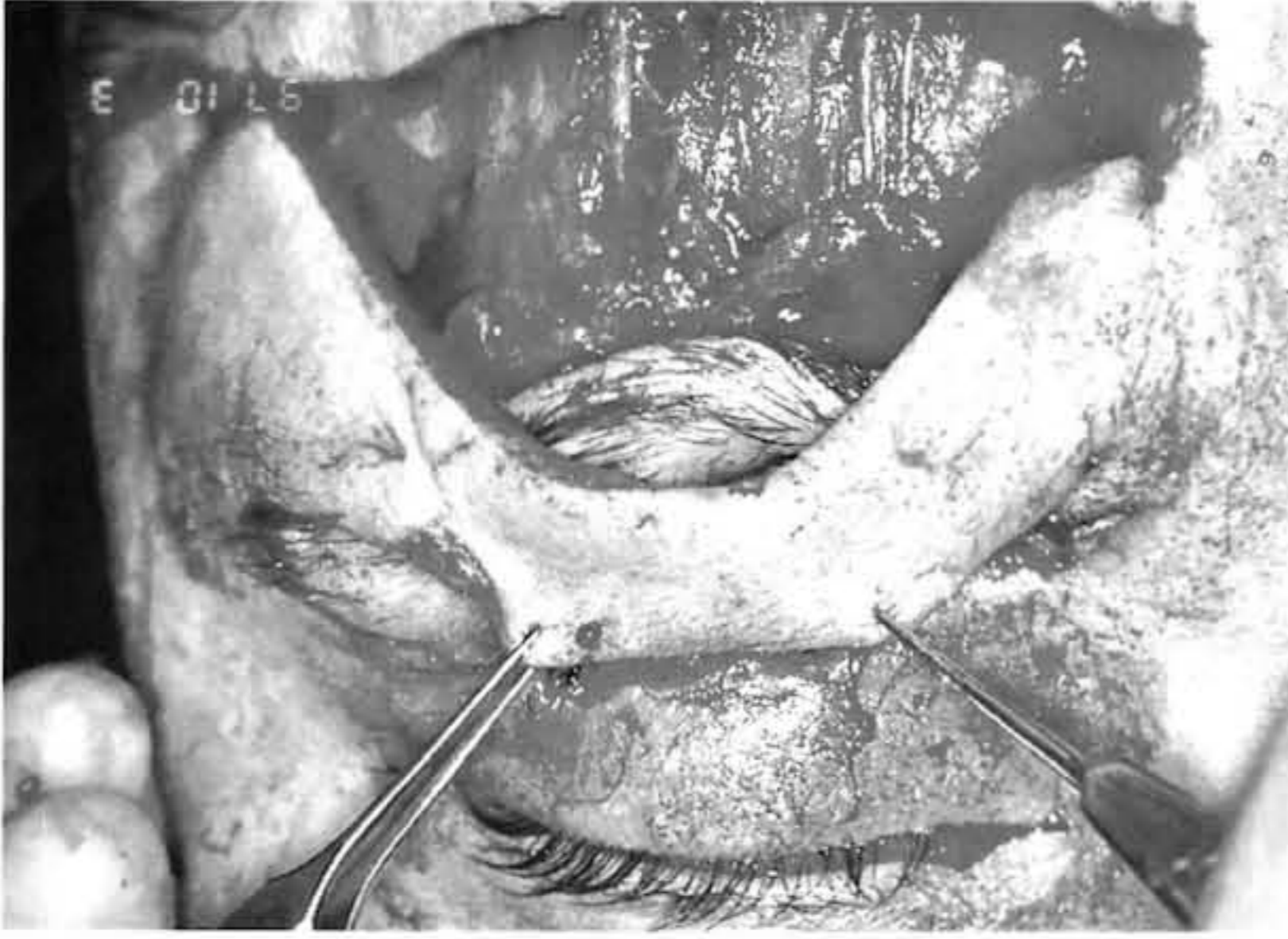


Fig. 3. Flap raised in a subcutaneous plane.

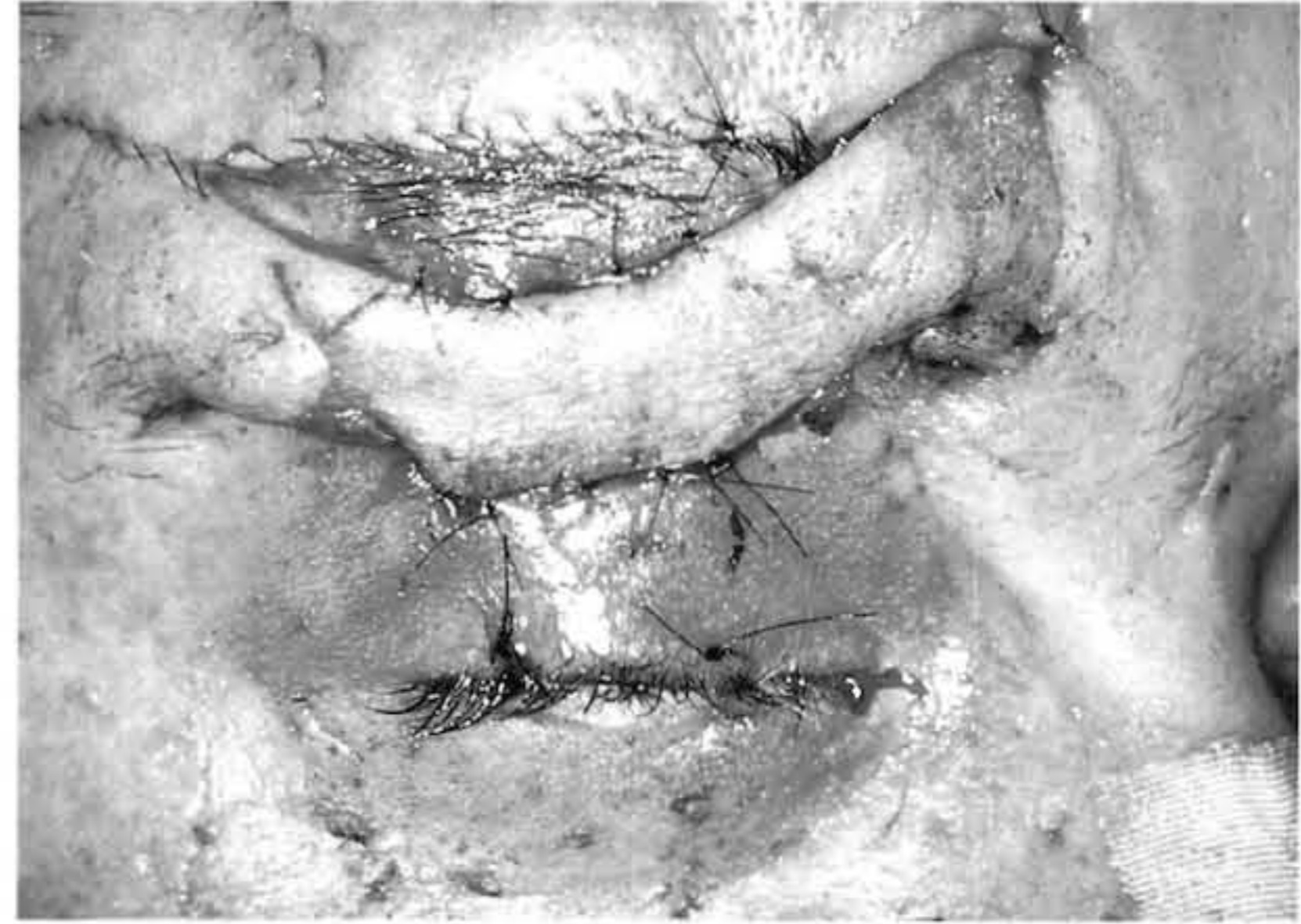

Fig. 4. Initial flap insetting.

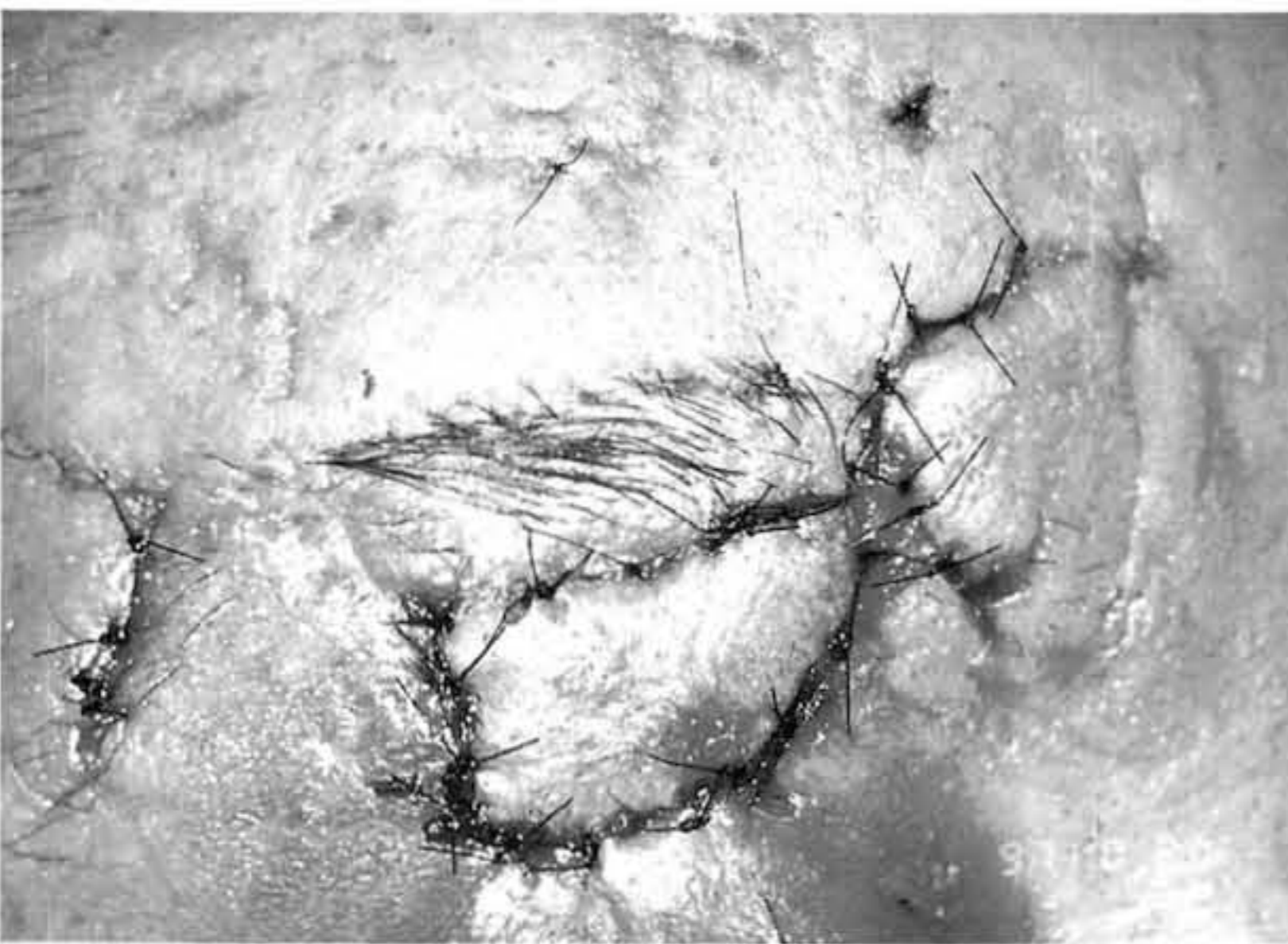

Fig. 5. Final flap insetting.

the supraorbital area, we felt it was relatively less safe to utilize only a singly pedicled flap, based either medially or laterally.

Aesthetically, if the pre-existing periorbital lacerations are excluded, the final result after insetting is acceptable. The majority of the incision lies camouflaged within the superior margin of the brow, similar to that seen with a direct brow lift in cosmetic surgery. As with other pedicled forehead or temporal flaps used in eyelid reconstruction, the skin that is transferred is not of the same color or thickness as is normally found in the recipient area. Thus, this flap would ideally be suited for full-thickness upper eyelid defects. Split-thickness skin grafts from the contralateral upper eyelid are the preferred reconstructive modality for rehabilitation of partial thickness upper eyelid defects. However, if there is concern regarding the patient's healing potential (e.g., heavy smokers, diabetes mellitus,

chronic steroid usage, radiation therapy, etc.), the bipedicled flap may be utilized. If it is used to resurface partial thickness defects, one should be willing to accept the likely need for secondary thinning of the flap.

### Conclusions

In conclusion, we have outlined the potential benefits and clinical use of a pedicled bucket-handle brow flap for reconstruction of upper eyelid defects. We found the flap to be simple to harvest and inset. Further, despite poor patient healing potential, flap vascularity was excellent and survival was complete. We feel that this may represent a useful flap in the armamentarium of the reconstructive surgeon, when faced with any significant full-thickness upper eyelid defects, or partial thickness defects in patients with borderline or unacceptable healing abilities.

### References

1. Tenzel RR: Reconstruction of the central one half of an eyelid. *Arch Ophthalmol* 93:125-126, 1975
2. Smith B, Obear MF: Bridge flap technique for reconstruction of large upper lid defects. *Plast Reconstr Surg* 38:45-48, 1966
3. Cutler N, Beard C: A method for partial and total upper lid reconstruction. *Am J Ophthalmol* 39:1-7, 1955
4. Putterman AM: Viable composite grafting in eyelid reconstruction. *Am J Ophthalmol* 85:237-241, 1978
5. Kazanjian VH, Roopenian A: Median forehead flaps in the repair of the nose and surrounding areas. *Trans AM Acad Ophthalmol Otolaryngol* 60:557-566, 1956